

## Primary liposarcoma of the liver: a case report and review of the literature

B. Nakhai, MD.<sup>1</sup>, AR. Motabar, MD.<sup>2</sup>

Department of Surgery, Hazrat Rasool Hospital, Iran University of Medical Sciences, Tehran, Iran.

### Abstract

Liver neoplasm is not an uncommon disease in Asian countries. Liposarcoma is a rare mesenchymal malignant tumor which usually originates in the retroperitoneum and extremities. From 1973 till now about 10 cases of primary liver liposarcoma have been reported. We present the eleventh case in a young adult female with uncommon presentation. She suffered from a huge mass in the right portion of the liver with clinical manifestations of sepsis and respiratory distress. Despite aggressive surgery, tumor recurrence after six months led to death after a year. Hepatectomy is the best strategy to achieve long term survival for patients. Trials of preoperative radiation therapy with or without intraoperative irradiation are underway.

**Keywords:** liver, liposarcoma, hepatectomy.

### Introduction

Liver neoplasm is not an uncommon disease in Asian countries. Cavernous hemangioma, adenoma, and focal nodular hyperplasia are the most common benign tumors of the liver. Hepatocellular and cholangiocarcinoma are the most common malignant ones.

Liposarcoma is a rare mesenchymal malignant tumor which usually originates in the retroperitoneum and extremities. It is the most common soft tissue sarcoma and accounts for 20% of all mesenchymal tumors [1,2].

Primary liposarcoma of the liver, although extremely rare, must be in the differential diagnosis of a hepatic mass that develops in the non-cirrhotic liver, especially in patients who are potential candidates for orthotopic liver transplantation. Liposarcoma is an absolute contraindication for liver transplantation.

The 5 year survival of liposarcoma varies from 59-70% but in primary liver liposarcoma rates have not been reported [3].

### Case report

A single 21 year-old female presented 3 months before admission with fever, dyspnea and severe abdominal pain. Pain was intermittent (3-4 hr) with pain relief intervals and was located in the right upper quadrant (RUQ), radiating to the back and anterior chest wall. She had a period of fever (maximum 39°C).

Sonography was done a week after symptoms had started indicating increased liver span with a subdiaphragmatic echogenous mass in the right lobe with multiple cystic foci. Size of the mass was 140×130 mm which was suggestive of hemangioma.

Spiral CT scan (triphasic) performed a week later reported a large mass sized 150×120×100

1. Associate Professor of Hepatobiliary Surgery, Department of Surgery, Hazrat Rasool Hospital, Iran University of Medical Sciences, Tehran, Iran.

2. **Corresponding author**, Resident of General Surgery, Department of Surgery, Rasool Hospital, Niayesh St., Tehran, Iran. Tel: +98912 1500971, email: amotabar@yahoo.com.

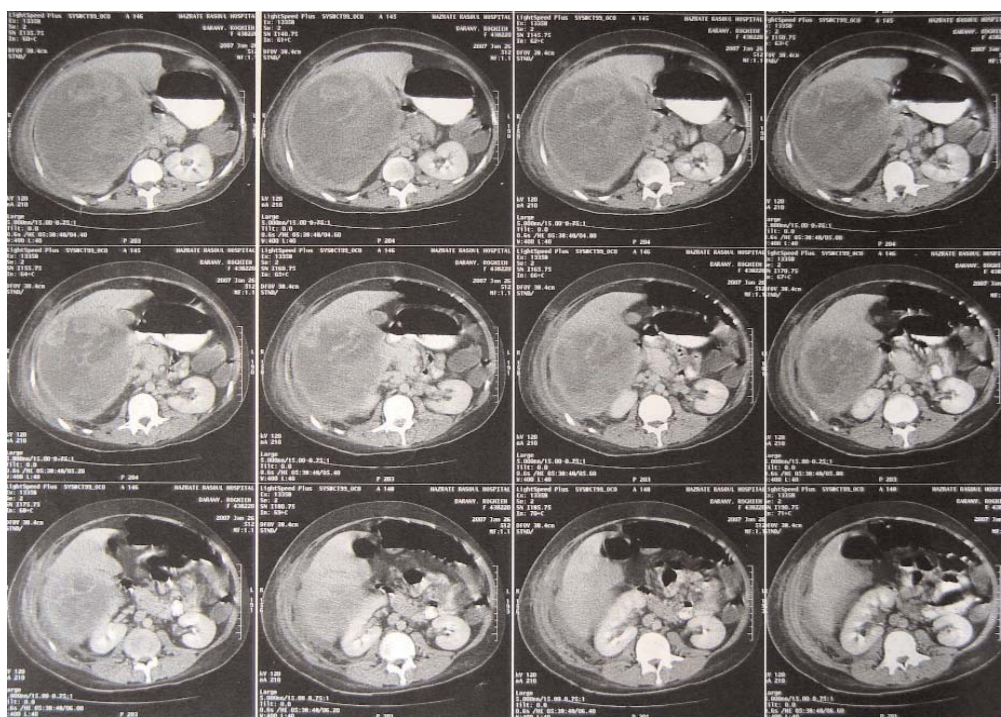


Fig.1. Abdominal CT scan with IV and oral contrast.

mm in the lateral part of the right lobe containing solid and cystic components; the solid com-

ponent was enhanced after IV contrast injection. The mass had a regular contour and margin with

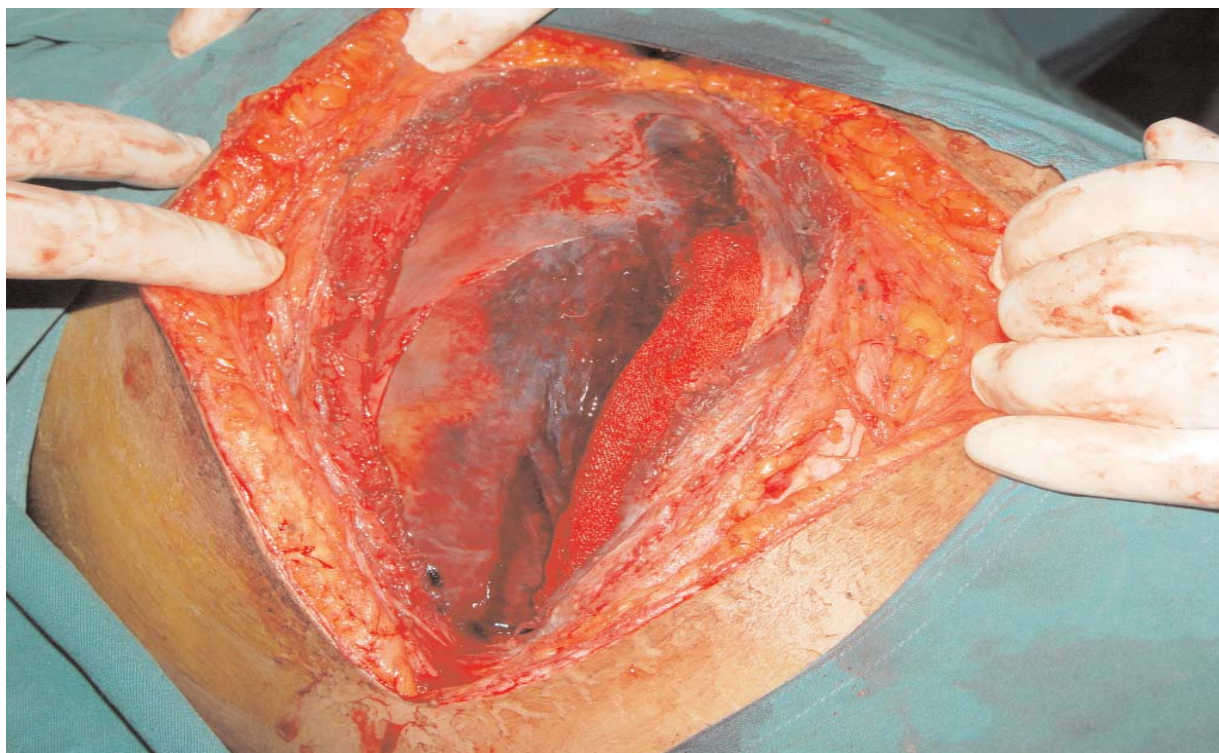


Fig. 2. Huge mass involving the right liver lobe.



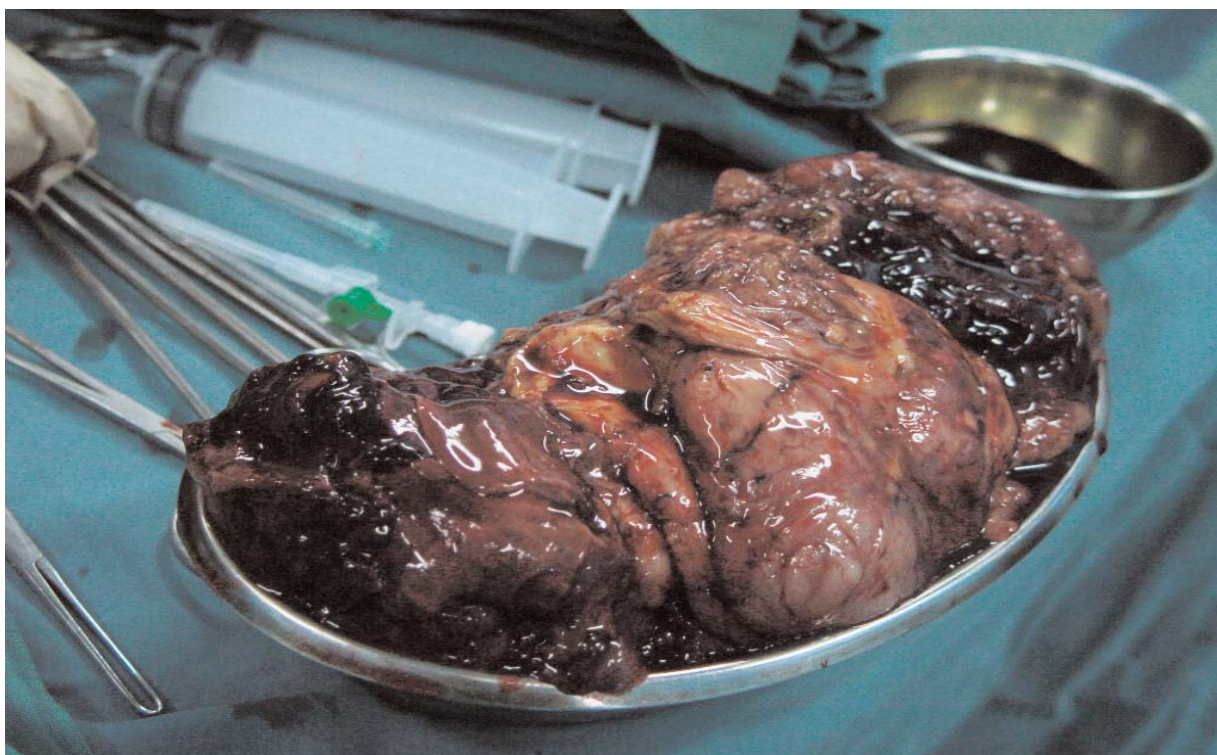

Fig. 3. Liver tissue after resection of the mass.

no wall enhancement in early and delayed phases of imaging. Bilateral pleural effusion with right side dominance was also noted. Free fluid and intra-abdominal LAP was not seen.

Complicated solid cyst and hemangioepithelioma were considered in the differential diagnosis. In pleural effusion analysis, hemorrhagic fluid containing few epithelial cells with mild cytonuclear atypia was seen.

The first liver biopsy specimen was obtained, but the result was not definitive. Symptoms were diminished for 1.5 months.

Gradually abdominal pain, dyspnea and fever appeared again. A second CT scan after 1.5 months showed a large round low-density mass in the right lobe of the liver growing exophytically towards the upper right hemithorax, elevating the right diaphragm. Liquid density was seen in that lesion. Free liquid was seen in the abdomen and pelvis (Fig. 1).

Differential diagnoses so far were hemangioma, adenoma, cystic lesions and malignancy. There was no risk factor for malignancy in

the history.

She was admitted again in our center with severe sepsis. On examination she was not icteric and there were no stigmata of chronic liver disease. Careful physical examination did not reveal lymphadenopathy or soft tissue mass. The abdomen was distended and firm with generalized tenderness, predominantly in the RUQ. Fullness in the RUQ was palpable. Liver span was 20cm. White blood cell count was 14600 (seg: 85%) and Hgb 12.5g/dl. Standard serum liver tests, urine analysis, coagulation tests, serum electrolyte levels and alpha-fetoprotein were all within the reference range.

An ultrasound guided biopsy failed to provide sufficient diagnostic material. In the last sonography the liver tissue was completely heterogeneous. A heterogeneous mass measuring 18× 18cm was detected in the right liver lobe consisting of cystic & solid foci. She was then scheduled for exploratory laparotomy. During laparotomy, the liver was completely enlarged and congested with severe omental adhesions.

We performed right extended hepatectomy and removed 3kg of necrotic tissue and bloody fluid. Grossly, the tumor was cystic and nonhomogeneous with extensive foci of hemorrhage and necrosis (Fig. 2,3). Pathology report mentioned neoplastic tissue composed of spindle cells with plump oval hyperchromic nuclei mixed with many highly pleomorphic giant cells. Extensive areas of necrosis were also evident. These findings suggested high grade sarcoma consistent with liposarcoma.

The postoperative course was uneventful and she tolerated normal activity and enteral feeding after a week. Chest tube was removed and the patient was discharged on her 15th postoperative day and referred to the oncology department. She was followed up in our outpatient clinic; liver ultrasonography was performed every 2-3 months. About 2 months later we found reappearance of a mass at the previous tumor site. She underwent chemotherapy for two months. Because of her poor socioeconomic status she rejected our request to come regularly to our clinic and complete the therapy course. After 9 months, she was admitted to another hospital with severe respiratory distress and multiple metastatic lesions in the lungs and a lobulated tumor in the liver. She died after 10 days of hospitalization with severe respiratory failure.

### Discussion

Virchow in 1857 first described a malignant tumor of fatty tissue arising in the lower extremity [4]. Most common tumor sites include deep soft tissue of the trunk, retroperitoneum and extremities [5]. The liver is involved in 10% of metastatic cases. Metastases are usually found in the lungs, brain, pleura, thyroid gland, pancreas and spinal cord [5,6].

Liposarcoma accounts for less than 20% of all soft tissue sarcomas and the average patient age at presentation is 50 years. Metastases are common, and the lungs and liver are the most common sites of metastasis.

The 5 year survival rate of patients who have undergone curative resection or radiation therapy is less than 50% [4,5].

Primary liver liposarcoma is rare. The experience in dealing with this malignant neoplasm is limited. Early diagnosis of liver liposarcoma is not easy. Physical examination is usually unrevealing. The usual symptoms and signs include jaundice, fever, nausea, vomiting, abdominal fullness, RUQ pain and weight loss [6]. Most of the symptoms are caused either by displacement or compression of nerves, vessels, biliary tract, and intestinal structures. Mildly abnormal LFT results are detected. Serum AFP levels are normal. Contrast-enhanced CT and MRI have become an accurate method of diagnosis. Fine-needle aspiration for the diagnosis is often unrevealing. Abdominal ultrasonography usually is a good tool to conduct preoperative screening and postoperative follow-up [4,5,6].

Five major histologic categories of liposarcoma include Myxoid, Round cell, Well-differentiated, Poorly-differentiated and Pleomorphic. Patients with myxoid or well-differentiated type have a lower local recurrence rate than others.

Curative and aggressive hepatectomies are still the best policy to achieve long-term survival of patients [5,6].

Wolloch et al in 1973 reviewed 16 cases of malignant liver tumors, including one patient with myxoid liposarcoma who had undergone right hepatic lobectomy with only 46 days postoperative survival [8].

Kim et al described a 14 × 10 × 5cm liposarcoma of the right lobe of the liver. The patient subsequently underwent a hepatic resection and remained tumor free for 10 months [9]. Another article reported by Kim and Yu showed tumor in the liver capsule, but survival was not mentioned [10].

Primary liposarcomas of the liver have also been described in children. Soares et al described a case of liposarcoma of the hepatic

hilum that presented as obstructive jaundice in a 28-month-old infant [11]. Wright et al described a 3-year-old boy who presented with abdominal pain which later proved to be due to liposarcoma in the hilum [12]. Chen et al evaluated primary malignant tumors in the pediatric population [13]. They described one child with liposarcoma, but sex, age, and exact location within the liver were not described. To our knowledge, there are no reports of hepatic liposarcoma in principal reference sources of rare hepatic tumors.

Nelson et al in 2001 reported one of the largest cases of primary liposarcoma of the liver in an adult [14]. Gajda in 1988 reported a case of primary liposarcoma of the liver in a 48-year-old woman. Histologic analysis showed a well differentiated liposarcoma [15]. In 2006 Liang et al described a huge case of primary liposarcoma sized 11×11×13cm in a 61 year old female [16]. Aribal et al in 1993 reported a hilum liposarcoma in a middle aged woman [17]. According to the clinical course, liver liposarcoma has a high rate of recurrence, which is similar to that of other sites [18].

Our case was one of the largest tumors in a young adult. The survival was less than a year. At the end of the illness period she suffered from severe respiratory failure due to bilateral lung metastases.

Primary liposarcoma of the liver is exceedingly rare; this tumor should be considered in the differential diagnosis, especially in those patients who are potential candidates for liver resection or orthotopic liver transplantation. This case provides a good experience about the clinical course of primary liver liposarcoma. In retroperitoneal and visceral lesions, operation remains the dominant method of therapy with the most important prognostic factors for survival being completeness of resection and grade [19,20]. Aggressive strategy in treatment including extensive hepatic resection might be efficient, although the prognosis is dismal and the recurrence rate is high. The role of radiation

therapy is not well defined and needs further investigation [21]. Brachytherapy or intraoperative radiation therapy at the time of surgical resection may be used to treat a localized area at high risk of microscopic or gross residual disease when further surgical excision is not possible. Trials of preoperative radiation therapy with or without intraoperative irradiation are underway [22].

## References

1. Lawrence W, Donegan WL, Natarajan N, et al. Adult soft tissue sarcomas. A pattern of care survey of the American College of Surgeons. *Ann Surg* 1987; 205:349.
2. Pollock RE, Karnell LH, Menck HR, et al. The National Cancer Data Base report on soft tissue sarcoma. *Cancer* 1996; 78:2247.
3. DeMatteo RP, Leung L, et al. Two hundred gastrointestinal stromal tumors: recurrence patterns and prognosis. *Ann Surg* 2000; 231:51.
4. Brasfield R, Das gupta TK. Liposarcoma. *CA Cancer J Clin* 1970; 20:3-9.
5. Steven G, Silverberg R, Delelis A. Principles and practice of surgical pathology and cytopathology. 3rd. New York, Churchill Livingstone; 2004. pp.540
6. Tear S, Ronan SG. Solitary metastatic liposarcoma of liver. *Arch Pathol Lab Med* 1978; 102:605.
7. Nelson V, Fernandes NF, Woolf GM, Geller SA, Petrovic LM. Primary liposarcoma of the liver: a case report and review of literature. *Arch Pathol Lab Med* 2001; 125: 410-412.
8. Wolloch Y, Dintsman M, Garti I. Primary malignant tumors of the liver. *Isr J Med Sci* 1973; 9: 6-11.
9. Kim TW, Reyes CV. Myxoid liposarcoma mimicking fluid density. *J Surg Oncol* 1985; 30: 80-82.
10. Kim YI, Yu ES, Lee KW, Park EU, Song HG. Differentiated liposarcoma of the liver. *Cancer* 1987; 60: 2785-2790.
11. Soares FA, Magnani landell GA. Liposarcoma of hepatic hilum in childhood: report of a case. *Med Pediatric Oncol* 1989; 17:239-243.
12. Wright NB, Skinner R. Myxoid liposarcoma of the portal hepatitis in childhood. *Pediatr Radiol* 1993; 23:620-621.
13. Chen WJ, Lee JC. Primary malignant tumor of liver in infants & children in Taiwan. *J Pediatric Surg* 1988; 23:457-461.
14. Nelson V, Fernandes NF, Woolf GM, Geller SA,

Petrovic LM. Primary liposarcoma of the liver: a case report and review of literature. *Arch Pathol Lab Med* 2001; 125: 410-412.

15. Gajda M, Hommam M. Primary liposarcoma of the liver - a rare mesenchymal tumor. *J Surg Oncol* 1985; 30: 80-82.

16. Liang M, Hong Shiue Chou. A case of huge primary liposarcoma of liver. *World Journal of Gastroenterology* 2006,21(7):1157-1159.

17. Aribal E, Berberoglu L. Primary liposarcoma of the liver. *AJR Am J Roentgenol* 1993; 161: 1331-1332.

18. Enzinger FM, Weiss SW. *Soft Tissue Tumors*. 3rd ed. St. Louis; Mosby: 1995. P. 431-465.

19. Lewis JJ, Brennan MF. The management of retroperitoneal soft tissue sarcoma. *Adv Surg* 1999; 33: 329.

20. Singer S, Corson M, Demetri GD, et al. Prognostic factors predictive of survival for truncal and retroperitoneal soft tissue sarcoma. *Ann Surg* 1995; 221:185.

21. Brennan MF. Retroperitoneal sarcoma: trial. *Ann Surg Oncol* 2002; 9:324.

22. Alektiar KM, Hu K, Anderson L, et al. High-dose-rate intraoperative radiation therapy (HDR-IORT) for retroperitoneal sarcomas. *Int J Radiation Oncol Biol Phys* 2000; 47:157, 73.