

ECG changes of cardiac origin in elderly patients with traumatic brain injury

Amir Masoud Hashemian¹, Koorosh Ahmadi², Ali Taherinia³
Mohamad Davood Sharifi⁴, Javad Ramezani⁵, Seyed Behzad Jazayeri⁶
Soheil Saadat⁷, Vafa Rahimi-Movaghar^{*8}

Received: 18 February 2015

Accepted: 16 August 2015

Published: 13 December 2015

Abstract

Background: Simultaneous electrocardiographic (ECG) changes are seen in hemorrhagic brain events even in the absence of associated myocardial infarction (MI). This study was designed to assess the role of ECG changes to predict true MI in patients with hemorrhagic brain trauma.

Methods: Data of 153 patients with traumatic brain injury and concomitant ECG changes were recorded. Enzyme study was performed for the patients, and a cardiologist confirmed the diagnosis of MI.

Results: Overall, 83 females and 70 males older than 50 years of age were enrolled in the study. The most common type of hemorrhagic brain event was subarachnoid hemorrhage, and the most common ECG change was an inverted T wave. MI was confirmed in 15 (9.8%) patients. Patients with intracranial hemorrhage had significantly ($p= 0.023$) higher rates of associated MI than other types of brain hemorrhages. ST segment elevation was found to have a positive predictive value of 71.4% in males and 25% in females in terms of diagnosing a true MI associated with hemorrhagic brain events.

Conclusion: Although simultaneous cardiac changes are seen after sympathetic over-activity in brain hemorrhages, regular ECG screening of elder patients with traumatic brain injury is suggested, particularly in patients with intracranial hemorrhages.

Keywords: Traumatic Brain Injury, Subarachnoid Hemorrhage, Electrocardiography, Intracranial Hemorrhage, Positive Predictive Value, Myocardial Infarction.

Cite this article as: Hashemian AM, Ahmadi K, Taherinia A, Sharifi MD, Ramezani J, Jazayeri SB, Saadat S, Rahimi-Movaghar V. ECG changes of cardiac origin in elderly patients with traumatic brain injury. *Med J Islam Repub Iran* 2015 (13 December). Vol. 29:306.

Introduction

Traumatic brain injuries (TBI) are common conditions in emergency department visits. In TBI, electrocardiographic (ECG) changes including morphologic changes

and rhythm disturbances are frequent. In subarachnoid hemorrhage (SAH), ECG changes have been reported to occur in 49% to 100% of the patients (1-4). Repolarization abnormalities such as prolongation

¹. MD, Assistant Professor of Emergency Medicine, Department of Emergency Medicine, Mashhad University of Medical Sciences, Mashhad, Iran. hashemianam@mums.ac.ir

². MD, Associate Professor of Emergency Medicine, Department of Emergency Medicine, Alborz University of Medical Sciences, Karaj, Iran. ahmadik@mums.ac.ir

³. MD, Assistant Professor of Emergency Medicine, Department of Emergency Medicine, Alborz University of Medical Sciences, Karaj, Iran. dr.alitaheriniya@gmail.com

⁴. MD, Assistant Professor of Emergency Medicine, Department of Emergency Medicine, Mashhad University of Medical Sciences, Mashhad, Iran. sharifimd@mums.ac.ir

⁵. MD, Assistant Professor of cardiology, Department of cardiology, Mashhad University of medical sciences, Mashhad, Iran. ramezanij@mums.ac.ir

⁶. MD, General Practitioner, Sina Trauma and Surgery Research Center, Tehran University of Medical Sciences, Tehran, Iran. s.b.jazayeri@gmail.com

⁷. MD, Associate Professor of Epidemiology, Sina Trauma and Surgery Research Center, Tehran University of Medical Sciences, Tehran, Iran. Soheil.saadat@gmail.com

⁸. **(Corresponding author)** MD, Professor of Neurosurgery, Sina Trauma and Surgery Research Center, Tehran University of Medical Sciences, Tehran, Iran. v_rahimi@sina.tums.ac.ir

of the QT interval and changes in the ST segment and T wave morphology are the most common ECG alterations in patients with SAH and intracerebral hemorrhage (ICH) (5-8). The mechanisms of these abnormalities are not completely understood, but sympathetic over-activity induced by the intracranial hemorrhage is considered as the pathophysiology behind it (9). ECG changes associated with TBI can mimic changes associated with acute coronary syndromes (3). ECG changes associated with neurovascular events may play an important decision making role in managing those who are critically ill and unresponsive. Several changes were found in ECG of SAH/ICH patients and were similar to patients with acute cardiac ischemia. However, lack of confidence about the etiology of these changes may lead to inappropriate management protocols. This study was designed to evaluate the significance of ECG changes in patients with hemorrhagic events following TBIs to detect concomitant cardiac pathology.

Methods

In a prospective study, 327 patients with a complaint of traumatic head injury who were admitted to the emergency department within 30 minutes after the injury were screened to be selected as the cases. A primary ECG was obtained in the initial survey. Patients with ECG abnormalities underwent computed tomographic (CT) study to detect hemorrhagic events inside the cranium including SAH, subdural hemorrhage (SDH), epidural hemorrhage (EDH) and intracranial hemorrhage (ICH). Patients who showed both ECG changes and findings of hemorrhagic brain events were eli-

gible to participate in the study. However, patients were not included in the study if they had a history of prior cardiac pathology, history of chest pain in the last four weeks, accompanying trauma to the chest, known vascular pathologies of the brain or declined to participate in the study. Patients with critical conditions such as massive active bleeding, hemorrhagic shock and airway impairments were not eligible for enrolment in the study. Cardiac enzymes were assessed for all patients six hours after their admission. A cardiologist assessed patients with elevated cardiac enzymes to confirm or reject possible diagnosis of an acute myocardial injury (AMI). The diagnosis of AMI was made by performing serial cardiac enzyme assays, traditional angiographic/CT assisted angiography and echocardiography whenever necessary. Data were recorded and statistical analyses were performed using SPSS V. 20. Chi-square test was used for data analysis. The study protocol was designed in accordance with Helsinki Declaration of 1975 and uptake of 2000, and was approved by The Ethics Committee of Mashhad University of Medical Sciences.

Results

In the primary selection of the patients, 327 cases, 230 males (70.3%) and 97 females (29.7%), were selected. Overall, 45 patients (13.7%), 31 males (68.9%) and 14 females (31.1%), had elevated cardiac enzyme assays, and 12 males and 6 females were diagnosed with AMI. However, the initial selected cases were not equally distributed in the age groups of the study, with only eight females younger than 50 years of age. To analyze the data and dismiss the biased distribution of the patients in the age

Table 1. Frequency of ECG changes and intracranial pathologies of the patients in the study

		Male	Female
ECG Changes	ST Elevation	4.6% (7)	2.6% (4)
	ST Depression	18.9% (29)	9.8% (15)
	T Inversion	22.3% (34)	22.9% (35)
	Prolonged QT	1.9% (3)	22.9% (35)
Intracranial Pathology	SAH	20.7% (47)	26.1% (40)
	ICH	1.3% (2)	11.7% (18)
	EPD	9.1% (14)	2.6% (4)
	SAD	4.6% (7)	13.7% (21)

Table 2. Frequency of cardiac pathology in different types of brain hemorrhagic events

		AMI	No Ischemic Pathology#	Total
Intracranial Pathology	SAH	6.9% (6)	93.1% (81)	56.9% (87)
	ICH	25% (5)*	75%(15)	13.0% (20)
	EDH	11.1% (2)	88.9% (16)	11.8% (18)
	SDH	7.1% (2)	92.9% (26)	18.3% (28)
Total		9.8% (15)	90.2% (138)	100% (153)

No ischemic pathology represents patients who were not diagnosed with current or previous ischemic cardiac pathology.

* The difference with other groups was significance at $p=0.023$

groups, the analyses were limited to patients older than 50 years of age. The results discussed further are limited to 153 cases who were over 50 years of age.

In the final analyses, 153 cases were enrolled, 70 (45.7%) males and 83 females (54.3%). The most common hemorrhagic brain event was SAH, and the most common ECG finding was an inverted T wave (Table 1). Enzyme study was initially positive in 27 patients (17.6 %). However, only 15 (9.8%) patients (9 males and 6 females) were ultimately diagnosed with AMI (Table 2). As displayed in Table 2, 25% (n= 5) of the patients with ICH had a true ischemic pathology in their final diagnosis; the proportion of patients with AMI in the ICH group was significantly higher than other brain hemorrhagic pathologies ($p=0.023$). The positive predictive value (PPV) of ECG changes in the diagnosis of AMI in patients with concomitant brain hemorrhages was assessed (Fig. 1). As shown in Figure 1, ST elevation had a PPV of 71.4%

in males and 25% in females. However, ST depression and T inversion had stronger PPV in females (Fig. 1). Prolonged QT was not included in the analyses since no patient with prolonged QT in ECG was diagnosed with true AMI.

Discussion

In this study, patients with hemorrhagic brain injuries and different ECG abnormalities, T inversion, ST depression, prolonged QT and ST elevations were enrolled. However, only 7.8% of the patients were diagnosed with AMI. ECG changes in hemorrhagic brain events are common. Coronary artery thrombosis, vasospasm, or oxygen supply-demand mismatch were first raised as the mechanism of ECG changes (3,12). However, the assessment of patients revealed normal coronary arteries in percutaneous cardiac catheterization and autopsies (1,13,14), and ECG changes did not correlate with ventricular wall motion abnormalities in hemorrhagic brain injuries (15). ECG changes may be present in up to 96% of the patients suffering from SAH with over 20% having positive cardiac enzymes (10,11).

In the study of Urbaniak et al. (1), the level of troponin I was the single cardiac parameter associated with the outcome of patients, and ECG changes were not indicative of underlying cardiac pathologies. The mechanism of ECG changes in CNS insults results from direct stimulation of hypothalamic nerve endings and epinephrine and norepinephrine secretion in the blood stream (1,3,16). Several animal (27) and clinical studies support both direct and hormonal mechanisms (17,18). However, the significance of certain ECG morpholog-

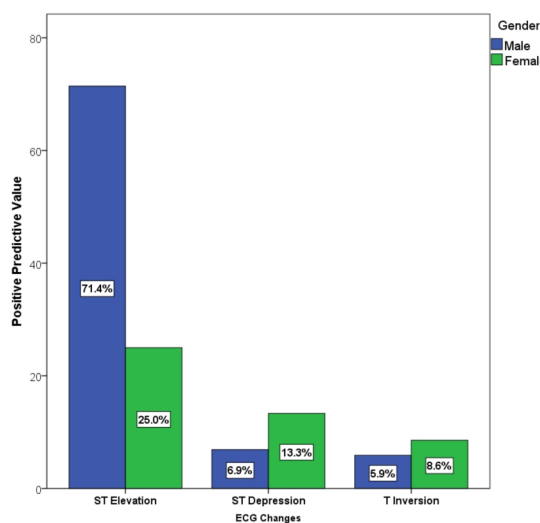


Fig. 1. Positive predictive value of ECG changes in hemorrhagic brain injuries in males and females

ic changes to each of these mechanisms is not completely understood. Although most of the studies in the literature have worked on presumable causes of ECG abnormalities in SAH patients, the same mechanism can be applied to ICH, EDH and SDH (6-8, 13,16,20-23). The presence of ECG changes in hemorrhagic brain injuries can be both due to cardiac pathology (13) and CNS insults (24). In this study, 5.5% of all admitted patients and 7.8% of the patients older than 50 years of age showed ischemic cardiac pathologies accompanying the traumatic brain hemorrhagic event.

In this study, 25% of the patients with ICH showed ischemic cardiac pathology; and the difference between this group of patients and other types of traumatic hemorrhagic events was statistically significant ($p= 0.023$). However, the occurrence of AMI in elder patients with ICH might be due to similar risk factors of ICH and AMI, increasing age, male gender, smoking, diabetes mellitus and hypertension (25). Ischemic cardiac pathologies were more common in males as it is predicted due to the general epidemiology of cardiac diseases. In this study, PPV of ST segment elevation was 71.4% for males and 25% for females in diagnosis of AMI. However, PPVs of T inversion and ST segment depression were surprisingly higher in females, 13.3% vs. 6.9% and 8.6% vs. 5.9%, respectively. The fact that these values are higher in females cannot be explained due to the small sample size of the study. To our knowledge, so far, there has not been any known pathophysiologic mechanism in CNS hemorrhagic events that could explain the differences between males and females' cardiac tissue response to hormonal or neuronal responses. Urbaniak et al.(1) found that age is the only independent predictor of cardiac problems in patients with SAH. In this study, analyzing patients of different age groups was not applicable due to limitations in patients' selection.

Conclusion

The negative impact of cardiac abnormal-

ity on patients' outcome with hemorrhagic brain events has already been stated (1,16). However, given the low GCS scores, and traumatic injuries to the head and critically ill elder patients with hemorrhagic brain events, the diagnosis of probable accompanying cardiac pathology is vital in these patients. The results of this study suggest regular screening of patients older than 50 years of age with ECG and interpreting ECG findings, namely ST segment elevations, regardless of concomitant neurovascular events in the CNS. Elder patients presenting with ICH may be at a higher risk for an accompanying ischemic cardiac pathology and require more attention in clinical management and diagnosis.

Limitations

This study was designed to assess the single role of ECG morphologic changes in patients after traumatic hemorrhagic events in the brain. Lack of a control group (patients with traumatic hemorrhagic brain events and no ECG changes) made the analyses of the data for risk factors inappropriate, and the sensitivity and specificity of the tests inapplicable. The patients were not evenly distributed by gender and age, which led to analyzing a limited elderly group of patients. Followed-up was not conducted for the secondary confirmation of existence of cardiologic pathology, in AMI patients, and this could be the result of a transient stress cardiac pathology rather than true cardiac pathology, leading to an overestimation of AMI cases.

Acknowledgements

We would like to thank Mrs. Bitia Pourmand for her generous help in language editing of the manuscript.

Conflict of Interest

The authors of the present manuscript, Amir Masoud Hashemian, Koorosh Ahmadi, Ali Taherinia, Mohamad Davood Sharifi, Seyed Behzad Jazayeri, Soheil Saadat and Vafa Rahimi-Movaghar declare that they have no conflict of interest to

state.

Ethical Guidelines

The study protocol was designed in accordance with Helsinki Declaration of 1975 and update of 2000, and was approved by The Ethics Committee of Mashhad University of Medical Sciences. All patients signed an informed consent prior to their inclusion to the study.

References

1. Urbaniak K, Merchant AI, Amin-Hanjani S, and Roitberg B. Cardiac complications after aneurysmal subarachnoid hemorrhage. *Surg Neurol* 2007;67(1): 21-8; discussion 28-9.
2. Bhattacharya IS, Sandeman D, Dweck M, McKie S, Francis M. Electrocardiographic abnormalities in a patient with subarachnoid haemorrhage. *BMJ Case Rep* 2011; 2011.
3. Sakr YL, Ghosn I, Vincent JL. Cardiac manifestations after subarachnoid hemorrhage: A systematic review of the literature. *Progress in Cardiovascular Diseases* 2002;45(1):67-80.
4. Stevens RD, Nyquist PA. The systemic implications of aneurysmal subarachnoid hemorrhage. *J Neurol Sci* 2007;261(1-2):143-56.
5. Syverud G. Electrocardiographic changes and intracranial pathology. *AANA J* 1991;59:229-32.
6. Chatterjee S. ECG Changes in Subarachnoid Haemorrhage: A Synopsis. *Neth Heart J* 2011; 19(1):31-4.
7. Qaqa AY, Suleiman A, Alsumrain M, Debari VA, Kirmani J, Shamoon FE. Electrocardiographic abnormalities in patients presenting with intracranial parenchymal haemorrhage. *Acta cardiologica* 2012; 67(6):635-639.
8. Jeong YS, Kim HD. Clinically significant cardiac arrhythmia in patients with aneurysmal subarachnoid hemorrhage. *J Cerebrovasc Endovasc Neurosurg* 2012;14(2):90-4.
9. Wybraniec MT, Mizia-Stec K, Krzych LJ. Neurocardiogenic injury in subarachnoid hemorrhage: a wide spectrum of catecholamine-mediated brain-heart interactions. *Cardiol J* 2014.
10. Deibert E, Barzilai B, Braverman AC, Edwards DF, Aiyagari V, Dacey R, et al. Clinical significance of elevated troponin I levels in patients with nontraumatic subarachnoid hemorrhage. *Journal of neurosurgery* 2003;98(4):741-746.
11. Parekh N, Venkatesh B, Cross D, Leditschke A, Atherton J, Miles W, et al. Cardiac troponin I predicts myocardial dysfunction in aneurysmal subarachnoid hemorrhage. *Journal of the American College of Cardiology* 2000;36(4):1328-1335.
12. Yuki K, Kodama Y, Onda J, Emoto K, Morimoto T, Uozumi T. Coronary vasospasm following subarachnoid hemorrhage as a cause of stunned myocardium: case report. *Journal of neurosurgery* 1991;75(2):308-311.
13. Kono T, Morita H, Kuroiwa T, Onaka H, Takatsuka H, Fujiwara A. Left ventricular wall motion abnormalities in patients with subarachnoid hemorrhage: neurogenic stunned myocardium. *Journal of the American College of Cardiology* 1994;24(3):636-640.
14. Bybee KA, Kara T, Prasad A, Lerman A, Barsness GW, Wright RS, et al. Systematic review: transient left ventricular apical ballooning: a syndrome that mimics ST-segment elevation myocardial infarction. *Annals of internal medicine* 2004;141(11):858-865.
15. Zaroff JG, Rordorf GA, Ogilvy CS, Picard MH. Regional patterns of left ventricular systolic dysfunction after subarachnoid hemorrhage: evidence for neurally mediated cardiac injury. *Journal of the American Society of Echocardiography* 2000;13(8):774-779.
16. Kilbourn KJ, Levy S, Staff I, Kureshi I, McCullough L. Clinical characteristics and outcomes of neurogenic stress cardiomyopathy in aneurysmal subarachnoid hemorrhage. *Clin Neurol Neurosurg* 2013;115(7):909-14.
17. Masuda T, Sato K, Yamamoto SI, Matsuyama N, Shimohama T, Matsunaga A, et al. Sympathetic nervous activity and myocardial damage immediately after subarachnoid hemorrhage in a unique animal model. *Stroke* 2002;33(6):1671-1676.
18. Lorenzo NY, Earle AM, Peterson LL, Todd GL, Leibrock LG. The relationship of the subarachnoid injection of blood and blood fractions with cardiac rate change and arrhythmias. *J Neurol Sci* 1994;127(2):134-142.
19. Fukui S, Katoh H, Tsuzuki N, Ishihara S, Otani N, Ooigawa H, et al. Multivariate analysis of risk factors for QT prolongation following subarachnoid hemorrhage. *Critical Care* 2003;7(3): R7.
20. Huang CC, Huang CH, Kuo HY, Chan CM, Chen JH, Chen WL. The 12-lead electrocardiogram in patients with subarachnoid hemorrhage: early risk prognostication. *Am J Emerg Med* 2012;30(5): 732-6.
21. Ibrahim K, Jellinghaus S, Christoph M, Pfluecke C, Guenther M, Ney M, et al. Intracranial hemorrhage causes a transmural myocardial infarction without the presence of coronary atherosclerosis. *Int J Cardiol* 2011;152(2):e40-1.
22. Ichinomiya T, Terao Y, Miura K, Higashijima U, Tanise T, Fukusaki M, et al. QTc interval and neurological outcomes in aneurysmal subarachnoid hemorrhage. *Neurocrit Care* 2010;13(3):347-54.
23. Junttila E, Vaara M, Koskenkari J, Ohtonen P, Karttunen A, Raatikainen P, et al. Repolarization abnormalities in patients with subarachnoid and intracerebral hemorrhage: predisposing factors and

association with outcome. *Anesth Analg* 2013; 116(1):190-7.

24. Szabo MD, Crosby G, Hurford WE, Strauss WH. Myocardial perfusion following acute subarachnoid hemorrhage in patients with an abnormal electrocardiogram. *Anesthesia &*

Analgesia 1993;76(2):253-258.

25. Ariesen M, Claus S, Rinkel G, Algra A. Risk factors for intracerebral hemorrhage in the general population a systematic review. *Stroke* 2003;34(8): 2060-2065.