

Vascular endothelial growth factor expression and vascular density in oral squamous cell carcinoma (OSCC): A study on clinical and histopathologic significance

Noushin Jalayer Naderi^{*1}, Farrokh Tirgari², Zahra Keshavarz³

Received: 11 August 2015

Accepted: 27 December 2015

Published: 18 April 2016

Abstract

Background: New blood vessels formation is a critical step in tumor progression. Vascular density affects the clinical outcome and prognosis of malignant tumors. The aim of this study was to investigate the relation between the Vascular Endothelial Growth Factor (VEGF) expression and vascular density with the clinical and histopathologic features in oral squamous cell carcinoma (OSCC).

Methods: In this retrospective study, 22 paraffin embedded block of well-differentiated OSCC were examined immunohistochemically for VEGF expression. Vascular density was determined by counting the blood vessels in 6 fields with 100 (HPF) on hematoxylin-eosin stained slides. The relation between the VEGF expression and vascular density with clinical and histopathologic features were analyzed by t-test, ANOVA, and Chi-square tests.

Results: A significant relation between gender ($P=0.06$) and tumor size ($p=0.05$) with vascular density was obtained. The relation between VEGF expression and gender ($p=0.41$), age ($p=0.35$), lymph node involvement ($p=0.38$), tumor size ($p=0.15$) and tumor differentiation ($p=0.34$) was not significant. The relation between vascular density and age ($p=0.55$), lymph node involvement ($p=0.20$), and tumor differentiation ($p=0.80$) was not significant.

Conclusion: Blood vessels formation relates to tumor size. Controlling the tumor size by manipulating the blood vessels formation may contribute to the inhibition of tumor progression in malignant tumors.

Keywords: Oral, Squamous Cell Carcinoma, Vascular Endothelial Growth Factor, Microvessel density.

Cite this article as: Jalayer Naderi N, Tirgari F, Keshavarz Z. Vascular endothelial growth factor expression and vascular density in oral squamous cell carcinoma (OSCC): A study on clinical and histopathologic significance. *Med J Islam Repub Iran* 2016 (18 April). Vol. 30:358.

Introduction

Squamous cell carcinoma is about 94% of all oral malignancies. The average mortality rate is very different between genders, age groups, races and even countries. This difference originates from different habits of populations, preventive methods, and medications. By increasing the age, the risk of intraoral cancer increases (1).

New blood vessels formation is a critical step in tumor growth and invasion. Neovascularization simplifies metastatic spreading. Without new vascular formation, solid tumors fail to growth over than 2 mm.

Accordingly, vascular density correlates with prognosis of malignant tumors (2).

VEGF is a cytokine that promotes angiogenesis, sprouting of endothelial cells and vascular permeability (3). The VEGF expression significantly correlates with 5-year survival rate of patients (4). Studies have been shown that the expression of VEGF associates with tumor invasion pattern and metastasis. The high expression of VEGF accompanied with poor prognosis (5-7).

Obtained results on the relation of VEGF expression with pathologic differentiation and clinical stage are controversial. Some

¹. (Corresponding author) Associate Professor, Department of Oral and Maxillofacial Pathology, Faculty of Dentistry, Shahed University, Tehran, Iran. jalayer@shahed.ac.ir

². Associate Professor, Pathology Department, Institute Cancer, Tehran University of Medical Sciences, Tehran, Iran. hosp_cancer@tums.ac.ir

³. DDS, Shahed University, Tehran, Iran. sam_varnasari@yahoo.com

researchers concluded that the VEGF expression has not prognostic significance (8). By increasing the blood vessel capacity, the vessel density increases. The association between tumor microvessel density (MVD) with prognosis still controversial (9-11). The aim of the study was to determine the correlation between VEGF expression and vascular density with clinical and histopathologic features in OSCC.

Methods

Data

The study was retrospective with archive reviewing, judgmental (Purposive) sampling method. 22 formalin-fixed, paraffin embedded samples of OSCC were retrieved from the Pathology Department, Cancer Institute, Imam Khomeini hospital, Tehran, Iran. The samples were selected from fixed tissues with adequate tumoral mass. The presence of necrosis / hemorrhage, previous radiotherapy/ chemotherapy and incomplete medical record were exclusion criteria. By examining the hematoxylin-eosin stained slides, best samples based on inclusion criteria were selected. The demographic, clinical and pathologic data were registered from medical records.

The VEGF expression was detected immunohistochemically. The 3 μ m sections were prepared as follows for immunohistochemical examination: deparaffinized in xylene, placing in 0.01M Citrate/HCl Buffer (pH=6.00), heated in a microwave oven for 15 minutes. In room temperature, sections were rinsed with phosphate buffered saline (PBS), incubation with 1 μ g/ml diluted primary antimouse polyclonal antibodies (Dako, Denmark-VEGF) for 1 hour follow with biotinylated antibody for 30 minutes. The final step was incubation with peroxidase for 30 minutes, developed in 3,3' diaminobenzidine hydrochloride (DAB) and Mayer's staining. The sections were immersed in xylene and then mounted. Samples were rinsed with PBS between each incubation. The Phaeochromocytoma and colon tissue were positive and negative controls, respectively (12). The positive

expression of VEGF was considered by light to dark brown color of tumor cells.

Immunohistochemical scoring

VEGF expression was assessed by scoring the intensity of staining and the area of staining. Staining intensity was scored as follows: (Fig. 1) 0=no staining, 1=weak staining, 2=moderate staining, 3=strong staining (13).

The area of staining was scored as follows: (14)

0=no staining in any microscopic field

1=<25% of tumor cells stained positively

2=25%-75% of tumor cells stained positively

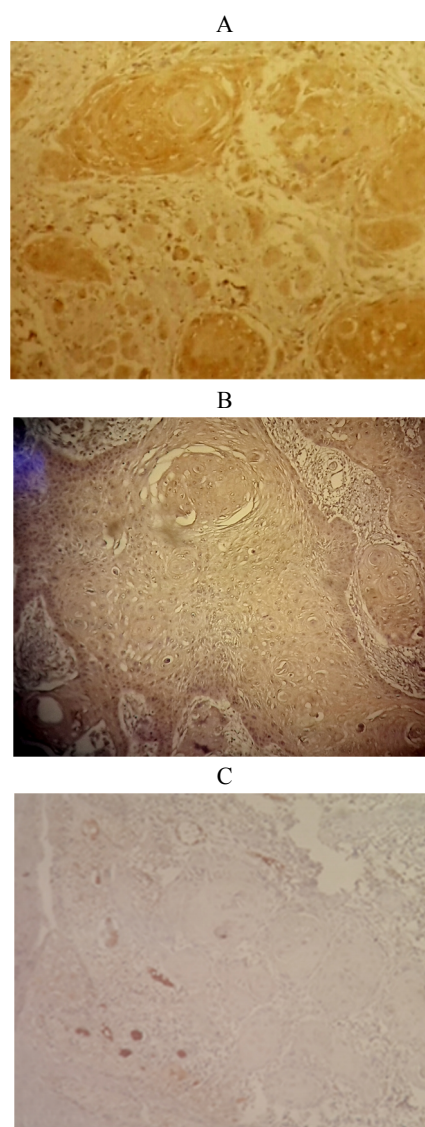


Fig 1. The immunostaining of VEGF (100 \times); A: Score 3(strong staining), B: Score 2(moderate staining), C: Score 0 (no staining)

3=more than 75% of tumor cells stained positively.

The assessment was completed by light microscopy (Zeiss, Japan) at $\times 100$.

For blood density assessment, 6 areas with highest number of vessels (hot spots) comprising of venous and artery were identified at $\times 40$ LPF under light microscopy (Zeiss, Japan). The value of counted the numbers of vessels in 6 areas was calculated for each sample. Counting was completed at $\times 100$ (0.3693mm² per optical area) with examining the hematoxylin-eosin stained slides (15).

The quantifications were completed blind. Counts were achieved in a front invasive aspect of the tumor within the tumor area.

Statistical analysis

The t-test, ANOVA, chi-square and Pearson Correlation Coefficient tests were employed for statistical analyzes using SPSS 13.0 software. $P < 0.05$ was considered as the statistical significance level.

Results

In this retrospective study, 13(59.1%) of 22 patients were males and 9 (40.9%) females. 18 (%81.8) of samples were from tongue, 2 (%9.1) from the floor of the mouth, 1(4.5%) from lip mucosa and 1 (4.5%) from the palate. Table 1 shows the summary of demographic and clinical data of samples.

Staining intensity of 4 (18.2%, Mean \pm Standard Deviation (M \pm SD)=49.5 \pm 16.74), 11 (50%, M \pm SD=58.45 \pm 16.58), 7 (31.8%, M \pm SD=64.85 \pm 16.60) were 3, 2 and 0, respectively.

There was no correlation between staining intensity of VEGF with age, gender, lymph node involvement, tumor size, tumor differentiation and blood density with Pearson Correlation Coefficient test ($p=0.35$, $p=0.41$, $p=0.38$, $p=0.15$, $p=0.34$ and $p=0.11$, respectively). The areas of VEGF staining of 7 (31.8%), 4 (18.2%), 3 (13.6%), 8 (36.4%) were 0, 1, 2 and 3, respectively.

There was no correlation between areas

Table 1. Frequency distribution of the demographic, clinical and histopathologic data

Demographic, clinical and histopathologic characteristics	Category	n (%)
Age (M \pm SD=58.9 \pm 16.69)	0-10	0
	11-20	0
	21-30	1 (5%)
	31-40	2 (9%)
	41-50	4 (18%)
	51-60	2 (9%)
	61-70	7 (32%)
	71-80	4 (18%)
	81-90	2 (9%)
	1	2 (9.1%)
Tumor size (cm) (M \pm SD=2.6 \pm 1.12cm)	1.3	1 (4.5%)
	1.5	1 (4.5%)
	2	8 (36.4%)
	2.5	2 (9.1%)
	3	3 (13.6%)
	4	3 (13.6%)
	4.5	2 (9.1%)
Lymph node involvement Diffrentiatuon	+	2 (9.1%)
	-	20 (90.9)
	Well	5 (22.7%)
	Moderate	17 (77.3%)
Blood density	12-20	8 (36/2%)
	21-40	6 (27/2%)
	41-60	3 (13/6%)
	61-80	3 (13/6%)
	81-100	1 (4.5%)
	101-120	1 (4.5%)

of VEGF staining with age, gender, lymph node involvement, tumor differentiation and blood density ($p=0.42$, $p=0.38$, $p=0.31$, $p=0.36$, and $p=0.78$, respectively). The areas of VEGF staining was significantly correlated with tumor size ($p=0.04$).

The Mean \pm SD of blood density was 40.72 ± 3.23 with ranging from 12 to 136 counts. The correlation between blood density with gender and tumor size was significant ($p=0.06$ and $p=0.05$, respectively). There was no correlation between blood density with age, lymph node involvement and tumor differentiation ($p=0.55$, $p=0.20$, and $p=0.80$, respectively). There was no correlation between the blood density and VEGF expression with Pearson Correlation Coefficient test ($p=0.78$).

Discussion

The study shows that angiogenesis is correlated with tumor size in oral squamous cell carcinoma. This finding defines by both VEGF expression and blood vessel density. Neovascularization is an important step in tumor progression and clinical outcome. The up-regulation of VEGF expression from normal oral mucosa to dysplasia and SCC has been indicated (16). It has been suggested that the VEGF-induced angiogenesis regulated by an autocrine system (17-18). This finding is compatible with this fact that VEGF keeps the tumor blood supply for further development.

The finding of this study shows that VEGF expression correlates with tumor size. No correlation was seen between VEGF expression with lymph node involvement, tumor differentiation, gender, and age.

The previously obtained results on the negative association between VEGF expression and histologic grade and lymph node metastases are compatible with this study (8-11). This finding is not compatible Sun et al. and Li et al. They showed higher expression of VEGF in metastatic squamous cell carcinoma of larynx and tongue in comparison with those without metastasis (5-19).

It has been shown that the VEGF expression in squamous cell carcinoma of the larynx is not correlated to age and gender (19). This is in agreement with the present study.

For the first time in 1991, Weidner et al. showed that the tumor angiogenesis measured by microvessel density correlates with metastasis (20). The relationship between microvessel density and prognosis has been demonstrated in malignant epithelial-derived tumors (21-24).

The current data showed a positive correlation between blood vessel density with gender and tumor size. The correlation between blood density with age, lymph node involvement and tumor differentiation was negative. This finding in part is consistent with previous reports but still some controversies exist. The correlation between blood vessel density and grade of the tumor were not significant. This finding is in agreement with previous reports (9-25). Another controversy is about lymph node involvement. Contrast to Artese et al. and Miyahara et al. blood vessel density was not associated with lymph node metastasis (11-26).

The expression of VEGF was not correlated to blood density. This is consistent with some reports (9-11,25-27), but in contrast to others (10-14,28,29). The study shows that angiogenesis correlates with tumor size in OSCC. The finding defines by both VEGF expression and blood vessel density. By increasing the tumor angiogenic volume, the microvessel density increases. Based on this fact, angiogenesis can be a predictor of the tumor progression.

The association between microvessel density and clinical outcome is still controversial. These dissimilarities mainly due to different methods for detecting the blood vessels such as employing different MVD detection methods, case selections, and immunohistochemical markers. Different endothelial markers such as Flt-4, CD105, CD 34 and D2-40 have been used for microvessel formation detection (5-9,26-30).

Some studies separate angiogenesis from

lymphangiogenesis. This is another reason of disagreement in reported data. Still other reports the correlation of both angiogenesis and lymphangiogenesis together with respect to clinical features.

The obtained results in measuring the density of the tumor blood vessels mainly relate to selection areas from peripheral or central part of the tumor or an even assortment of hotspot areas. This is another reason of dissimilarity between reports.

For achieving a precise result, more samples with more harmonized assessment methods need. Without a strict standardization in methodology, conflicting results on the correlation between reports will continue.

Along with immunohistochemical markers, MVD has been suggested as an alternate method for detecting of angiogenic activity in OSCC. MVD detects during any phase of neoplastic transformation (31-32). Using immunohistochemical markers and MVD are facing some discrepancies.

Immunostaining of vascular detecting markers depends on the degree of differentiation and maturation of the vessels (9). In MVD detection method, the obtained result depends on to the selected hotspot section. The selected section may not be descriptive of tumor state as a whole. By measuring the blood density passive and active vessels are not differentiated (14).

In the present study, we investigated the blood vessel density in the invasive front of the tumor without demarcation between blood and lymphatic vessels. Our data achieved by counting the all presented blood vessels in the section without regarding its type. Considering the present status of tumor can be a more available alternative in MVD evaluation. The most important limitation of the present study was the number of cases. By increasing the counts, more detailed results will achieve.

Conclusion

Blood vessels formation relates to tumor size. Controlling the tumor size by manipulating the blood vessels formation may con-

tribute to the inhibition of tumor progression in malignant tumors.

Acknowledgments

The authors thank Vaziri S., Daavoodi H., Ahad Pour Sefidan M., for laboratory processing techniques.

Conflict of interest

This research completed under financial support of Shahed University.

References

1. Neville BW, Damm DD, Allen CM, Bouquot JE. Oral and maxillofacial pathology. 3th ed. China: Saunders 2009; chapt 10:409.
2. Algire GH, Chalkey HW. Vascular reactions of normal and malignant tissue in vivo. Vascular reactions of mice to wounds and to normal and neoplastic transplant. J Natl Cancer Inst 1945;6:73-85.
3. Ferrara N, Davis-Smyth T. The Biology of Vascular Endothelial Growth Factor. Endocrine Reviews 1997;18(1):4-25.
4. Mineta H, Miura K, Ogino T, Takebayashi S, Misawa K, Ueda Y. Vascular endothelial growth factor (VEGF) expression correlates with p53 and ki-67 expressions in tongue squamous cell carcinoma. Anticancer Res 2002;22(2B):1039-1044.
5. Li QL, Chen FJ, Zeng ZY, Yang AK, Wu QL, Zhang HZ, et al. Expression and clinical significance of VEGF-C and Flt-4 in tongue squamous cell carcinoma. Ai Zheng 2006;25(2):235-240.
6. Martin SG, Orridge C, Mukherjee A, Morgan DA. Vascular endothelial growth factor expression predicts outcome after primary radiotherapy for head and neck squamous cell cancer. Clin Oncol (R Coll Radiol) 2007;19(1):71-76.
7. Siriwardena B, Kudo Y, Ogawa I, Udagama K, Tilakaratne WM, Takata T. VEGF-C is associated with lymphatic status and invasion in oral cancer. J Clin Pathol 2008;61(1):103-108.
8. Salven P, Heikkilä P, Anttonen A, Kajanti M, Joensuu H. Vascular endothelial growth factor in squamous cell head and neck carcinoma: expression and prognostic significance. Mod Pathol 1997;10(11):1128-1133.
9. Kukreja I, Kapoor P, Deshmukh R, Kulkarni V. VEGF and CD 34: A correlation between tumor angiogenesis and microvessel density-an immunohistochemical study. J Oral Maxillofac Pathol 2013;17(3):367-73.
10. Li C, Shintani S, Terakado N, Klosek SK, Ishikawa T, Nakashiro K, et al. Microvessel density and expression of vascular endothelial growth factor, basic fibroblast growth factor, and platelet-derived endothelial growth factor in oral squamous

cell carcinomas. *Int J Oral Maxillofac Surg* 2005; 34(5):559-65.

11. Artese L, Rubini C, Ferrero G, Fioroni M, Santinelli A, Piattelli A. Microvessel density (MVD) and vascular endothelial growth factor expression (VEGF) in human oral squamous cell carcinoma. *Anticancer Res* 2001;21(1B):689-95.

12. Jalayer Naderi N, Tirgari F, KharaziFard MJ, Farahani Parsa F. A study on the relationship between clinical features with Ki67 expression and eosinophil cells infiltration in oral squamous cell carcinoma. *Med J Islam Repub Iran* 2014;28:115.

13. Jalayer Naderi N, Tirgari F, Esmaili F, Paktinat F, Keshavarz Z. Vascular Endothelial Growth Factor and Ki-67 Antigen Expression in Relation to Age and Gender in Oral Squamous Cell Carcinoma. *J Dent Res Dent Clin Dent Prospect* 2012; 6(3):103-107.

14. Astekar M, Joshi A, Ramesh G, Metgud R. Expression of vascular endothelial growth factor and microvessel density in oral tumorigenesis. *J Oral Maxillofac Pathol* 2012;16(1):22-26.

15. Liang X, Yang D, Hu J, Hao X, Gao J, Mao Z. Hypoxia inducible Factor-1alpha expression correlates with Vascular Endothelial Growth Factor-C expression and lymphangiogenesis/angiogenesis in oral squamous cell carcinoma. *Anticancer Res* 2008;28:1659-1666.

16. Johnstone S, Logan RM. Expression of vascular endothelial growth factor (VEGF) in normal oral mucosa, oral dysplasia and oral squamous cell carcinoma. *Int J Oral Maxillofac Surg* 2007;36(3): 263-6.

17. Lalla RV, Boisoneau DS, Spiro JD, Kreutzer DL. Expression of vascular endothelial growth factor receptors on tumor cells in head and neck squamous cell carcinoma. *Arch Otolaryngol Head Neck Surg* 2003;129(8):882-8.

18. Seghezzi G, Patel S, Ren CJ, Gualandris A, Pintucci G, Robbins ES, et al. Fibroblast growth factor-2 (FGF-2) induces vascular endothelial growth factor (VEGF) expression in the endothelial cells of forming capillaries: an autocrine mechanism contributing to angiogenesis. *J Cell Biol* 1998;141(7):1659-1673.

19. Sun D, Wang Y, Kong W, Liu B, Chen X, Zhang D, et al. The expressions of Ki67 and VEGF in squamous cell carcinoma of larynx and the correlation between the two marks. *Lin Chuang Er Bi Yan Hou Ke Za Zhi* 2004;18(2):93-6.

20. Weidner N, Semple JP, Welch WR, Folkman J. Tumor angiogenesis and metastasis-correlation in invasive breast carcinoma. *N Engl J Med* 1991; 324(1):1-8.

21. Gasparini G, Weidner N, Maluta S, Pozza F, Boracchi P, Mezzetti M, et al. Intratumoral microvessel density and p53 protein: Correlation with metastasis in head-and-neck squamous cell carcinoma. *Int J Cancer* 1993;55(5):739-744.

22. Visscher DW, Smilantetz S, Drozdowicz S,

Wykes SM. Prognostic significance of image morphometric microvessel enumeration in breast carcinoma. *Anal Quant Cytol Histol* 1993;15(2):88-92.

23. Bigler SA, Brawer MK, Deering RE. Vessel density in carcinoma of the prostate: Comparing organ confined tumors with stage D tumors. *Mod Pathol* 1993;6:56a.

24. Qian C, Min H, Liang X. Preliminary study on the correlation between neovasculature and metastatic nasopharyngeal carcinoma by computer image analysis. *Zhonghua Er Bi Yan Hou Ke Za Zhi* 1998;33(2):106-109.

25. Tae K, El-Naggar AK, Yoo E, Feng L, Lee JJ, Hong WK, et al. Expression of vascular endothelial growth factor and microvessel density in head and neck tumorigenesis. *Clin Cancer Res* 2000;6(7):2821-8.

26. Miyahara M, Tanuma J, Sugihara K, Semba I. Tumor lymphangiogenesis correlates with lymph node metastasis and clinicopathologic parameters in oral squamous cell carcinoma. *Cancer* 2007;110(6):1287-94.

27. Chen SX, Li XY, Kong XL, Feng Y. [The expression of vascular endothelial growth factor-C in oral squamous cell carcinoma and its associations with angiogenesis, lymphangiogenesis and lymph node metastasis]. *Hua Xi Kou Qiang Yi Xue Za Zhi* 2010; 28(3):319-23.

28. Sugiura T, Inoue Y, Matsuki R, Ishii K, Takahashi M, Abe M, et al. VEGF-C and VEGF-D expression is correlated with lymphatic vessel density and lymph node metastasis in oral squamous cell carcinoma: Implications for use as a prognostic marker. *Int J Oncol* 2009;34(3):673-80.

29. Riedel F, Götte K, Schwalb J, Bergler W, Hörmann K. [Coexpression of VEGF and bFGF is associated with increased vascular density in head and neck carcinomas]. *Laryngorhinootologie* 2000; 79(12):730-5.

30. Watanabe S, Kato M, Kotani I, Ryoke K, Hayashi K. Lymphatic Vessel Density and Vascular Endothelial Growth Factor Expression in Squamous Cell Carcinomas of Lip and Oral Cavity: A Clinicopathological Analysis with Immunohistochemistry Using Antibodies to D2-40, VEGF-C and VEGF-D. *Yonago Acta Med* 2013; 56(1):29-37.

31. Sedivy R, Beck-Mannagetta J, Haverkamp C, Battistutti W, Honigschnabl S. Expression of vascular endothelial growth factor- C correlates with the lymphatic microvessel density and the nodal status in oral squamous cell carcinoma. *J Oral Pathol Med* 2003; 32(8):455-60.

32. Iamaroon A, Pongsiriwet S, Jittidecharaks S, Pattanaporn K, Prapayasatok S, Wanachantararak S. Increase of mast cells and tumor angiogenesis in oral squamous cell carcinoma. *J Oral Pathol Med* 2003;32(4):195-9.