

Transpupillary thermotherapy of occult subfoveal choroidal neovascularization secondary to age related macular degeneration

M. H. Dehghan, MD,¹ M. Soheilian, MD,² J. Naghibozakerin, MD,³ and A. Papi, MD,⁴

Department of Ophthalmology and Ophthalmic Research Center, Labbafinejad Medical Center, Shaheed Beheshti Medical University, Tehran, I.R. Iran, and the Negah Eye Center, Tehran, I.R. Iran.

Abstract

Background: Transpupillary thermotherapy is a new treatment for subfoveal choroidal neovascularization which needs further evaluation. This study was aimed to evaluate the efficacy of transpupillary thermotherapy on regression of occult subfoveal choroidal neovascularization with or without pigment epithelial detachment in patients with age-related macular degeneration.

Methods: In a case series study, patients with age-related macular degeneration who had occult subfoveal choroidal neovascularization less than 4 disc diameters with or without pigment epithelial detachment underwent transpupillary thermotherapy by diode laser. The patients were followed for 1-12 months. Main outcome measures were visual acuity changes, flattening of pigment epithelial detachment observed clinically, or absence of leakage in angiography. The data were analyzed using T-test and chi-square.

Results: The study included 30 eyes of 30 patients. Mean age of the patients was 67 ± 7 years. Mean follow up time was 5.3 ± 0.5 months. Visual acuity improved in 63%, remained unchanged in 20%, and worsened in 17%. Mean visual acuity improved from 1.25 ± 0.4 log MAR (20/320) to 1.06 ± 0.36 log MAR (20/200), ($p < 0.04$). Choroidal atrophy or flat scar was achieved in 73% and failure to treatment was seen in 27%, ($p = 0.0001$). Pigment epithelial detachment flattened in all cases after transpupillary thermotherapy.

Conclusion: Transpupillary thermotherapy may be a particularly useful modality for treating occult subfoveal choroidal neovascularization associated with serous pigment epithelial detachment in selected cases of age-related macular degeneration.

Keywords: Age-related macular degeneration, Choroidal neovascularization, Diode laser, Pigment epithelial detachment, Transpupillary thermotherapy.

Intoduction

Age-related macular degeneration (ARMD) is one of the leading causes of visual im-

pairment in the world. Severe visual loss in ARMD is mainly due to choroidal neovascularization (CNV), which appears as a subretinal fibrovascular proliferation in the macular area [1,2] Currently, the argon

1. Department of Ophthalmology and Ophthalmic Research Center.

2. **Corresponding author:** Department of Ophthalmology and Ophthalmic Research Center, Labbafinejad Medical Center, Boostan 9 St., Pasdaran Ave., Tehran, I.R. Iran. Tel: (98) 21 22587317, Fax: (98) 21 22562138, email: masoud_soheilian@yahoo.com

3. Department of Ophthalmology and Ophthalmic Research Center.

4. Negah Eye Center, Tehran, I.R. Iran.

laser is widely used for the treatment of perifoveal and extrafoveal CNV and prevents severe visual loss, however it destroys the neurosensory retina and in the case of subfoveal CNV leads to severe visual loss [3,5].

Unfortunately, in almost 90% of the patients with ARMD who have visual loss secondary to macular CNV, the argon laser is not useful because of large, occult, or subfoveal CNV [2]. Lack of a definite treatment for CNV especially the subfoveal type has evolved various therapeutic modalities like photodynamic therapy (PDT) [6], radiotherapy [7], macular surgery [8,9], trans-scleral diopexy [10], intraocular and subtenon steroid injection, [11], interferon α -2a [12], oral thalidomide [13], and transpupillary thermotherapy (TTT) [14].

Transpupillary thermotherapy is a new treatment that has been suggested for small choroidal melanoma and CNV. In this method, a diode laser beam ($\lambda = 810$ nm) with a spot size of 500-3000 μ and a power of 300-900 mw is delivered to the choroids and retinal pigment epithelium through the pupil. Preferential absorption of the heat energy by CNV causes closure of choroidal vessels [15]. However, TTT may injure all layers of the retina [16]. It is also a much less expensive treatment than PDT and other treatment modalities. In a pilot study, TTT has controlled CNV of ARMD both clinically and angiographically in 94%, while visual acuity remained stable or improved in 75% of the eyes [3].

The efficacy of all new treatments in cases of occult CNV in association with pigment epithelial detachment (PED) is unclear and even PDT with its high cost is not effective for treatment of such cases. In this study we have evaluated the efficacy of TTT for the treatment of eyes with ARMD

who had occult CNV with or without PED.

Methods

This study was designed as a retrospective interventional case series. Patients with ARMD who presented to the Negah Eye Center in Tehran from 2001 to 2003, underwent a complete ophthalmic examination as well as fluorescein angiography (FAG). Those who had occult CNV with or without PED, size less than 4 disc diameter, and enough dilated pupil without media opacity were selected for TTT. Patients with any component of disciform scar, or another previous treatment were excluded from the study. An informed written consent was obtained. Then, TTT was performed using a diode laser at 810 nm (Viridis-Twin Diode Laser, Quantel Medical, France) with various parameters (spot size, power, and duration) through Goldman or Centralis contact lens. The spot size was adjusted at about 200 μ larger than the most peripheral limits of the largest dimension of the lesion. If the lesion was larger than 3000 μ multiple side by side spots were applied to cover the entire lesion. The power was selected according to the guidelines of our laser system proportional to the spot size with larger spots requiring higher power levels. In general, for a 2 mm spot size, the initial power level was 400 mw. As soon as a discoloration appeared, the laser was discontinued and reinitiated by a power of 100 mw lower than the previous setting.

The chosen duration was 60 seconds for all the eyes. The end point of each laser application was barely a visible color change. Laser was not applied to the subfoveal area of the CNV in eyes with a good fixation, however in most of the eyes the whole area of CNV including the fovea was treated as

PED* (No.)	Subretinal Fluid (No.)	Subretinal Hemorrhage (No.)	Mean CNV Size (DD)	Mean Spot Size (μ)	Mean Power (mw)	Mean Pre-TTT VA	Mean Post- TTT VA	CA† or FCS‡ (No.)	Disciform Scar (No.)
12	22	17	3	1441	445	20/320	20/200	22	8

* PED: pigment epithelial detachment. † CA: choroidal atrophy. ‡ FCS: flat choroidal scar

Table 1. Characteristics of 30 patients with occult CNV secondary to ARMD who underwent TTT.

well. Retreatment was performed if flattening of the PED or decreasing of the subretinal hemorrhage, fluid or exudation didn't occur after a waiting period of at least 6 weeks.

After TTT, the patients were followed at 6 weeks, 3, 6, and 12 months if there was an appropriate response. At each follow up a complete ophthalmic examination was performed. Main outcome measures were visual acuity changes, flattening of the PED observed clinically, and the presence or absence of leakage in angiography. Statistical analysis of data was performed by T-test and chi-square.

Results

The study included 30 eyes of 30 patients. Twenty-two cases (73%) were males. The mean age of the patients was 67 ± 7 years (range, 55 to 78 years). The mean laser spot size was $1478 \pm 664 \mu$ (range, 500 to 3000 μ). The mean laser power was 445 ± 121 mw

(range, 300-800 mw). The duration of laser was 60 seconds for all the eyes. The mean follow up time was 5.3 ± 0.5 months (range, 1 to 12 months).

Initial visual acuity was better than 1/10 in 37% of the eyes while after TTT, 43% had visual acuity of better than 1/10. Visual acuity improved in 19 (63%) eyes, unchanged in 6(20%), and worsened in 5(17%). The mean visual acuity improved from 1.25 ± 0.4 log MAR (20/320) to 1.06 ± 0.36 log MAR (20/200) which means 2 lines visual improvement ($p < 0.04$), (Table 1).

Twelve (40%) eyes had PED, which was large (involving the whole posterior pole) in two, (Table 2). Subretinal fluid was observed in 22 (73%) eyes, 67% of which responded to the laser therapy. Subretinal hemorrhage was seen in 17(57%) eyes, which persisted in 5 (28%) of them even after the TTT ($p < 0.05$). TTT retreatment was required in 2 (7%) eyes, which finally resulted in visual acuity of 20/30 in one, and

No	Sex/Age	SRF* /SRH†	CNV Size (DD)	Spot Size (μ)	Power (mw)	Pre-TTT VA	Post-TTT VA	CA‡ or FCS§	Disciform Scar
1	F/59	+/+	2	1500	400	20/500	20/200	+	-
2	M/60	+/-	3	1500	450	20/500	20/500	+	-
3	M/60	+/+	1	2500	600	20/800	20/200	-	+
4	M/60	+/+	2	3000	800	20/800	20/800	-	+
5	M/65	+/-	1	500	360	20/200	20/200	-	+
6	M/70	+/-	3	2000	550	20/400	20/400	+	-
7	M/57	+/-	3	1500	400	20/160	20/400	+	-
8	M/66	+/+	1	2000	300	20/400	20/60	+	-
9	F/74	+/+	2	2000	480	20/2000	20/2000	+	-
10	M/77	+/-	2	1600	380	20/500	20/250	-	+
11	F/67	+/-	1	800	450	20/65	20/30	+	-
12	F/78	+/+	4	1500	380	20/600	20/60	+	-

* SRF: subretinal fluid. † SRH: subretinal hemorrhage. ‡ CA: choroidal atrophy. § FCS: flat choroidal scar.

Table 2. Characteristics of patients with pigment epithelial detachment in association with occult CNV secondary to ARMD who underwent TTT.

20/60 in the other.

Anatomical success defined as appearance of choroidal atrophy or flat scar was achieved in 22(73%) eyes and failure defined as appearance of disciform scar, recurrent or persistent CNV was seen in 8(27%), ($p=0.0001$). All the PEDs even large lesions responded well to the TTT without any RPE rupture (Fig. 1A-D). Neither anterior nor posterior segment complications of TTT were observed in this series.

Conclusion

For the first time, TTT was used in conjunction or after plaque radiotherapy for

treatment of small choroidal melanoma that failed to respond to the plaque radiotherapy alone by Oosterhuis and coworkers [17] in 1995. It probably affects the choroidal vessels by hyperthermia. Hyperthermia damages the endothelium of CNV or tumor vessels and results in platelet aggregation, blood cell adhesion, thrombosis and obstruction of vessels, release of vasoactive molecules, and increased vascular permeability [14]. Yet more has to be done to reveal the exact overlying mechanisms. The concept of minimizing collateral damage to adjacent or overlying retina is the rationale behind PDT and indocyanine

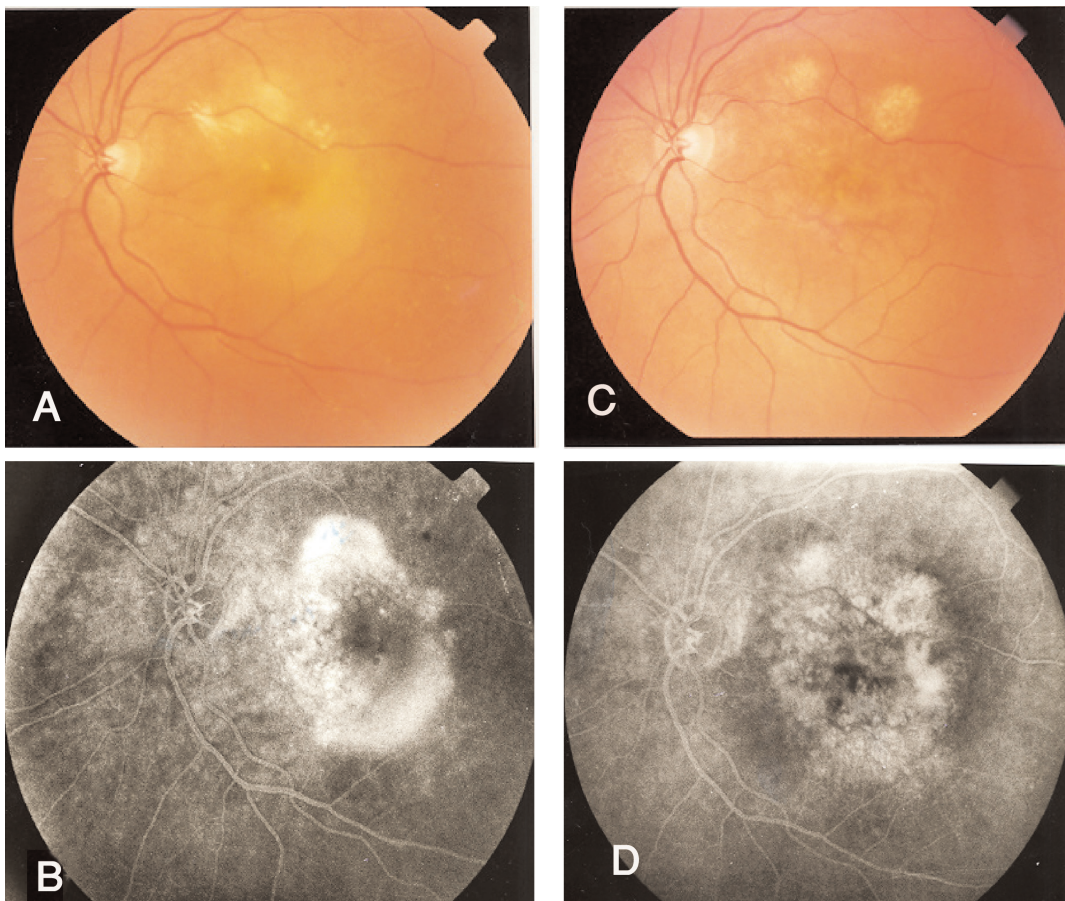


Fig.1 A-D. (A) A large pigment epithelial detachment in an eye of a 70-year-old lady with CNV secondary to ARMD and visual acuity of counting fingers, and (B) its FAG before TTT. (C) Same eye after TTT, which shows flattening of the PED and (D) faint staining of the scar in FAG (visual acuity improved to 20/200).

green-enhanced diode laser treatment. TTT may also minimize the collateral damage, and the theoretical advantage of its lower thermal energy compared with traditional laser photocoagulation is the point of interest for most researchers. However, Peyman and coworkers [16] in an experimental animal study have shown that TTT using diode laser injures all layers of the retina.

CNV of ARMD was treated with TTT by Reichel and coworkers [3] for the first time in 1999. In their study of 16 eyes, the visual acuity improved 2 or more lines in 19%, unchanged in 56%, and decreased in 25%. They considered the reduction of the exudation as a sign of vascular occlusion and it was observed in 94% of the eyes, however simultaneous evaluation of the occult and classic CNV may be a source of bias in their study. In our study, the number of eyes was almost twice Reichel's study and in addition to reduction of the exudation, appearance of a flat scar or choroidal atrophy was also considered as a sign of treatment response. By this definition, 73% of our patients responded to TTT. It should be noted that although disciform scar causes reduction of exudation, it is not a sign of successful treatment.

In our study, all the PEDs responded well to TTT and did not demonstrate any complication related to laser thermal therapy. Karel and coworkers [18] in a study of 30 eyes have reported that after TTT, serous PED re-attached in 13 eyes (43%).

In a study by Stevens and coworkers [6], the natural course of the CNV was evaluated in eyes with ARMD. They reported that during 9-12 months, the size of the occult CNV increased more than 2-times in 32%, the classic CNV enlarged in 52%, and the mean visual acuity decreased 2.5 lines. Newsom and coworkers [19] have reported that the occult neovascular membrane of

ARMD regressed by TTT in 78%. Newsom and coworkers [20] also showed good stability of both occult and classic CNV after TTT with little visual loss and few recurrences during 28 months follow up. In our study it was shown that TTT not only improved the mean visual acuity (2 lines), but also resulted in anatomical success (73%).

One of the problems of TTT is the choosing of appropriate laser parameters. The amount of fundus pigmentation [21,23], and the CNV size [23] are important factors to choose the laser parameters. Eyes with pigmented fundus, or small lesions need lower laser power. Also, excessive lens pressure on the globe decreases the choroidal blood flow and in turn increases the laser thermal effect [24].

In the absence of a definite treatment for ARMD especially those in association with PED, and weak effect of the other methods like PDT which is also costly and often requires retreatment, TTT may be considered as a more economic and effective replacement. The validity of all these conclusions needs to be proven in a randomized clinical trial. Also, TTT should be compared with PDT in a randomized study.

References

1. Ferris F, Fine S, Hyman L. Age-related macular degeneration and blindness due to neovascular maculopathy. *Arch Ophthalmol* 1984; 102: 1640-1642.
2. Freund KB, Yannuzzi LA, Sorenson JA. Age-related macular degeneration and choroidal neovascularization. *Am J Ophthalmol* 1993; 115:786-791.
3. Reichel E, Berrocal AM, Ip M, Kroll AJ, Desai V, Duker JS, Puliafito CA. Transpupillary thermotherapy of occult subfoveal choroidal neovascularization in patients with age-related macular degeneration. *Ophthalmology* 1999; 106:1908-1914.
4. Shields CL, Shields JA, Perez N, Singh AD,

- Cater J. Transpupillary thermotherapy for small choroidal melanoma in 256 consecutive cases. *Ophthalmology* 2002; 109:225-234.
5. Macular Photocoagulation Study Group: Visual outcome after laser photocoagulation for subfoveal choroidal neovascularization secondary to age-related macular degeneration: the influence of initial lesion size and initial visual acuity. *Arch Ophthalmol* 1994;112:480-488.
6. Stevens TS, Bressler NM, Maguire MG, Bressler SB, Fine SL, Alexander J, et al. Occult choroidal neovascularization in age-related macular degeneration. A natural history study. *Arch Ophthalmol* 1997; 115:345-350.
7. The Radiation Therapy for Age-related Macular Degeneration (RAD) Study Group: A prospective randomized double-masked trial on radiation therapy for neovascular age-related macular degeneration (RAD) study. *Ophthalmology* 1999; 106:2239-2247.
8. Bressler NM, Bressler SB, Hawkins BS, Marsh MJ, Sternberg P Jr, Thomas MA. Submacular Surgery Trials Pilot Study Investigators: Submacular surgery trials randomized pilot trial of laser photocoagulation versus surgery for recurrent choroidal neovascularization secondary to age-related macular degeneration: I. Ophthalmic outcomes submacular surgery trials pilot study report number 1. *Am J Ophthalmol* 2000;130:387-407.
9. Fujikado T, Ohji M, Hayashi A, Kusaka S, Tano Y. Anatomical and functional recovery of the fovea after foveal translocation surgery without large retinotomy and simultaneous excision of a neovascular membrane. *Am J Ophthalmol* 1998; 126:839-842.
10. Venkatesh P, Gupta RK, Verma L, Tawari HK. Evaluation of trans-scleral diode laser using diopexy probe for subfoveal choroidal neovascular membrane in age related macular degeneration. *J Clin Laser Med Surg* 2004; 22:91-97.
11. Challa JK, Gillies MC, Penfold PL, Gyory JF, Hunyor AB, Billson FA. Exudative macular degeneration and intravitreal triamcinolone: 18 months follow up. *Aust NZJ Ophthalmol* 1998; 26:277-281.
12. Pharmacological Therapy for Macular Degeneration Study Group: Interferon α -2a is ineffective for patients with choroidal neovascularization secondary to age-related macular degeneration. Results of a prospective randomized placebo-controlled clinical trial. *Arch Ophthalmol* 1997; 115: 865- 872.
13. Bird AC. What is the future of research in age-related macular disease? *Arch Ophthalmol* 1997; 115:1311-1312.
14. Lanzetta P, Michieletto P, Pirracchio A, Bandello F. Early vascular change induced by transpupillary thermotherapy of choroidal neovascularization. *Ophthalmology* 2002; 109:1098-1104.
15. Kumar A, Prakash G, Singh RP. Transpupillary thermotherapy for idiopathic subfoveal choroidal neovascularization. *Acta Ophthalmol Scand* 2004; 82:205-208.
16. Peyman GA, Genaidy M, Yoneya S, Men G, Ghahramani F, Kuo P, Bezerra et al. Transpupillary thermotherapy threshold parameters: effect of indocyanine green pretreatment. *Retina* 2003; 23:378-386.
17. Oosterhuis JA, Journee-de Korver HG, Katebeke-Kemme HM, Blecker JC. Transpupillary thermotherapy in choroidal melanomas. *Arch Ophthalmol* 1995; 113:315-321.
18. Karel I, Zalava J, Boguszakova J, Dubska Z, Lestak J. Transpupillary thermotherapy in age-related serous detachment of retinal pigment epithelium. *Cesk Slov Oftalmol* 2004; 60:89-97.
19. Newsom RSB, Mc Alister JC, Saeed M, Mchugh JDA. Transpupillary thermotherapy for the treatment of choroidal neovascularization. *Br J Ophthalmology* 2001; 85:173-178
20. Newsom RS, McAlister JC, Saeed M, El-Ghonemy K, McHugh JD. Results 28 months following TTT for classic and occult CNV in patients with ARMD. *Ophthalmic Surg Laser Imaging* 2005; 36:94-102.
21. Atarashi T, Tamaki Y, Inoue Y, Obata R, Muranaka K, Yanagi Y. Transpupillary thermotherapy for treatment of exudative age-related macular degeneration in Japanese patients. *Eye* 2004;18:615-618.
22. Nagpal M, Nagpal K, Sharma S, Puri J, Nagpal PN. Transpupillary thermotherapy for treatment of choroidal neovascularization secondary to age-related macular degeneration in Indian eyes. *Indian J Ophthalmol* 2003; 51:243-250.
23. Peyman GA, Genaidy M, Moshfeghi DM, Ghahramani F, Yoneya S, Men G, Kuo P, et al. Transpupillary thermotherapy threshold parameters: fundusoscopic, angiographic, and histologic findings in pigmented and nonpigmented rabbits. *Retina* 2003; 23:371-377.
24. Friberg TR, Mainster MA. Transpupillary thermotherapy — introduction. *Semin Ophthalmol* 2001; 16:53-54.