

Alveolar Hydatid disease: a case report

S.H. Fattahi Masoom, MD.¹, and, N. Sharifi, MD.²

Department of General and Thoracic Surgery and Pathology, Ghaem Hospital, Mashad, Iran.

Abstract

Alveolar hydatid disease is caused by *E. multilocularis*. Human infection occurs at the larval stage of this small tape worm (1.2 to 4.5 mm). In this article we studied alveolar hydatid disease in a 50 year old woman who presented with a hepatic mass. Liver biopsy and histopathologic evaluation showed alveolar hydatidosis of the liver. Then resection of the left lobe of liver was done, with medical treatment with oral Albendazole (15 mg/kg/12h) for 6 weeks with 2 week intervals. The drug was continued for 4 courses. 5 year follow up of the patient was satisfactory without any complaint.

Keywords: Alveolar Hydatidosis, Liver, Echinococcus, Albendazole

Introduction

Human alveolar echinococcosis is a devastating disease that takes a malignant clinical course by an indolent morbidity and a high mortality. Most cases originated from rural communities in the northern hemisphere occurring in South Germany, North Switzerland, North Canada, and Alaska. Foxes are the important hosts of the adult worms in nature, but dogs and cats also become infected. The natural intermediate hosts of *E. multilocularis* are field mice and other small rodents in addition to man and monkey. Transmission to human occurs when eggs of the tape worm excreted by the final hosts are accidentally ingested [1, 2].

Multilocular hydatid cyst forms an aggregate of small cysts less than pea size. The larva's primary target organ is the liver,

where it proliferates slowly, but the larva also spreads into extrahepatic structures and even metastasizes to distant organs. The mortality rate used to exceeded 90% within 10 years. The introduction of benzimidazole for alveolar echinococcosis treatment in 1976 has considerably improved the prognosis [3]. Radical surgical excision is the only curative treatment [4].

Case report

A 50 year-old woman presented with an abdominal mass in 2002. She had been suffering from dyspepsia and heart burn. On physical exam she was a sick patient with weight loss and a mass in the right upper quadrant. Sonography demonstrated a liver mass with dense echo and cystic component.

The patient underwent laparotomy for biopsy that revealed multiples nodules of the liver with extension to the stomach and duodenum. Liver biopsy was done and histopathologic examination performed.

1. **Corresponding author**, Department of General and Thoracic Surgery and Pathology. Address: Ghaem Hospital, Ahmadabad st. Mashad, Iran. Tel: +98511 8400001-9, Fax: +98511 8409612, email: sh.fatahi@yahoo.com

2. Department of General and Thoracic Surgery and Pathology, Ghaem Hospital, Mashad, Iran. Email: Nourieh_sharifi@yahoo.com

Alveolar hydatid cyst of the liver was diagnosed through biopsy material (Fig. 1). After general condition improved, Laparotomy and left lobe hepatectomy and complete excision of the lesion was done (Figs. 2, 3). Then the patient received Albendazole according to a research protocol from the Ghaem hospital surgery department, 10-15 mg/kg/12h for 6 weeks and two week intervals. The drug was continued for 4 courses [14]. After one course of treatment liver sonography was done for evaluation of complications and results. Follow up of the patient showed no recurrence or metastasis.

Discussion

Alveolar hydatid disease is one of three forms of hydatidosis that occurs as a result of ingesting eggs of the tapeworm *E. multilocularis*. It is considered to be the most pathogenic zoonosis in temperate and arctic regions of the northern hemisphere [5]. The first cases were recorded in Japan in 1928 and since then forty-nine cases have been reported up to 1978. Surveillance for alveolar echinococcosis in central Europe was initiated in 1998. The liver is involved in over 90 percent of human infections, however multilocular echinococcosis often gives rise to metastases to other organs and metastases occur more frequently in unilocular hydatidosis. Metastases of multilocular hydatidosis to brain, bone, bone marrow, lung, spleen, heart and soft tissues have been reported [6,7]. Pathologically the nature of multilocular hydatid cyst is the formation of an aggregate of innumerable small cysts and the cut surface of involved tissue has the appearance of a honeycomb, and marked connective tissue reaction is seen around the cysts. The size of cysts increases by endogenous budding and the cysts gradually produce a tumor-like

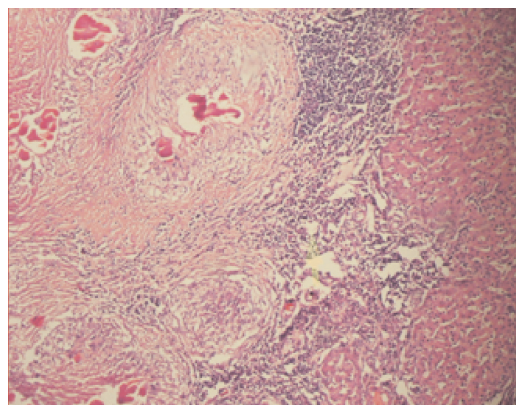


Fig. 1. Microscopic view shows liver tissue with alveolar hydatidosis (H&E \times 400).

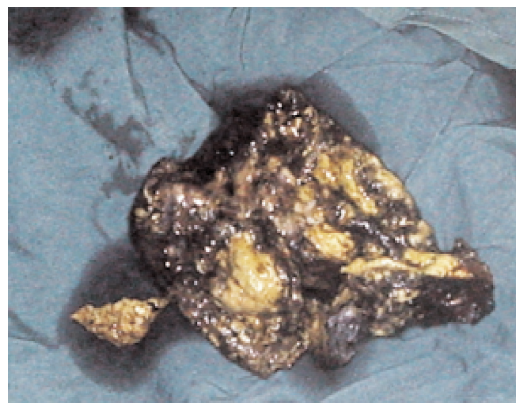


Fig. 2. Excision of left liver lobe.

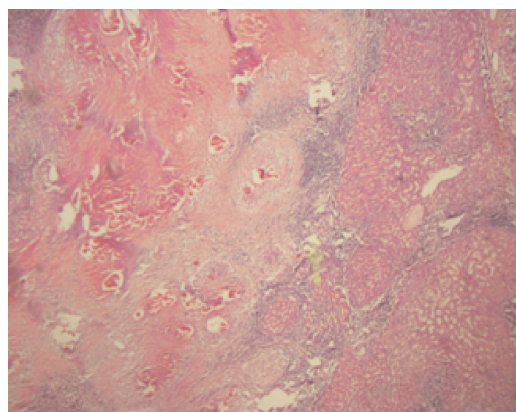


Fig. 3. Microscopic view shows liver tissue with multiple foci of alveolar hydatidosis (H&E \times 400).

mass [8, 9]. The tumor proliferates in contact with liver parenchyma by extension and the involved organ may undergo pronounced enlargement. Therefore it may cause typical symptoms such as hepatomegaly or jaundice by portal obstruction with depression of the liver function. Individual vesicles having an inner germinal layer can produce daughter cysts with scolices inside. Clinically upon palpation tumors are felt to be irregular with various sizes [10]. Consistency is usually firm but fluctuation is demonstrated especially when degeneration takes place centrally. Liver involvement by *E. multilocularis* manifested by hepatomegaly that must be distinguished from hepatoma. At times x-ray findings indicate calcification in the liver. The most reliable method of diagnosis is examination of the involved organ by biopsy, exploratory laparotomy or laparoscopy. Other methods such as immunologic tests are also applied, and complement fixation test, immunoelectrophoresis and hemagglutination tests are useful in untreated patients. Radical surgical excision is the only curative treatment [11,12,13]. Long-term medical treatment for prevention of recurrence after surgery is advised [3, 4,14].

References

1. Ammann RW, Eckert J. Cestodes, *Echinococcus*. *Gastroenterol Clin North Am* 1996; 25:655-89.
2. Schantz PM, Van den Bossche H, Eckert J. Chemotherapy for larval echinococcosis in animals and humans: report of a workshop. *Zeitschrift für Parasitenkunde* 1982; 67:5-26.
3. Wilson JF, Rausch RL, McMahon BJ, Schantz PM. Parasitocidal effect of chemotherapy in alveolar hydatid disease: review of experience with mebendazole and albendazole in Alaskan Eskimos. *Clin Infect Dis* 1992; 15:234-49.
4. Ishizu H, Uchino J, Sato N, Aoki S, Suzuki K, Kuribayashi H. Effect of albendazole on recurrent and residual alveolar echinococcosis of the liver after surgery. *Hepatology* 1997; 25: 528- 31.
5. Hegglin D, Bontadina F, Gloor S. From the alpine to the urban fox- adaptive behavior of the red fox (*Vulpes*). *Advances in Ecology* 1998; 33:119.
6. Nothdurft HD, Jelinek T, Mai A, Sigl B, Von Sonnenburg F, Loscher T. Epidemiology of alveolar echinococcosis in southern Germany (Bavaria). *Infection* 1995; 23:85-8.
7. Craig PS, Giraudoux P, Shi D, Bartholomot B, Barnish G, Delattre P, et al. An epidemiological and ecological study of human alveolar echinococcosis transmission in south Gansu, China. *Acta Trop* 2000; 77:167- 77.
8. Lee GW. An evaluation of eastern fox-hunting enclosures as sites of potential introduction and establishment of *Echinococcus multilocularis*. Athens, GA: University of GeorgiaThesi; 1992.pp.98.
9. Morris DL, Dykes PW, Marriner S, et al. Albendazole: objective evidence of response in human hydatid disease. *JAMA* 1987; 253: 2053-2057.
10. Wilson JF, Rausch RL. A clinical trial of mebendazole in the treatment of alveolar hydatid disease. *Am Rev Resp Dis* 1987; 118:747-757.
11. Eckert J, Conraths FJ, Tackmann K. Echinococcosis: an emerging or re-emerging zoonosis? *Int J Parasitol* 2000; 30: 1283-94.
12. Giraudoux P, Raoul F, Bardonnnet K, Vuillaume P, Tourneux F, Cliquet F, et al. Alveolar echinococcosis: characteristics of a possible emergence and new perspectives in epidemio-surveillance. *Medicine des Maladies Infectieuses* 2001; 31:247-56.
13. Ammann RW, Ilitsch N, Marincek B, Freiburg- haus AU. Effect of chemotherapy on the larval mass and the long-term course of alveolar echinococcosis. *Hepatology* 1994; 19:735-42.
14. Keshmiri M, Bahar Vahdat H, Fattahi SH, et al. A placebo controlled study of albendazole in the treatment of pulmonary echinococcosis. *Eur Respir J* 1999; 14:503-507.