

Fat necrosis secondary to pancreatitis mimicking transverse colon cancer: a case report

A. Sadeghi, MD,¹, H. Froutan, MD,², , and, S. Mirmomen, MD³.

Department of Gastroenterology, Imam Khomeini Hospital, Tehran University of Medical Science, Tehran, Iran.

Abstract

Fat necrosis secondary to pancreatitis can be either mild and self limited or create severe organ damage, but may rarely lead to abdominal opancreatic pseudotumor. We report a case of fat necrosis secondary to pancreatitis which clinically simulates transverse colon cancer.

Keywords: Fat necrosis, Pancreatitis, Abdominal mass

Introduction

Mesenteric fat necrosis can present as a pseudotumor a rare complication of pancreatitis. We present a case of fat necrosis secondary to pancreatitis which clinically simulated transverse colon cancer.

Case report

A 50-year-old woman complaining of recurrent epigastric and RUQ pain and significant weight loss from one year ago was admitted for further work up. The pain was intermittent and repeated every 2-3 weeks but between attacks she was well. It was not associated with fever or jaundice.

On physical examination: head and neck examination was normal without icter or lymphadenopathy, the lungs were clear and

no abnormal sound or murmur was heard on heart auscultation. On abdominal examination there was no mass, tenderness and organomegaly.

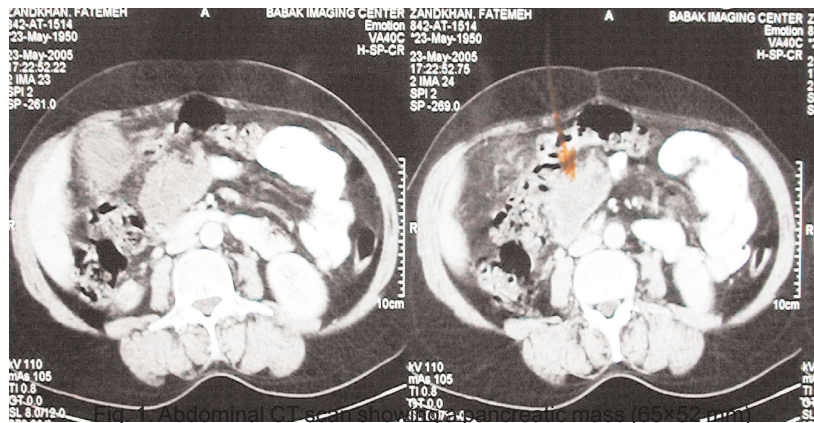
In paraclinical studies CBC was normal and there was no leukocytosis at presentation. Liver function tests, FBS, serum creatinine and electrolytes were all within normal limit. Increased ESR to 85 mm/hr and mild hyperamylasemia were the only positive findings in paraclinical studies (amylase = 383 u/l with upper limit of 200 Iu/l).

Upper GI endoscopy and small bowel transit were normal. Chest X-ray was normal. Ultrasonography showed a mildly dilated CBD (9mm) and a possible CBD stone (6mm), and a dilated gallbladder with two gallstones (22 mm, 8 mm) inside and a hypo-echoic pancreatic head mass (11×14mm) was also noted. Abdominal CT scan (Fig. 1) was performed that confirmed the pancreatic mass (65×52 mm).

1. **Corresponding author**, Assistant of internal medicine, Tehran University of Medical Sciences. Address: Endoscopic ward, 1st floor, Imam Khomeini Hospital, Keshavarz Boulevard, Tehran, Iran. Telefax: +98 21 66935456, email: amirsadeghi7651@yahoo.com

2. Professor of Gastroenterology, Tehran University of Medical Sciences, Imam Khomeini Hospital, Tehran, Iran

3. Gastroenterologist, Imam Khomaini Hospital, Tehran, Iran.



Endosonography was ordered for evaluation of the mass. It showed a dilated CBD (10 mm) that contained one stone (6mm) and sludge was seen in the gallbladder and CBD, necessitating ERCP. No mass was reported. ERCP was performed and showed a dilated CBD and small filling defect in it but pancreatic ducts were normal and after sphincterectomy large amounts of bile secretions and pus was discharged, but the patient's pain and condition did not change and she remained ill. For more evaluation of the pancreatic mass, the patient underwent a surgical consultation which the surgeon recommended a laparotomy with impression of pancreatic cancer.

The patient underwent an exploratory laparotomy 7 days later. During exploration, surgeons reported an inflamed gallbladder and a large stony and grossly tumoral mass of the transverse colon with extension towards the pancreas with peritoneal involvement and lymphadenopathy. Surgeons were so sure of the malignant nature of what they had seen that a radical surgery (cholecystectomy, choledocho-jejunostomy and transverse colectomy with lymphadenectomy) was performed. But surprisingly the histological study of the transverse mesocolon mass revealed fat necrosis and inflammation.

The story in our opinion should have

been cholecystitis, cholangitis and pancreatitis around eight weeks before admission which had been missed and led to rare complications such as fat necrosis and gallbladder walled-off perforation with local inflammatory reactions. Now after 8 months the patient is completely well without any medication.

Discussion

The incidence of acute pancreatitis in England, Denmark, and the United States varies from 4.8 to 24.2 per 100,000 patients [1]. We usually do not see acute pancreatitis as common as western countries because of prohibition of alcohol consumption in Islam. The most common etiology in our cases is cholelithiasis. Gallstones cause 35% of acute pancreatitis in the United States [1]. However, only 3% to 7% of patients with gallstones develop pancreatitis [2]. The risk of developing acute pancreatitis due to gallstones is relatively greater in men (relative risk, 14 to 35) than in women (relative risk, 12 to 25) [2].

However, more women develop gallstone pancreatitis because gallstones are more frequent in women [2]. While a stone passes through the papilla it can induce both cholangitis and pancreatitis and in contrary to common sense "the smaller the

stone is, the more severe the pancreatitis will be”.

Acute pancreatitis occurs more frequently when stones are less than 5 mm in diameter (odds ratio, 4:5) [3]. Small stones (microlithiasis) are more likely than large stones to pass through the cystic duct and cause ampullary obstruction [3]. Mild acute pancreatitis consists of minimal or no organ dysfunction and an uneventful recovery. Severe pancreatitis manifests as organ failure and/or local complications such as necrosis, abscess, or pseudocyst. Intra-abdominal fat necrosis, involving the mesentery, omentum, peritoneum, and peri-pancreatic fat and pancreas, is a common manifestation of pancreatitis.

Other less commonly involved distant sites include the mediastinum, pleura, bone marrow, central nervous system, and subcutaneous tissues.

Intra-osseous fat necrosis can simulate septic arthritis and osteomyelitis. Subcutaneous fat necrosis presents as subcutaneous nodules and pancreatic panniculitis.

Mesenteric fat necrosis can present as pseudotumor that is a rare complication of pancreatitis.

Etiologies of pancreatic disease associated with fat necrosis are many and include acute pancreatitis, chronic pancreatitis, carcinoma of the pancreas, pancreatic duct stones, trauma, ischemia, pancreatic cyst and pseudocyst, and insulinoma [4-10].

There is no report of fat necrosis which presents as a colon mass to present. Our opinion in this case is that fat necrosis of the transverses colon mesentery led to a pseudotumor-like mass lesion of the transverse colon.

This case bears in our mind that regardless of high radiologic and endoscopic technical developments, one cannot be a good clinician without skills in history tak-

ing and physical examination. This is only achievable by repeated experience, logical thinking and not relying monothemically on paraclinical data in routine practice.

References

1. Go VLW, Everhart JE. Pancreatitis. In: Everhart JE, editor. Digestive diseases in the US: Epidemiology and Impact. Washington DC: NIH; 1994. pp 693.
2. Moreau JA, Zinsmeister AR, Melton LJ, et al. Gallstone pancreatitis and the effect of cholecystectomy. *Mayo Clin Proc* 1988; 63:466.
3. Diehl AK, Holleman Jr DR, Chapman JB, et al. Gallstone size and risk of pancreatitis. *Arch Intern Med* 1997;157:1674.
4. Gil Grande JR. Gomez Pellico C. Solis Villa J. De Ramon Garrido E. Usera G. Miranda J. Cystic fat necrosis of the peritoneum. A nondescribed complication of pancreatitis. *Revista Clinica Espanola* 1979; 153(3):235-8 .
5. Chen H. Tsang Y. Wu C. Su C. Hsu JC. Perirenal fat necrosis secondary to hemorrhagic pancreatitis, mimicking retroperitoneal liposarcoma: CT manifestation. *Abdominal Imaging* 1996. 21(6):546 - 8.
6. Tiscornia OM. Celener D. Vaccaro MI. Cresta MA. Waisman H. Acute pancreatitis: physiopathogenic hypothesis of fat necrosis. *Medicina*. 1988; 48(5):530-42.
7. Filin VI. Krasnorogov VB. Aganezov SA. Vashetko RV. Lektorov VN. Pathogenesis and clinical significance of fat necrosis in acute pancreatitis. *Vestnik Khirurgii Imeni i - i - Grekova* 1987; 139 (8):40-5.
8. Aho HJ. Sternby B. Nevalainen TJ. Fat necrosis in human acute pancreatitis. An immunohistological study. *Acta Pathologica, Microbiologica, et Immunologica Scandinavica*. 1986; 94(2):101-5.
9. Dobbins WO, Liberman S. Acute pancreatitis with extensive peripheral fat necrosis simulating erythema nodosum and an abdominal cyst. *Med Annals of the District of Columbia* 1973; 42(7):319-22.
10. Aldridge MC, Francis ND, Glazer G, Dudley HA. Colonic complications of severe acute pancreatitis. *Br J Surg* 1989; 176:362-367.