

Enchondroma of the hand: the role of biopsy in the course of diagnosis and treatment

Davod Jafari¹, Hooman Shariatzadeh², Farid Najd Mazhar³
Mohammad Hossein Ghahremani⁴, Alireza Jalili⁵

*Department of Orthopedic Surgery, Division of hand surgery, Shafa Yahyaian Hospital,
Tehran University of Medical Sciences, Tehran, Iran.*

Received: 22 Apr 2011

Revised: 15 Aug 2011

Accepted: 20 Aug 2011

Abstract

Background: Enchondroma is the most frequent bone tumor of the hand, but chondrosarcoma is rare at this location. There is a high possibility of correct diagnosis of enchondroma and differentiating from its malignant counterpart by precise clinical and radiologic assessment without biopsy, a subject of debate in the literature. At the present study we substantially investigate this problem, in our patients.

Methods: Case records, radiographs, and histology of 52 solitary enchondroma patients who underwent operation in our hospital between 1998 and 2010, were reviewed. Special attention paid to pre and post-op diagnoses, and compared with each other.

Results: Eighty-six percent of our patients were between the second to fourth decades of life, with a slight female predominance. In all, the primary diagnosis of enchondroma according to clinical presentation and radiographic appearance, supported by intraoperative gross appearance of tumor, and confirmed histologically by permanent section analysis. There was no mismatch between radiologic and histologic diagnosis.

Conclusion: we concluded that correct diagnosis of enchondroma is almost always possible by precise clinical and radiographic assessment with no need for histologic confirmation before definitive treatment.

Keywords: enchondroma, hand, biopsy, treatment.

Introduction

Enchondroma, a benign cartilaginous lesion, is the most frequent primary bone tumor of the hand. Contrary to this, chondrosarcoma its malignant equivalent, is rare at this location [1,2].

Because of the relative similarities and ambiguity in clinical course, radiologic features, and microscopic appearance of these two entities, incisional biopsy in the shape of frozen section and if not responding, perma-

nent section was recommended in the literature, before definitive treatment of enchondromas [1, 3-6].

Enchondroma of the hand, most common in second to fourth decades, show increased cellularity and nuclear atypia in comparison to other sites, but has a good radiographic appearance including central lucent lesion with symmetric cortical expansion, and without any cortical destruction or soft tissue extension [1,3-5]. In comparison to this, hand chondrosarcoma commonly seen in

1. Associate Professor of Orthopedic Surgery, Tehran University of Medical Sciences, Tehran, Iran. djafari@tums.ac.ir

2. Assistant Professor of Orthopedic Surgery, Tehran University of Medical Sciences, Tehran, Iran. shariatzade-h@hotmail.com

3. Assistant Professor of Orthopedic Surgery, Tehran University of Medical Sciences, Tehran, Iran. fnajdmazhar@yahoo.com

4. (Corresponding author), MD. Clinical fellow of Hand Surgery, Department of Orthopedic Surgery, Shafa Yahyaian University Hospital, Baharestan Sq., Tehran, Iran. Tel: +9821 33542022, mhqahremani@yahoo.com

5. MD. Assistant Professor, Hormozgan University of Medical Sciences, Mohamadi Hospital, Bandar Abbas, Iran. alirezajalili.jalili@gmail.com

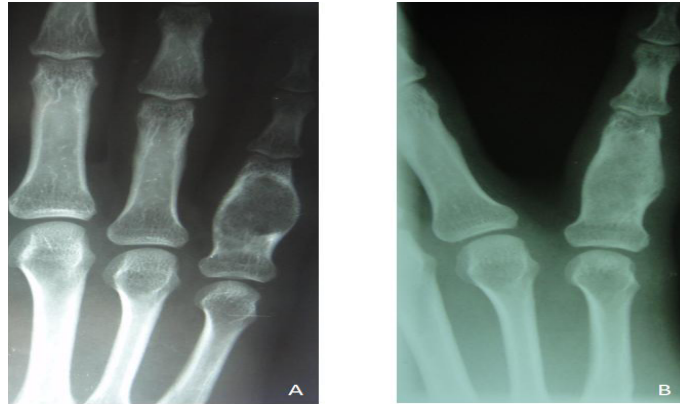

Fig. 1. Enchondroma of proximal phalanx of fifth finger. (A) Radiographic appearance of tumor (B) 8 months after curettage and bone grafting.

fourth to sixth decades, has high histologic grade, apparent cortical destruction, and soft tissue extension [1,2,7-9]. It's proved that chondrosarcoma of the hand is a locally aggressive lesion which in contrast to other anatomic sites, rarely metastasizes, and excellent local control may achieved after recurrence by reoperation [1,7,8,10]. Recently there is a tendency toward more conservative intralesional procedures including curettage (similar to enchondroma) for the treatment of chondrosarcomas [7].

By considering these, the necessity of incisional biopsy before definitive treatment of enchondromas is questionable, but there is no published data about this. Therefore we studied this objective in our patients for further information and reasonable data.

Methods

Fifty-two patients with solitary enchondroma of hand were operated at our hospital between 1998 and 2010. The case notes, radiographs, and histology of all patients were reviewed. The diagnosis of all cases were initially based on characteristic radiographic features (Fig.1-A) including well defined central lytic lesion with symmetrical cortical expansion, lobulation and occasionally calcification [1,3,4], supported by intraoperative findings and gross appearance of white to blue lobulated cartilaginous lesion [4], and finally confirmed histologically by permanent section analysis (Fig.2). All patients underwent curettage and

autogenous iliac bone grafting primarily as definitive treatment (Fig.1-B) without intraoperative frozen section, and histologic examination was done after operation. Clinical data were collected for all cases with great details. Special attention paid to pre – op radiologic and post –op histologic diagnosis.

We used SPSS version 15.0 (SPSS Inc. Chicago, IL) for statistical analysis. Mean [standard deviation (SD)] and frequency percentages were used for quantitative and qualitative variables, respectively.

Results

The patients included 28 women and 24 men, with the age range of 12 to 48 years (mean, 28.7 years, SD=7.6), 86 percent of them were in the second to fourth decades of life. Enchondromas presented as localized swelling in 27 (52%), pathologic fracture in 23 (44%), and were diagnosed incidentally in plain X- rays in 2 (4%) of our patients. Among these, 27 lesions (52%) occurred in proximal phalanges, 11 (21%) in metacarpals, 10 (19%) in middle phalanges, and 4(8%) in distal phalanges.

Noteworthy, in all patients the primary diagnosis of enchondroma according to radiographic appearance, was matched with intraoperative findings and gross appearance of tumor, and finally confirmed by histologic examination in all of them.

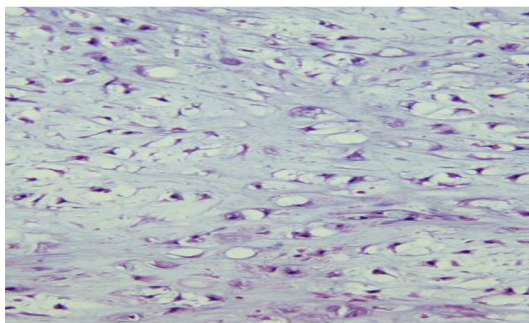


Fig. 2. Histologic appearance of tumor depicted in figure 1.

Discussion

Enchondroma usually occurs between the second and fourth decades of life [1,2,11,12]. This reemphasized in our study, but our patients were younger than depicted in the literature (the mean age of 28.7 years at the present study in comparison to 35.4 years in Takigawa's series [11]). According to Takigawa [11] and Noble et al [12] enchondroma is most common in males. Athanasian [3] and Greenspan et al [5] believe that there is no sex predilection. Unni [2] demonstrated a slight female predominance, similar to our study.

The distribution of tumors in decreasing of frequency between proximal phalanx, metacarpals, middle phalanx, and distal phalanx in the present study, is similar to many other reports including Takigawa [11], Noble et al [12] and O'Connor et al [1]. The presentation of our patients as localized swelling (52%), pathologic fracture (44%), and incidental finding (4%) were similar as described in the literature [1,3,5].

It is mentioned that the vast majority of enchondromas can be diagnosed by characteristic plain X – ray findings that previously described, and cortical destruction and soft tissue invasion seen in chondrosarcoma, are good differentiating factors [2,3,5,7,8]. Based on the results of this study, all of the primary radiologic diagnoses were correct, and there was no mismatch with histologic diagnosis.

Incisional biopsy, in the shape of frozen section or permanent section analysis, recommended as the first step of surgical treatment of enchondroma in the literature [1,3,

6]. In contrast, Unni [2] believes that if the radiographic findings are in favor of enchondroma biopsy is not necessary, but no documentation was presented. Our results strongly suggested that there is no need for biopsy in this setting.

If we consider the difficulty in differentiating benign and malignant cartilage tumors of hand at the microscopic level [1,7,8], intraoperative frozen section analysis as recommended by O'Connor et al [1] will be a time consuming , and in the vast majority of cases non- responding method. Apparently postponing the definitive treatment for permanent section analysis [1] was unnecessary in almost all situations.

In brief, by considering the fact that almost all cartilaginous tumors of hand are usually thought benign [4,10], and reemphasis on high possibility of correct diagnosis according to precise clinical, radiologic and intraoperative assessment, difficult pathologic differentiation [1,7,8], the similarity in treatment plan [7], little fear of spreading and distant metastasis and the chance of good local control by re- operation in case of hand chondrosarcoma in the rare situations of possible mistake diagnosis [7,8,10]; It is revealed that incisional biopsy is not necessary in the course of diagnosis and treatment of enchondroma.

Conclusion

Our results indicated that correct diagnosis of enchondroma is almost always possible by precise clinical and radiographic assessment and there is no need for histologic confirmation before definitive treatment.

References

1. O' Connor MI, Bancroft LW. Benign and malignant cartilage tumors of the hand. *Hand Clinics* 2004; 20: 317-323.
2. Unni KK. Dahlin's bone tumors: general aspects and data on 11,087 cases. 5th ed .Philadelphia: Lippincott – Raven; 1996.
3. Athanasian EA." Bone and soft tissue tumors" in: Green's operative hand surgery. Sixth ed. Philadelphia: Elsevier- Churchill Livingstone; 2011 .pp.

2141-2196.

4. Unni KK, Inward CY. "Tumors of the osteoarticular system" in Diagnostic histopathology of tumors. Third ed. Philadelphia: Churchill Livingstone – Elsevier; 2007. pp.1602-1612.

5. Greenspan A, Jundt G, Remangen W. Differential diagnosis in orthopaedic oncology .Second edition. Philadelphia: Lippincott Williams & Wilkins; 2007.pp.158-256.

6. Mirra JM. "Intramedullary cartilage and chondroid producing tumors " In: Bone tumors. Philadelphia: Lee & Febiger; 1989.pp.439-535.

7. Bovee JVMG, van der Huel RO, Taminiau AHM, Hogendoorn PCW. Chondrosarcoma of the phalanx: A locally aggressive lesion with minimal metastatic potential. A report of 35 cases and a review of the literature. Cancer 1999; 86:1724-1732.

8. Patil S, De Silva MV, Crossan J, Reid R. Chondrosarcoma of small bones of the hand. Hand Surg (Br) 2003; 28(6):602-608.

9. Cawte TG, Steiner GC, Beltran J, Dorfman HD. Chondrosarcoma of the short tubular bones of the hands and feet. Skeletal Radiol 1998; 27(11):625-632.

10. Robert PH, Price CH. Chondrosarcoma of the bones of the hand. J Bone Joint Surg (Br) 1977; 59(2) 213-221.

11. Takigawa K. Chondroma of the bones of the hand: A review of 110 cases .J Bone Joint surg 1971; 53(A):1591-1600.

12. Noble J, Lamb DW. Enchondromata of bones of the hand. A review of 40 cases. Hand 1974; 6:275-284.