



## Spontaneous coiling of the distal tip of the chemotherapy port

Morteza Khavnin Zadeh<sup>1\*</sup>, Amirhossein Dehghani Esfahani<sup>2</sup>, Alireza Azadeh<sup>2</sup>

Received: 22 Jan 2018

Published: 4 Aug 2018

### Abstract

For doing systemic chemotherapy, central venous ports are used to access central veins and internal jugular vein. Installing these devices though can be with complications on the side which cause them function limits. In this text a case is presented in which after installing a complete and intact port, some malfunction was detected in the chemotherapy procedure after several months which leads us to port Malposition which is probably caused by the huge soft tissue of patient's breast. This can be prevented simply by installing the port primarily in the zone with less soft tissue.

**Keywords:** Central Venous Catheter Chemotherapy Port, Coiling of the Distal Tip

Copyright© Iran University of Medical Sciences

**Cite this article as:** Khavnin Zadeh M, Dehghani Esfahani A, Azadeh A. Spontaneous coiling of the distal tip of the chemotherapy port. *Med J Islam Repub Iran.* 2018(4 Aug);32:66. <https://doi.org/10.18869/mjiri.32.66>

### Introduction

Central venous ports (CVPs) are vascular access devices facilitating central venous access for administration of fluid supplements or systemic chemotherapy (1). CVPs can be implanted into the anterior chest. In the past, surgeons inserted CVPs into the subclavian vein and reported complications such as pneumothorax, hemothorax, pneumohemothorax, thrombosis, and pinch-off syndrome (2). Nowadays, the internal jugular vein is considered a safer place for CVPs insertion (3), but sometimes complications such as dislocation of the end of the CVPs occur, causing failure in the process of treatment (4, 5). We present a case of rare complication after insertion of chest CVP through the internal jugular vein, where some malposition occurred at the distal part of the device, resulting in dysfunction of the device and preventing the treatment to be completed.

### Case report

A chemotherapy port was placed for a 44-year-old female under local anesthesia through right internal jugular vein, with the guidance of sonography by passing a guide wire, while performing fluoroscopy. The edge of the catheter was placed in the cavoatrial junction. Everything looked normal and the postoperative CXR showed the tip of the catheter being dwelled in the cavoatrial junction (Fig. 1). A few months later, the patient returned to the hospital due to the dysfunction of the port, and the CXR

showed that the tip of the catheter was curled upwards (Fig. 2). Under local anesthesia and through the guidance of the fluoroscopy, the port was moved towards its normal place, resulting in straightening its tip and creating a direct route. In the next follow-ups, the patient had no complications and received her routine chemotherapy.

### Discussion

One possible explanation for this phenomenon could be

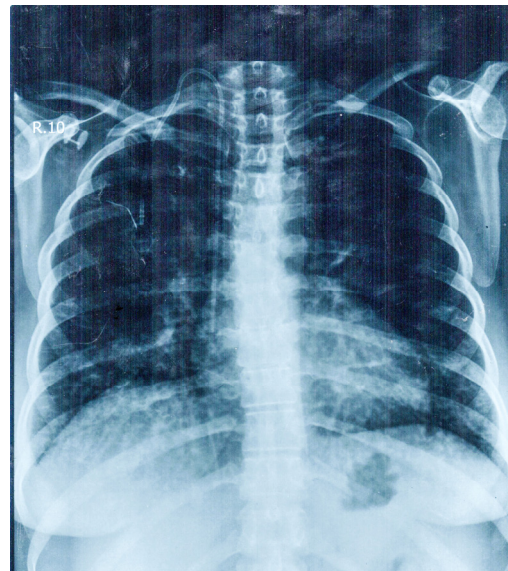


Fig. 1. The tip of the catheter being dwelled in the cavoatrial junction

**Corresponding author:** Dr Morteza Khavnin Zadeh, [khavaninzadeh.m@iums.ac.ir](mailto:khavaninzadeh.m@iums.ac.ir)

<sup>1</sup> Vascular Access Surgeon, Iran University of Medical Sciences, Hasheminejad Kidney Center, Tehran, Iran.

<sup>2</sup> Iran University of Medical Sciences, Tehran, Iran.

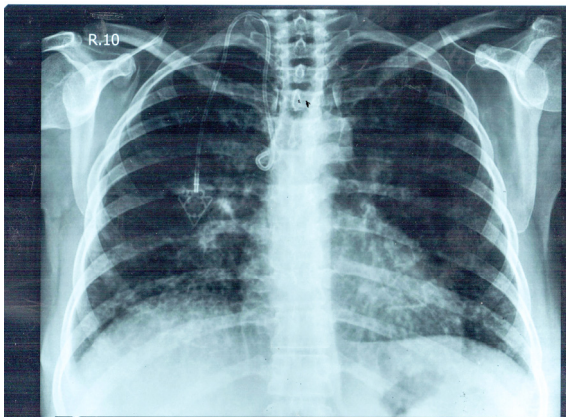


Fig. 2. The tip of the catheter has been curled upwards

that the repeated to/fro movement of the catheter, due to shifting heavy breast motion, has led to gradual coiling up of its tip and doubling over itself; we assume that shifting the entry site to a lateral or medial location, which is less dependent on the breast mass, can help prevent such a consequence.

#### Conflict of Interests

The authors declare that they have no competing interests.

#### References

1. Mori Y, Nagayama S, Kawamura JI, Hasegawa S, Tanaka E, Okabe H, Takeuchi M, Sonobe M, Matsumoto S, Kanai M, Muto M. A retrospective analysis on the utility and complications of upper arm ports in 433 cases at a single institute. *Intl J Clin Oncol*. 2016 Jun 1;21(3):474-82.
2. Sakamoto N, Arai Y, Takeuchi Y, Takahashi M, Tsurusaki M, Sugimura K. Ultrasound-guided radiological placement of central venous port via the subclavian vein: a retrospective analysis of 500 cases at a single institute. *Cardiovascul Interven Radiol*. 2010 Oct 1;33(5):989-94.
3. Teichgräber UK, Kausche S, Nagel SN, Gebauer B. Outcome analysis in 3,160 implantations of radiologically guided placements of totally implantable central venous port systems. *Eur Radiol*. 2011 Jun 1;21(6):1224-32.
4. Wiegering V, Schmid S, Andres O, Wirth C, Wiegering A, Meyer T, Winkler B, Schlegel PG, Eyrieh M. Thrombosis as a complication of central venous access in pediatric patients with malignancies: a 5-year single-center experience. *BMC Hematology*. 2014 Dec;14(1):18.
5. Surov A, Bach AG, Schramm D. Clinically relevant cardiovascular findings detected on staging computed tomography in patients with several malignancies. *Angiology*. 2016 Aug;67(7):630-7.