

Intraforaminal and extraforaminal far lateral lumbar disc herniation (a review of 63 cases)

Fariborz Samini, MD.¹, Gholamreza Bahadorkhan, MD.², Mohammad Reza Ehsaei, MD.³
Hamed Kheradmand, MD.⁴

Department of Neurosurgery, Mashhad Medical University, Mashhad, Iran.

Abstract

Background: Far lateral discal herniation is an uncommon disorder and is difficult to assess by physical examination alone. This study is designed to define clinical and epidemiological findings and to establish the indications of surgical and medical treatment for FLLDH.

Methods: Between 2000 and 2005, a total of 2035 patients with lumbar disc herniation underwent surgical discectomy by the authors in several neurosurgical centers in Mashhad. Among these patients, 63 (3.1%) had FLLDH (42 men and 21 women). Clinically these patients had unilateral radicular pain with or without paresis. SLR was positive in 100% of cases. Conservative therapy consisting of bed rest, nonsteroidal anti-inflammatory drugs and physiotherapy had failed. We used a combination of classical interlaminar approach and the intertransverse route through a midline approach for the treatment of our patients.

Results: From 63 cases in our series, 42 were men and 21 were women. 19 patients had extraforaminal and 44 had foraminal disc herniation. The most common level for far lateral discal herniation was L4-L5. Our patients had LBP in 43.6% (27 cases) and positive SLR and radicular leg pain in 100% (63 cases). In all patients leg pain was relieved immediately after surgery.

Conclusion: FLLDH should be considered in all cases with lower limb radiculopathy. These patients have more severe radicular pain than patients with paracentral lumbar disc herniation. FLLDH happens more frequently at L4-L5 and L3-L4 levels. It can often be difficult to diagnose or easily overlooked on radiographic studies. In almost all cases, conservative treatment is unsuccessful and surgical treatment is recommended.

Keywords: far lateral disc, lumbar spine, foraminal and extraforaminal, disc surgery.

Introduction

Lumbar disc herniation is one of the most common medical and surgical problems all over the world. The vast majority of lumbosacral radiculopathies are caused by para-

central herniation. However, Hood reported that far lateral lumbar disc herniation (FLLDH) accounts for 2.8 – 10% of all disc herniations.

Over 75% of FLLDHs occur at the L3–L4 and L4–L5 levels. In addition, FLLDH presents a clinical challenge, since it can be diffi-

1. **Corresponding author**, Associate Professor of Neurosurgery, Department of Neurosurgery, Ghaem Medical Center, P.O. Box 155, Mashhad, Iran. Tel: +98 915 111 1343, Fax: +98 511 8012613, email: SAMINIF@MUMS.ac.ir

2-4. Associate Professor of Neurosurgery, Mashhad Medical University, Mashhad, Iran.

cult to diagnose or easily overlooked on radiographic studies. A far lateral compression of a nerve root presents similar to when the corresponding nerve root is compressed inside the vertebral canal by a posterolateral protrusion of the disc above [1,2].

MRI is the diagnostic modality of choice except in a setting of severe arthrosis. In this situation CT-Myelography may be the best [3]. Indications for lumbar surgery include instability, foraminal stenosis and discal herniation [4].

Methods

Between September 2000 and September 2005, a total of 2035 cases with lumbar discal herniation underwent discectomy by the authors in Mashhad neurosurgical departments. Among these patients, 63 (3.1%) had FLLDH, including 21 women and 42 men, ranging in age from 31 to 62 years old (mean 47 years).

They often had an acute onset in their clinical courses. Frequently there was no precipitating event that corresponded to the onset of symptoms. Clinically almost all patients had unilateral radicular pain. Low back pain was present in 27 patients who had limited movement and antalgic scoliosis of the lumbar region. Straight leg raising was positive in 63 cases and femoral stretch test was positive in 19 cases.

Foraminal stenosis with enlarged facet joints and spondylotic degeneration was noted in 5 patients with foraminal disc herniation.

Most patients presented with back pain as the first symptom, followed by radicular pain, weakness and sensory loss. The low back pain generally subsided, and it was usually the radicular symptoms that brought the patients to the physician.

The patients often described that the pain was worse upon exertion. They had severe radicular pain.

Radiologic investigations including plain

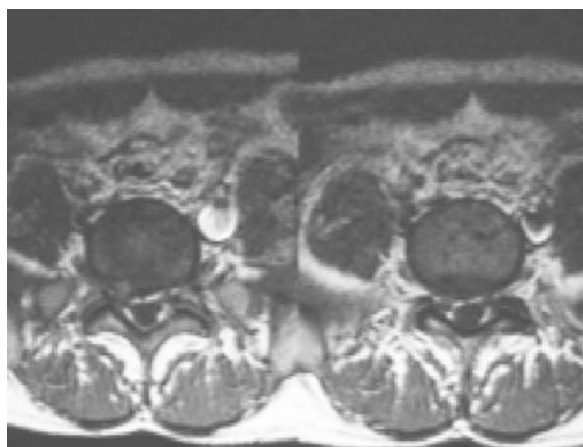


Fig. 1. Intraforaminal far lateral disc herniation in one of our patients.

radiography, CT scanning with or without myelography and /or MRI of the lumbar spine showed the presence of FLLDH (Fig. 1, 2).

Conservative therapy consisting of bed rest, nonsteroidal anti-inflammatory drugs and physiotherapy had failed for all patients.

Surgery was performed from 3 weeks to six months after the onset of symptoms. We used a combination of classical interlaminar approach and the intertransverse route through a midline approach for the treatment of our patients.

None of our patients needed pedicular screw fixation and fusion with posterolateral bone grafting.

Follow up ranged from 3 months to 5 years (mean 3.6 years).

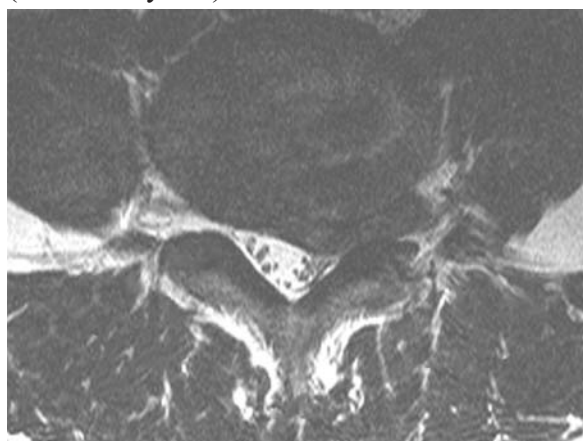


Fig. 2. Extraforaminal far lateral disc herniation in another patient.

Femoral stretch test	Radicular pain	SLR+	LBP	Female	Male	Number of patients
19 (29.8%)	63 (100%)	63 (100%)	27 (43.6%)	21 (33.5%)	42 (66.5%)	63

Table 1. Clinical findings in our patients with far lateral lumbar disc herniation.

We took flexion-extension radiography from our patients in follow up periods. Nobody acquired vertebral instability at the operated level (sagittal translation of 4 mm or more, or angular movement of 10 or more).

We used chi-squared test for statistical analysis.

Results

42 (66.5%) of 63 patients in our series were men and 21 (33.5%) were women ranging in age from 31 to 63 years old (mean 47 years).

Low back pain was present in 27 (43.6%) patients & radicular pain and SLR were both positive in 63 cases (100%).

Femoral stretch test was positive in 19 patients (29.8%) (Table 1).

Among cases operated for FLLDH, 19 (31%) had extraforaminal disc herniation and 44 (69%) had foraminal disc herniation. The mean age of the two groups were 39 and 51 years, respectively.

Herniation levels were at L3-L4 in 19 patients, L4-L5 in 26 and L5-S1 in 15 cases. L2-L3 was involved in 3 cases (Table 2).

All of our patients (63 cases) immediately noted relief of leg pain and had no complaints after surgery. There was improvement in muscle weakness in 58 cases. 5 patients had severe paresis before operation. They became better after surgery but still there was residual paresis.

There was no statistically significant difference among the results encountered in our

two surgical groups (foraminal & extraforaminal) ($P < 0.01$).

None of these cases showed hypermobility in flexion-extension radiographs after operation.

Discussion

Each nerve root exits through its corresponding neural foramen. The exiting nerve root enters the neural foramen just below the corresponding pedicle. The dorsal root ganglion lies in the neural foramen or just distal to the neural foramen. Far lateral lumbar disc herniation causes impingement directly on the dorsal root ganglion. Due to the compression on the ganglion, which contains the cell bodies for the sensory nerves for the appropriate dermatome, FLLDH can cause significantly more radicular pain than paracentral disc herniation. Owing to the small size of the neural foramen, small FLLDH can cause more severe symptoms than similarly sized paracentral disc herniation. Generally, FLLDH involves higher lumbar segments compared to other herniated lumbar discs [4,5].

The L4-L5 level is most commonly involved, followed in descending order by L3-L4 and L5-S1 and least by L2-L3. The average age of patients with FLLDH is generally higher than those with central or paracentral herniation [7,8].

In FLLDH, both the ganglion and the nerve root are compressed. Signs of neural entrapment are often accompanied by significant

L2-L3	L3-L4	L4-L5	L5-S1	Foraminal herniation	Extraforaminal herniation	Number of patients
3 (4.8%)	19 (30.2%)	26 (41.2%)	15 (23.8%)	44 (69%)	19 (31%)	63

Table 2. Levels of involvement in lumbar intervertebral discs in our patients with far lateral lumbar disc herniation.

motor or sensory deficits clearly defining the nerve root involved. Low back pain is a less common finding and may be absent especially with an intraforaminal disc herniation [8].

In our series the incidence of FLLDH was 3.1% of all operated lumbar disc herniations. In other reports the incidence varied from 1% to 13% [9,10].

Diagnosis of FLLDH based on physical examination alone is difficult because FLLDH compressing the nerve root has the same sign as if the corresponding nerve root had been compressed inside the vertebral canal by a posterolateral protrusion of the disc above [11,12].

The most sensitive imaging techniques for diagnosing lumbar disc herniation are MRI and CT myelography. However, for FLLDH, MRI is superior. Since the compression is lateral to the nerve root sleeve, which is distal to the most lateral extent of contrast penetration, the FLLDH may be missed with CT myelography. Godersky and his colleagues described 12 cases of FLLDH that were diagnosed with CT. In nine of these cases, myelography was performed, and results were normal in six instances. MRI may reveal the presence of disc material obliterating the neural foramen. Therefore it is imperative that the parasagittal views are taken far enough laterally to include the neural foramina. The axial view of MRI was useful for the diagnosis of FLLDH. Neither lumbar epidural block nor the root block were effective for pain reduction [13,14].

As with other nontraumatic lumbar disease, the physician should attempt conservative therapy prior to surgical intervention. A trial of conservative therapy should include non-steroidal anti-inflammatory medications, muscle relaxant and physical therapy. In addition, brief treatments with corticosteroids may also reduce the inflammatory reaction that accompanies acute disc herniations [15].

Once the decision to use surgical intervention for treatment has been made, in foraminal lumbar disc herniation, the hemilaminecto-

my with medial facetectomy is recommended, while in extraforaminal lumbar disc herniation, either facetectomy with pedicular screw fixation and fusion with posterolateral bone grafting or the transmuscular approach for removal of the nucleus pulposus can be chosen [16].

We used a combination of the classical interlaminar approach and the intertransverse route through a midline approach for the treatment of our patients. This combined midline approach permits complete evacuation of the involved disc and additional bone resection procedures [17]. None of our patients needed pedicular screw fixation and fusion with posterolateral bone grafting.

After surgical intervention, patients usually have immediate relief from their preoperative symptoms.

For healthy patients with minimal morbidities, the hospital stay is usually not more than 1 or 2 days.

Physical therapy can be a useful adjunct, but it is usually not necessary as long as the patient can walk without difficulty [12,17].

Conclusion

In cases with lower limb radiculopathy, FLLDH should be considered in the differential diagnosis. These patients have more severe pain than similar patients with a paracentral lumbar disc herniation. FLLDH happens more frequently at L4-L5 & L3-L4 levels. Occasionally the diagnosis of FLLDH is a problem by clinical findings and even imaging. Conservative therapy should be considered in patients with FLLDH, although it is often unsuccessful. This is due to the increased pain symptoms that accompany FLLDH with compression of the dorsal root ganglion. Although several surgical techniques may be used for FLLDH, we prefer the pars resection, as this technique is less prone to destabilization of the spine. The results of operation are excellent.

Acknowledgement

We would like to express our appreciation to the Research Vice-chancellor of the Mashhad University of Medical Sciences for supporting this research.

References

1. Epstein NE, Epstein JA, Carras R, Hyman RA: Far lateral lumbar disc herniations and associated structural abnormalities. An evaluation in 60 patients of the comparative value of CT, MRI, and Myelo-CT in diagnosis and management. *Spine* 1990; 15:534-542.
2. Gioia G, Mandelli D, Capaccioni B, et al. Surgical treatment of far lateral lumbar disc herniation: identification of compressed root and discectomy by lateral approach. *Spine* 1999;18:1952-7.
3. Grenier N, Greselle JF, Douws C, et al : MR imaging of foraminal and extraforaminal lumbar disc herniations. *J Comput Assist Tomogr* 1990; 14:243-249.
4. Hodge SD, Humphreys S, Craig MD, Eck JC, Covington MS, Laurie A. The surgical treatment of far lateral L3-L4 and L4-L5 disc herniation: A modified technique and outcome analysis of 25 patients. *Spine* 1999; 24 (12): 1243 – 1247.
5. Jenis LG, An HS, Gordin R. Foraminal stenosis of the lumbar spine: a review of 65 surgical cases. *Am J Orthop* 2001; 205-11.
6. Siebner HR, Faulhauer K: Frequency and specific surgical management of far lateral lumbar disc herniation. *Acta Neurochir (Wien)* 1990; 105:124-131.
7. Epimenio RO, Giancarlo D, Giuseppe T, et al. Extraforaminal lumbar herniation: 'far lateral' microscopic approach retrospective study. *J Spinal Disord Tech* 2003;16:534-9.
8. Abdullah AF, Wolber PGH, Warfield JR , et al. Surgical management of extreme lateral lumbar disc herniations: a review of 138 cases. *Neurosurgery*1988; 22: 648-655.
9. Jackson RP, Glah JJ. Foraminal and extraforaminal lumbar disc herniation, diagnosis and treatment. *Spine* 1987; 12: 577-584 .
10. Darden BV, Wade JF, Alexander R, et al. Far lateral disc herniations treated by microscopic fragment excision: techniques and results. *Spine* 1995; 20:1500-5.
11. Perno JR ,Rossitch EJ;Extreme lateral lumbar disc herniation. Diagnosis and management. *NC Med J* 1993; 54: 224 -226.
12. Viswanathan R, Swamy NK, Tobler WD, et al.Extraforaminal lumbar disc herniation: microsurgical anatomy and surgical approach. *J Neurosurgery Spine*

2002 ;96: 206-211.

13. Pfirrmann CW, Metzdorf A, Zanetti M, et al. Magnetic resonance classification of lumbar intervertebral disc degeneration. *Spine* 2001; 26:1873-8 .

14. Fukushige T, Yamada S, Sano T, Kano T, Kawasaki Y. Five cases of far lateral lumbar disc herniation treated conservatively. *The Pain Clinic J* 2005; 17: 213-219.

15. Tessitore E, Tribolet N. Far lateral lumbar disc herniation: the microsurgical transmuscular approach. *Neurosurgery* 2004; 54 (4): 939-942.

16. Yi XS, Zu GZ, Mao HC, Qi RD, Xiao ZZ. Diagnosis and operative treatment of far lateral lumbar disc herniation: English transl. of *Zhonghua Wai Ke Za*. 2006; 44: 559 – 61.

17. Mehmet FO, Turgay B, Seref B, Mustafa E. Combined approach for far lateral lumbar disc herniation. *Neurologia Medico Chirurgica* 2004; 44: 118 – 123.