

Midterm results after surgical correction of total anomalous pulmonary venous connection

Maziar Gholampour-Dehaki, MD.¹, Alireza Alizadeh Ghavidel, MD.², Nader Givtaj, MD.³

Department of Cardiovascular Surgery, Rajaee Heart Center, Tehran, Iran.

Abstract

Objective: To evaluate the surgical treatment of total anomalous pulmonary venous connection (TAPVC) and determination of predictors for postoperative death.

Methods: Between 1995 and 2005, 80 patients aged from 1 month to 12 years underwent surgical repair for supracardiac (39), cardiac (34), infracardiac (3) or mixed (4) type of TAPVC. Systemic pulmonary hypertension (PH) in 53.8% of patients, half systemic PH in 26.3% and mild PH (<40 mmHg) were found by preoperative evaluations. Twelve patients (15%) had some degree of pulmonary vein obstruction preoperatively.

Results: Seven patients (8.7%) died in the operating room. Early postoperative mortality (during 48 hours) occurred in 11 cases (13.7%) and nine patients died during first hospitalization. We did not have late mortality in survivors during follow-up period; therefore the overall mortality rate was 33.8%. The incidence of postoperative death was highest in the infracardiac type (2/3). Approximately two-thirds of dead patients (21/27) had presented with systemic PH and 89% of them had at least half-systemic PH preoperatively. Mortality rate in patients with normal pulmonary artery pressure (PAP) was zero.

Conclusion: In contrast to early surgical results we had excellent mid-term outcome.

The role of myocardial protection and surgical technique are the most probable causes of high death rate in our series. However influences of poor preoperative stabilization process as well as anesthetic technique and cardiopulmonary bypass related problems should be considered. PAP more than half of systemic pressure and patient age smaller than 3 months were the primary predictive factors for premature death ($P < 0.05$).

Keywords: total anomalous pulmonary venous connection, pulmonary hypertension, mortality.

Introduction

Total anomalous pulmonary venous connection (TAPVC) accounts for only 1-3% of all congenital heart disease. In this cardiac anomaly all the pulmonary veins (PV) connect to the

right atrium or one of its tributaries and there is no direct connections between PV and the left atrium [1,3]. The first description of this anomaly was done by Wilson in 1798. TAPVC develops when the primordial PV fails to unite with the plexus of veins surrounding the lung buds [1]. This cardiac malformation is classified according to the site of PV connection. TAPVC is

1. **Corresponding author**, Cardiac Surgeon, Vali-Asr Ave., Next to Mellat Park, Rajaee Heart Center, Department of Cardiovascular Surgery, Tehran, Iran. Tel: +9821 2392 2169, Fax: +9821 2204 2037, email: drgholampour@yahoo.com.
2&3. Cardiac Surgeon, Rajaee Heart Center, Department of Cardiovascular Surgery, Tehran, Iran.

	No. (%)
No. and sex (Male/Female)	80, 48/32
Age (Mean)	21.5 +/-42 (1 to 240)
Type of malformation:	
Supracardiac	39 (48.7%)
Cardiac	34 (42.5%)
Infracardiac	3 (3.8%)
Mixed	4 (5%)
Symptoms:	
Tachypnea	79 (99%)
Cyanosis	72 (90%)
Associate anomalies:	
ASD or PFO*	80 (100%)
VSD**	3 (3.8%)
LSVC***	3 (3.8%)
PDA****	13 (16.3%)
TF#	None
Pre-op PAP## (mmHg)	61 +/-20 (15 to 110)
Pulmonary Hypertension:	
Systemic	43 (53.8%)
Half-systemic	21 (26.3%)
Mild	13 (16%)
Normal PAP	3 (3.9%)

*Atrial septal defect or patent foramen ovale. **Ventricular septal defect.

left superior vena cava. *Patent ductus arteriosus. #Tetralogy of Fallot.

##Pulmonary artery pressure.

Table 1. Preoperative characteristics of patients.

supracardiac in about 45% of cases, cardiac in about 25%, infracardiac in about 25% and mixed in about 5% [2,3]. Although not part of the malformation, a patent foramen ovale (PFO) or atrial septal defect (ASD) nearly always is present because for survival after birth, a communication between systemic and pulmonary circulation must exist [1,3]. Infants born with TAPVC have a generally unfavorable prognosis, with only about 20% surviving the first year of life. Surgical therapy is the main therapeutic option and should be undertaken immediately in any neonate or infant with TAPVC.

The aim of this descriptive study was to review the results of surgical management of TAPVC cases at our center as a major referral center for congenital heart disease in our country, in an attempt to expand the knowledge on

the malformation and identify risk factors for adverse outcome.

Methods

All patients who underwent surgical repair of TAPVC between March 1995 and April 2005 were identified from the surgical database. All preoperative, surgical and postoperative data were obtained from medical records. All survivors were followed up in cardiac surgery and congenital heart disease clinics with clinical examination and serial 2D echocardiographic assessment. The mean follow up period was 25 +/- 33 months, ranging from 1 to 144 months.

There were 80 patients, 48 male and 32 female with a mean age of 22 months (range 1 month to 12 years). Dyspnea (99%) and cyanosis (90%) were the most common clinical findings. According to the standard classifica-

Drainage sites	No. (%)
Innominate vein	10 (12.5%)
Right SVC*	26 (32.5%)
Left SVC	3 (3.8%)
Right atrium	4 (4.9%)
Coronary sinus	30 (37.5%)
Portal vein	3 (3.8%)
Azygos	None
Mixed	
Innominate vein & right SVC	2 (2.6%)
Right SVC & coronary sinus	1 (1.3%)
Right atrium & coronary sinus	1 (1.3%)

*SVC: Superior vena cava.

Table 2. Drainage sites of pulmonary veins.

tion, supracardiac (48.7%) and cardiac (42.5%) forms were the most common types of malformation. Four cases (5%) had mixed type and only three patients (3.8%) had the infracardiac form of anomaly.

There was an atrial communication in all patients, large PFO in 23% and ASD in 77%. The other associated cardiac anomalies included patent ductus arteriosus (PDA) in 16.3%, ventricular septal defect (VSD) in 3.8% and left superior vena cava (LSVC) in 3.8%. No case of tetralogy of Fallot (TF) was found in our series. Twelve patients (15%) had some degree of pulmonary vein obstruction preoperatively. Mean pulmonary artery pressure (PAP) was 61±20 mmHg (ranging from 15 to 110 mmHg). Systemic pulmonary hypertension (PH) in 53.8% of patients, half systemic PH in 26.3% and mild PH (<40 mmHg) were found by preoperative evaluations. Only three infants had normal pulmonary artery pressure before surgical treatment. Patients' clinical characteristics are summarized in Table 1. According to the echocardiographic and angiographic studies coronary sinus and SVC were the most common sites of vertical vein's drainage. In 3 infants with infracardiac type of malformation, the portal vein was the drainage site of the pulmonary veins (Table 2).

Surgical technique

All patients were scheduled for an urgent or as soon as possible operation. Ten critically ill infants (12.5%) were operated urgently according to the transthoracic echocardiographic evaluation, but cardiac catheterization and angiographic study were performed for the remainder of patients preoperatively.

All procedures were carried out under general anesthesia and through median sternotomy incision. Cardiopulmonary bypass (CPB) was established using ascending aortic and bicaval cannulation. PDA was dissected and ligated before CPB establishment or immediately after that. The operation was performed under moderate hypothermia and in a few neonates the cooling continued to 20 degree Celsius and circulatory arrest was induced. During the cooling process the posterior pericardium was cut and the common pulmonary venous sinus, vertical vein and its drainage course were identified. Cold crystalloid antegrade cardioplegia was used to induce cardiac arrest. In 45 patients (56.3%) surgical repair included side to side anastomosis of common pulmonary venous sinus to left atrium with interrupted 5-0 or 6-0 polypropylene sutures and ligation of vertical vein. In 32 patients (40%) coronary sinus was unroofed so that it communicated freely with the left atrium and the fossa ovalis, then the re-

sulting large defect was closed with an untreated autologous pericardial patch. Surgical management of the remaining three cases with mixed or infracardiac form of anomaly were individualized based on morphologic aspects of the malformation. The remainder of the operation was completed in the usual manner, including the re-warming and de-airing process.

Results

Seven patients (8.7%) could not wean off from CPB and died in the operating room due to low output syndrome. Early postoperative mortality (during 48 hours) occurred in 11 cases (13.7%) and nine patients died during first hospitalization. We did not have late mortality in survivors during the follow-up period; therefore the overall mortality rate was 33.8% (27/80). Heart failure and low cardiac output syndrome was the most common cause of death (25/27). Pneumonia was the leading cause of death in a 15 day neonate, and a 3 year old baby with systemic pulmonary hypertension expired as a result of respiratory failure. According to the types of malformation, the incidence of postoperative death was 66.7% in infracardiac type (2/3), 38.5% in cardiac type (13/34), 28% in supracardiac type (11/39) and 25% in mixed type (1/4). Approximately two-thirds of dead patients (21/27) had presented with systemic PH and 89% of them had at least half-systemic PH preoperatively. Mortality rate in patients with normal PAP was zero. Mortality rate was highest in the neonate group (75%). This rate

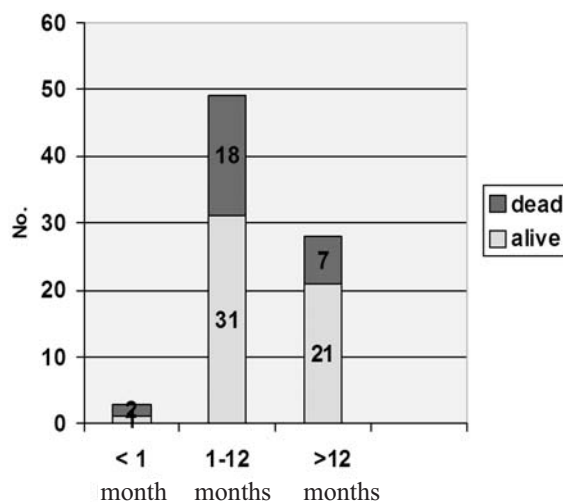


Fig. 1. Mortality incidence between age groups.

was 36.7% (18/49) in infants with age from 1 to 12 months and 25% (7/30) in patients older than 12 months (Fig. 1).

We evaluated predictive factors for in-hospital mortality and found that all dead patients had some degree of pulmonary hypertension. Multivariable analysis showed that PAP more than half of systemic pressure was an independent risk factor for postoperative mortality in our series (P=0.02). Patient age less than 3 months was the other predictive factor for premature death (P=0.02). Table 3 shows the results of risk analysis.

Postoperative pulmonary vein obstruction occurred in a 2 months old infant who died before re-operation due to acute heart failure. The obstruction developed at the anastomosis site between the common pulmonary vein sinus and

	No. (%)	P value
Age < 3 month	13 (48%)	P=0.02
Preoperative high PAP	24 (89%)	P=0.02
Restricted ASD	16 (59%)	P=0.04
Small LV size	10 (37%)	P=0.04
Preoperative PV obstruction	7 (26%)	P=0.05
Presence of other anomaly	12 (44%)	P=0.06
Infracardiac type of anomaly	2 (7.6%)	P=0.04

Table 3. Predictive risk factors for in-hospital death.

left atrium that created a 23 mmHg peak pressure gradient. The most common postoperative complication was respiratory tract problems including long-term need for mechanical ventilatory support (more than 48 hours) in 12 patients (15%), pneumonia in 5 cases (6.2%) and segmental or lobar atelectasis in 5 patients (6.2%). was 2.5%. One of them was a 3 months old patient who was re-explored for mediastinal bleeding and the second one was a 13 year old girl with postoperative tamponade who underwent subxiphoid drainage a few days after the first procedure. No significant correlation was seen between postoperative complications and morphologic types of malformation or surgical techniques.

Discussion

Total anomalous pulmonary vein connection (TAPVC) is relatively uncommon and accounts for only 1-3% of all congenital heart disease [3,5]. The morphologic variations of TAPVC reflects a wide difference of physiology and clinical presentation, ranging from right to left shunting with mild cyanosis to pulmonary edema and respiratory distress[5,6]. Patients born with TAPVC generally have an unfavorable natural history.

Nearly 50% of these patients die during the first 3 months of life and also survivors beyond the first critical few months have no favorable prognosis, because only approximately 50% of them survive to one year [3].

Results of surgical repair have markedly improved in recent years because of better preoperative, intraoperative and postoperative managements. This improvement is probably due to early diagnosis with high quality echocardiographic studies, progresses in preoperative preparation and stabilization of critically ill infants, improvements in anesthetic strategies and surgical techniques. Good myocardial protection, creation of a large and tension-free anastomosis avoiding any torsion or rotation of the PV common sinus [3,5,6].

Operative mortality rate has been reported from 2% to 20% in recent years [1,3,4,5,7]. Overall mortality was 33.8% in our series that is markedly higher than most reports, except the report of Korbmacher and his colleagues that presented the long term results of TAPVC repair of 52 patients in 2001. Early mortality rate in their study was 34.6% [6]. In our study more than half of mortalities occurred in the operating room, therefore the role of myocardial protection and surgical technique are the most probable causes of high death rate. However influences of poor preoperative stabilization process as well as anesthetic technique and cardiopulmonary bypass related problems should be considered.

Preoperative and postoperative PV stenosis have been defined as powerful predictors of adverse outcomes and the incidence of re-operation for PV obstruction has been reported from 9 to 11% [5]. On the other hand we had only one patient with documented post-operative PV stenosis and we had no re-intervention due to PV obstruction. Nevertheless it seems that we had some neglected cases of postoperative PV stenosis among the dead patients because of non-optimal postoperative echocardiographic assessments.

In contrast to in-hospital mortality the rate of late death was zero and our mid-term results were excellent. It can show that the peri-operative problems were the most important predictors of poor surgical outcome and better management of this stage leads to better results.

Although risk factors like PV obstruction on presentation and infracardiac type did not correlate with early mortality in Michielon's report [5], these factors in addition to small LA size, preoperative PH and age <3 months had significant correlation with in-hospital death.

In our study respiratory tract problems were the most common postoperative complications, meanwhile more than 95% of patients had some degrees of PH; thus improvement of postoperative respiratory care including control of pul-

monary hypertension crisis and reducing PAP may lead to better results.

Results of TAPVC repair in infancy have markedly improved in recent years, with an operative mortality of less than 10%. Therefore early surgical correction is currently recommended, even before the onset of clinical symptoms. But we have to improve preoperative, operative and postoperative management for achievement of good results.

Routine use of echocardiography as the gold-standard diagnostic tool, improvements in myocardial protection with specific attention to the right ventricle, creation of a large tension-free anastomosis, careful geometric alignment of the PV common sinus with the body of the left atrium avoiding torsion or rotation of PV, monitoring and prevention of PH crisis and delayed sternal closure have been considered as major factors in reducing operative mortality [5,7]. It seems that cardiopulmonary bypass related events and ineffective management of PH were the primary causes of high early mortality in our series.

Unfortunately, our study was a retrospective review of a limited number of patients treated over a long period of time. Thus the role of individual risk factors on outcome was difficult to assess.

In summary, our findings show that in contrast to early surgical results we had excellent mid-term outcome. In addition, early presentation (less than 3 months) and preoperative PH have the greatest adverse effect on patient outcome.

References

1. Hancock Friesen CL, Zurakowski D, Thiagarajan RR, Forbess JM, del Nido PJ, Mayer JE, et al. Total anomalous pulmonary venous connection: an analysis of current management strategies in a single institution. *Ann Thorac Surg* 2005; 79 (2): 595-606.
2. Ricci M, Elliott M, Cohen GA, Catalan G, Stark J, de Leval MR, et al. Management of pulmonary venous

obstruction after correction of TAPVC: risk factor for adverse outcome. *Eur J Cardiothorac Surg* 2003; 24:28-36.

3. Sinzobahamvya N, Arenz C, Brecher AM, Blaschczok HC, Urban AE, et al. Early and long-term results for correction of total anomalous pulmonary venous drainage (TAPVD) in neonates and infants. *Eur J Cardiothorac Surg* 1996; 10(6): 433-8.

4. Kirshbom PM, Myung RJ, Gaynor JW, Ittenbach RF, Paridon SM, DeCampi WM, et al. Preoperative pulmonary venous obstruction affects long-term outcome for survivors of total anomalous pulmonary venous connection repair. *Ann Thorac Surg* 2002; 74(5):1616-20.

5. Michielon G, Di Donato RM, Pasquini L, Giannico S, Brancaccio G, Mazzera E, et al. Total anomalous pulmonary venous connection: Long-term appraisal with evolving technical solution. *Eur J Cardiothorac Surg* 2002; 22:184-191.

6. Korbmacher B, Büttgen S, Schulte HD, Hoffmann M, Krogmann ON, Rammos S, et al. Long-term results after total anomalous pulmonary venous connection. *Thorac Cardiovasc Surg* 2001; 49(2):101-6.

7. Kanter KR. Surgical repair of total anomalous venous connection. *Semin Thorac Cardiovasc Surg Pediatr Card Surg Annu* 2006:40-4.

8. Wilson WR, et al. Technical modifications for improved results in total anomalous pulmonary venous drainage. *J Thorac Cardiovasc Surg* 1992; 103(5):870-1.

9. Aeba R, Katogi T, Takeuchi S, Kawada S, et al. Correction of total anomalous pulmonary venous connection of cardiac type. *Cardiovasc Surg* 1998; 6(1): 50-57.