

## Bicornuate-septate uterus: a new congenital uterine anomaly

Nasrin Moghadami-Tabrizi, MD.<sup>1</sup>, Maryam Mokhtari-Derakhshanfard, MD.<sup>2</sup>, Hormoz Dabir-Ashrafi, MD.<sup>3</sup>, Fahime Iravani, PhD.<sup>4</sup>, Shahram Shams, MD.<sup>5</sup>, Babak Dabir-Ashrafi, BS.<sup>6</sup>

*Department of Obstetrics and Gynecology, Tehran University of Medical Sciences, Tehran, Iran.*

### Abstract

Bicornuate uterus is class IV and septate uterus is class V in uterine anomaly classification. Bicornuate uterus is almost always treated by laparotomy and metroplasty. But the treatment of choice for septate uterus is hysteroscopic metroplasty. Bicornuate-septate uterus which is described in this paper is a new class of uterine anomaly (between class IV & V). The advantages of hysteroscopic metroplasty to laparotomy and metroplasty have been proven previously. It is important to know if the uterine anomaly is pure bicornuate or bicornuate-septate. In the latter case, we suggest the first line of operation should be hysteroscopic metroplasty.

**Keywords:** bicornuate-septate uterus, uterine anomaly, Mullerian anomalies, hysteroscopic metroplasty, laparotomy and metroplasty.

### Introduction

According to The American Fertility Society Classification of Mullerian anomalies, bicornuate uterus is class IV and septate uterus is class V [1]. The treatment of choice for septate uterus is hysteroscopic metroplasty [2,3] but bicornuate uterus is almost always treated by laparotomy and metroplasty [4]. Here we describe a new form of uterine anomaly which is both bicornuate and septate.

### Case one

A 35 year old woman with previous history

of three second trimester abortions was referred to our clinic to find the etiology of habitual abortion. As a routine in our clinic, we study all causes of habitual abortion. Immunological and hormonal evaluation of the patient was within normal limits. Study of karyotype of the wife and husband was also normal. The previous hysterosalpingography (HSG) of the patient showed bicornuate uterus. The patient had a previous history of having two Shirodkar operations in abortion number two and three without success. We scheduled the patient for a diagnostic laparoscopy and hysteroscopy in our surgical clinic. During laparoscopy we found a bicornuate uterus with a single cervix and nor-

\* The research has been performed under the financial support of Dr. Dabirashrafi Endoscopy & Fertility Research Center, Tehran University of Medical Sciences, Tehran, Iran.

1. **Corresponding author**, Associate Professor of Obstetrics and Gynecology, Tehran University of Medical Sciences, Mirza Kochak Khan Hospital, Obstetrics and Gynecology Department. Address: North Sohrevardi Ave. Hoveize Street. No. 50, Tehran, Iran. Tel: +982188762345, email: ivdrashrafi@yahoo.com.

2. Assistant Professor, Shahid Beheshti Medical University, Tehran, Iran.

3. Professor, Obstetrics and Gynecology Department, Head of Dr. Dabirashrafi Endoscopy & Fertility Research Center, Tehran University of Medical Sciences, Tehran, Iran.

4&5&6. Researcher, Dr. Dabirashrafi Endoscopy & Fertility Research Center, Tehran University of Medical Sciences.

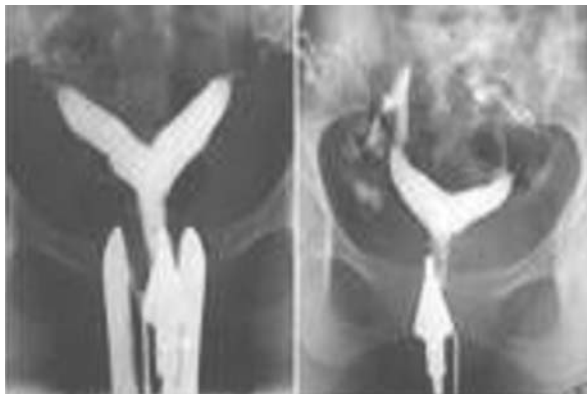

Fig. 1. Left: before operation; right: after operation.

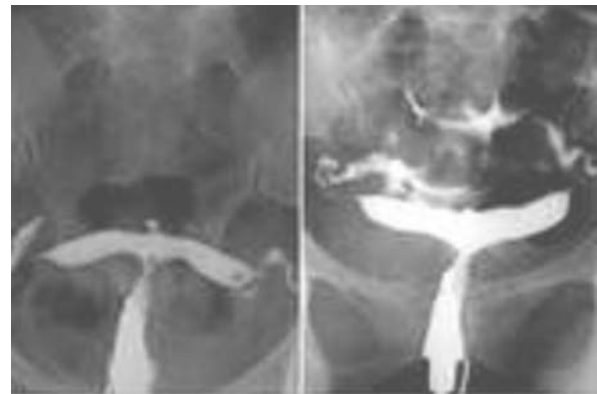


Fig. 2. Left: before operation; right: after operation.

mal adnexae. In hysteroscopy a septum was also discovered. The septum was incised with hysteroscopy miniscissors. The operation ended without any complications. No GnRh-agonist was prescribed before and no estrogen was used after the operation [5]. Two months later controlled HSG showed improvement of the uterine cavity; however the shape of the uterus was again a bicornuate (Fig. 1).

Three months after the operation, the patient became pregnant. At twelve weeks of pregnancy Shirodkar operation was performed on the patient. At 36 weeks of pregnancy the fetus showed breech presentation in the uterus. At this time the pregnancy ended by cesarean section (CS) and a healthy child was born.

### Case two

A 26 year old woman was referred to our clinic with a history of two first trimester abortions. All laboratory diagnostic tests, evaluating causes of abortion (sperm analysis, immunological and hormonal tests) were normal. The HSG of the patient showed a bicornuate uterus with the horns located very far from each other (Fig. 2).

The patient was scheduled for a diagnostic laparoscopy and hysteroscopy.

Laparoscopy showed a bicornuate uterus with horns being very distant from each other near the lateral pelvic wall. During hysteroscopy a small septum was found and incised by miniscissors. Shirodkar operation was

not performed after hysteroscopic metroplasty on this patient. The patient became pregnant four months after the operation. Pregnancy ended at 26 weeks of gestation because of a premature labor. The newborn died as a result of RDS.

### Discussion

According to The American Fertility Society Classification of Mullerian anomalies, bicornuate and septate uterus are two different classes of uterine malformations [1]. Extensive studies have confirmed that the preferred method of surgery for septate uterus is hysteroscopic metroplasty [2,3]. However the treatment of choice for bicornuate uterus is laparotomy and metroplasty (Strassman operation) [4]. It has been shown that the latter operation has complications such as intrapelvic and intrauterine adhesions. In some patients these complications cause secondary infertility [6]. These two cases reported in this article show that some bicornuate uteri are bicornuate-septate. To prevent the above-mentioned complications after laparotomy and metroplasty, we recommend hysteroscopic metroplasty if possible. If the result of hysteroscopic metroplasty is not satisfactory, then we can choose the Strassman operation. We had the experience of hysteroscopic metroplasty on 400 cases of septate uterus (unpublished data). Some of these patients were checked in second look laparoscopy+hysteroscopy or during CS. No intrapelvic adhe-

sion was seen in these patients. If we put aside the re-fusion of the septum, intrauterine adhesions are very rare in hysteroscopic metroplasty. We only saw this complication in one patient in our series (1/400). In this patient, septate uterus and missed abortion was found and treated at the same time via surgical hysteroscopy. With this experience if we found missed abortion in a septate uterus, first the missed tissues should be removed and metroplasty must be postponed for a later time. To our knowledge the bicornuate-septate uterus is a new uterine malformation and could be included in the classic American Society Classification for Mullerian Anomalies between class IV (bicornuate uterus) and class V (septate uterus). According to our experience in these two cases reported above, if this kind of uterine anomaly is found, hysteroscopic metroplasty should be the first line of operation.

---

### References

1. American Fertility Society classification of mullerian anomalies. *Fertil Steril* 1988; 49: 952
2. Daly DC, Walters CA, Soto-Albors CE, et al. Hysteroscopic Metroplasty: surgical technique and obstetrical outcome. *Fertil Steril* 1983, 39: 623.
3. Israel R, March CM. Hysteroscopic incision of the septate uterus. *Am J Obstet Gynecol* 1984: 149: 66
4. Rock JA, Breech LL. Surgery for anomalies of the Mullerian Ducts. In: Rock JA, Linde's Operative Gynecology. NY: Lippicott, Williams & Wilkins; 2003, pp. 740-41.
5. Jones JA. Comparison between abdominal and hysteroscopic metroplasty. *Obstet & Gynecol* 1986; 68 (3): 399-403.