

## Review Article

### NEURO IMAGING OF CNS LESIONS IN AIDS

HOMAYOON MOOSAVI, M.D., FARHAD KIOUMEHR, M.D., AND  
S. ABDULMAJEED ROOHOLAMINI, M.D.

*From the Department of Radiological Sciences, Olive View, UCLA, U.S.A., and Namazi Hospital, Shiraz  
University of Medical Sciences, Shiraz, I.R. Iran.*

#### ABSTRACT

**Background:** The aim of this study was to review and characterize the pattern of CNS lesions in patients suffering from AIDS and to correlate these patterns with clinical disorders.

**Method:** The MR scan, medical records and laboratory findings of 58 AIDS patients were reviewed retrospectively during April 1994 to November 1997 at the Olive view/UCLA and Shiraz Medical Centers, and the patterns of CNS involvement by secondary pathologic processes were divided into three types:

1- Focal parenchymal lesions with enhancement and mass effect that could be solid or ring shaped.

2- Focal parenchymal lesions without mass effect and enhancement.

3- Leptomeningeal enhancement with or without adjacent cortical involvement.

Focal parenchymal enhancing lesions appeared to be caused by toxoplasmosis and primary lymphoma.

Multiple ring enhancing lesions were most common with toxoplasmosis. Focal parenchymal lesions without mass effect and enhancement were detected specifically in PML and all were deep within the white matter structure.

Leptomeninges with or without adjacent cortical enhancement were seen in CNS infectious diseases such as TB, cryptococcosis/coccidioidomycosis and herpes zoster as well as in secondary CNS lymphoma. Granulomatous meningo-encephalitis mostly presented as basal leptomeningitis while herpes meningo-encephalitis was typically located in the temporal lobe. Secondary lymphoma showed high vertex leptomeningeal involvement.

The medical history/clinical presentation/CSF findings/stereotaxic biopsy, therapeutic response and postmortem pathologic results were used to distinguish the different etiologic agents.

**Results:** Of a total of 58 HIV seropositive patients, 12 (20%) appeared to be infected by toxoplasmosis, 7 (12%) by TB, 8 (14%) cryptococcosis, 5 (9%) coccidioidomycosis, 2 (3%) herpes zoster and 3 (5%) cases were diagnosed as PML (progressive multifocal leuko-encephalopathy) according to high serum titer for papova

\*Corresponding author: Homayoon Moosavi, M.D., 106-3455  
Drummond Street, Montreal, QC H3G 2R6, Canada.

virus group B. Sixteen cases revealed evidence of CNS lymphoma of whom 9 were diagnosed as primary and 7 as secondary CNS lymphoma. In 5 cases HIV infection itself was suspected to be the etiology of the abnormal MRI finding.

**Conclusion:** In spite of newly developing MR spectroscopy techniques for differentiation of CNS lesions in AIDS, categorization of different MRI patterns of CNS diseases in HIV seropositive patients is still helpful in differentiating various types of common CNS lesions in AIDS.

*MJIRI, Vol. 19, No. 4, 349-361, 2006.*

## INTRODUCTION

About 20% of AIDS patients develop focal or diffuse brain lesions before death,<sup>1</sup> the most common of which are toxoplasmosis, lymphoma, PML, cryptococcosis, tuberculosis and herpes meningo-encephalitis.

For brain lesions in non-immune compromised patients biopsy is usually performed to obtain histologic confirmation to direct appropriate therapy. However, in AIDS patients this protocol is not accepted because of restricted life expectancy and potential dangers.<sup>4</sup>

Categorization of findings in AIDS neuroimaging can help to characterize and diagnose the most common ones such as toxoplasmosis, lymphoma, PML, etc.

On the other hand empiric treatment for focal lesions or leptomeningitis may harm some patients while the undiagnosed pathology would grow up rapidly in AIDS patients.<sup>1</sup> Therefore noninvasive techniques are needed for differentiation among the common lesion in AIDS. Most recently some attempts were done to differentiate among these entities especially in AIDS patients by MR spectroscopy, but the results are controversial.<sup>1,13</sup> Most of the common diseases in AIDS have distinct histopathologic and subsequently MR imaging appearances.<sup>2,3,5</sup>

For example, toxoplasmosis causes parenchymal abscess with central necrosis and surrounding inflammation.<sup>13,14,15</sup>

Primary lymphomas are infiltrating cellular masses mostly of the non-Hodgkins type, and the lesions are deeply seated in periventricular areas with marked edema and enhancement. Leptomeningitis is a common pattern of secondary lymphoma.<sup>7,4,28</sup>

PML (progressive multifocal leuko-encephalopathy) leads to multifocal demyelination in subcortical white matter, mostly bilateral, but asymmetric.

Fungal infections are histologically diverse and cause leptomeningitis and brain abscess.<sup>12</sup>

Tuberculosis in AIDS may appear as focal brain lesions (tuberculoma) or as leptomeningitis and encephalitis.<sup>19,20</sup>

Herpes meningo-encephalitis in AIDS patients is quite common but may not show characteristic temporal lobe involvement.

Each of these diseases may have a characteristic MR imaging appearance.

Typical toxoplasmosis has multifocal enhancing lesions, while primary lymphoma has a single enhancing lesion that encases the ventricles.<sup>8,9</sup> But exceptions to these patterns are common. About 30% of toxoplasmosis in AIDS may manifest as a single lesion and 30% of primary lymphomas may be multiple in HIV positive patients.<sup>2,3,10,17</sup>

PML MR findings are usually non-enhancing multifocal white matter hyperintense lesions in T2 weighted images with little mass effect.

Fungal infection (cryptococcus and coccidioidomycosis) may show focal meningo-encephalitis and basal meningitis; multiple round cystic lesions with little or no surrounding edema are less common in AIDS patients. Fungal meningo-encephalitis mostly results from systemic fungal infection and pathologically gives a granulomatous reaction. CT and MR findings are hardly distinguishable from those of TB.<sup>6,10</sup> Tuberculosis may have typical thick leptomeningeal enhancement in basal cisterns or appears as focal enhancing brain lesions. Parenchymal tuberculoma shows low signal intensity on T2 weighted images; enhancement could be nodular or ring shaped.<sup>6,20</sup>

## MATERIAL AND METHODS

In a retrospective study, all MRI studies of the brain in 96 HIV seropositive patients done at our institution (Olive View UCLA Medical Center and Namazee Shiraz University Medical Center) from April 1993 through September 1997 were reviewed.

Fifty-eight patients who showed any type of focal lesion and/or leptomeningeal abnormalities were selected to form the basis of this study. Subsequently the medical records of these patients were reviewed. Clinical information and laboratory data including CSF analysis

were collected. Patients with insufficient clinical or laboratory findings were excluded from the study.

All HIV seropositive patients presented with neurological symptoms attributed to the focal parenchymal or leptomeningeal lesions. These included headache, change in mental status, seizures, focal neurological deficits and cranial nerve symptoms.

All the patients included in the study had CSF analysis or histopathologic confirmation.

All the patients were imaged with an 1.0T impact super conducting magnet (Siemens MR machine) and resistive 0.3T (Hitachi MR machine). All sections were 5mm thick with an intersection gap of 1-2mm using standard two dimensional fourier transform (2DFT) SE technique, the T1-weighted (600-800/20/TR/TE) and T2 weighted (2000-3000/30-120 TR/TE) imaging were performed in the axial plane before and after intravenous administration of Gd-DTPA.

Additional coronal and sagittal post-contrast MR scans were taken and some cases had CT scan by a GE 9800 as well.

Final diagnosis was based on the medical history, clinical presentation and follow up CSF analysis, pathological, surgical findings when available and response to medical therapy.

Different patterns of focal parenchymal and leptomeningeal lesions were recognized and correlation was made between MRI findings and etiologic clinical diagnosis.

MRI and CT findings were divided into three categories on the basis of anatomic location of the parenchymal lesions, presence of mass effect and attributed leptomeningeal enhancement and its distribution after Gd-DTPA injection.

According to clinical etiology enhancing focal cortical lesions with or without leptomeningitis are seen in tuberculosis, cryptococcosis, coccidioidomycosis and herpes meningo-encephalitis.

Parenchymal lesions in subcortical and deep white matter with mass effect and enhancement are mostly referred to toxoplasmosis and primary CNS lymphoma. Those without mass effect and mild to absent enhancement upon Gd-DTPA injection are mostly secondary to PML (progressive multifocal leuko-encephalopathy).

Nonspecific cortical sulci prominency/scattered

patchy deep white matter lesions that are non-enhancing all appeared to be attributed to the HIV type I viral infection.

Criteria for infectious meningo-encephalitis include clinical presentation of fever, headache, nuchal rigidity, CSF analysis of elevated white blood cell count and proteins and positive culture when available.

Toxoplasmosis, lymphoma and PML are diagnosed either according to brain biopsy response to anti-toxoplasma medications (pyrimethamine-sulfadiazine and clindamycin), detection of serum titer for papova virus or postmortem autopsy findings. Secondary CNS lymphoma was easily categorized according to peripheral lymphoproliferative system involvement.

## RESULTS

A summary of the results are given in Tables I, II and III. Nine groups of AIDS patients were identified. There were 12 toxoplasmosis, 7 tuberculosis, 8 cryptococcosis, 5 coccidioidomycosis, 3 PML, 2 herpes infection, and 16 CNS lymphoma. In 5 cases HIV infection itself was suspected to be the etiology of abnormal MRI findings.

A detailed description of each of these groups follows.

**Toxoplasmosis**-All 12 toxoplasmosis cases had focal mass with edema and contrast material enhancement on MR images, of which nine cases showed typical ring enhancing (Fig. 1) and three patients demonstrated solid enhancing lesions in cortical and subcortical brain tissue (Fig. 2).

**Table I:** Neuro imaging of CNS lesions in patients with AIDS.

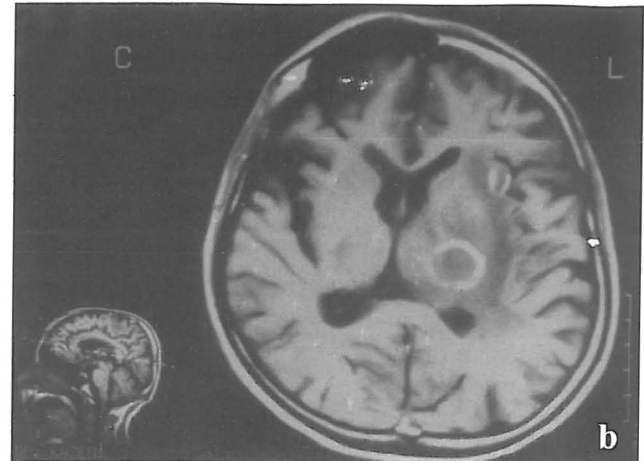
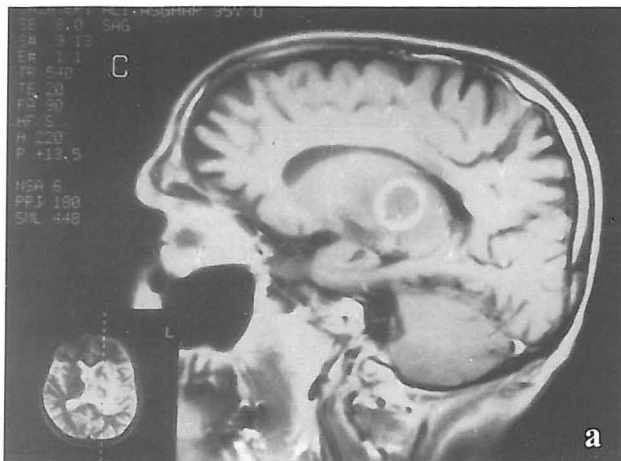
Disease	No.	%
Toxoplasmosis	12	(21%)
CNS lymphoma	9	(16%)
Cryptococcosis	8	(14%)
Tuberculosis	7	(12%)
Coccidioidomycosis	5	(9%)
Lymphoma	7	(12%)
PML	3	(5%)
Herpes	2	(3%)
HIV type I	5	(8%)
Total	58	(100%)

**Table II:** MR findings in AIDS with focal brain lesions.

Disease	No. of patients	Solitary lesion	Multiple lesions
Toxoplasmosis	12	1	11
Primary lymphoma	9	5	4
PML	3	-	3

**Table III:** Patterns of MR findings in AIDS with leptomeningitis.

Disease	No. of Cases	Basal involvement	Cortical involvement
TB	7	6	1
Cryptococcosis	8	5	8
Coccidioidomycosis	5	2	5
Herpes zoster	2	-	2
Secondary lymphoma	7	2	5
HIV type I	5	-	5



**Fig. 1. (a-b):** Toxoplasmosis ring enhancing lesions; (a) axial and (b) sagittal contrast enhanced T1 weighted MR images show two ring enhancing lesions in basal ganglia and sylvian cortex with marked surrounding edema.

All of the cases had multiple lesions. Both nodular and ring enhancing lesions were not larger than 30mm in diameter (Fig. 3).

**Lymphoma-** of 16 cases with clinical evidence of lymphoma nine were categorized as primary lymphoma due to absence of any sign of peripheral involvement.

Primary lymphomas were located deeply within the brain near the ventricular system. One case showed diffuse extension along the ventricular wall (Fig. 4). The lesions were hypoisosignal with gray matter on T1 and hyperintense on T2 weighted images.

On CT scan lymphomatous lesions appeared isodense to gray matter and upon contrast injection homogenous enhancement was seen.

Marked edema along with homogenous post-contrast enhancement was seen in six of the lymphomatous lesions (Fig. 5) and three had a ring enhanced pattern described in AIDS. Lymphomatous lesions were often larger than 30mm in diameter (Fig. 6).

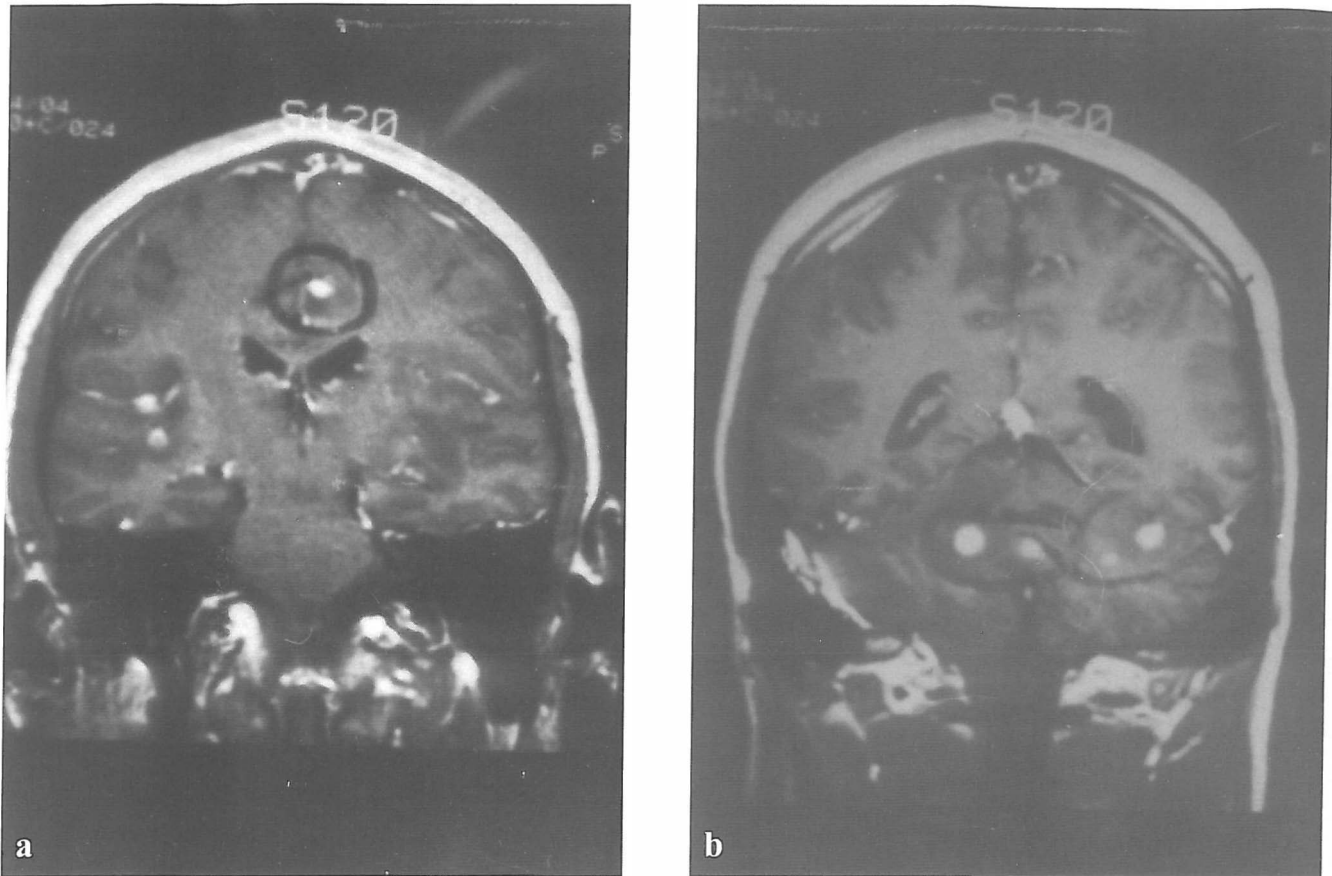
The so-called secondary lymphoma mostly mani-

fested with pachy-leptomeningitis as enhancement of dura and meninges or perineural extension through the cranial nerves. Focal parenchymal lesions were not seen in this group (Fig. 7).

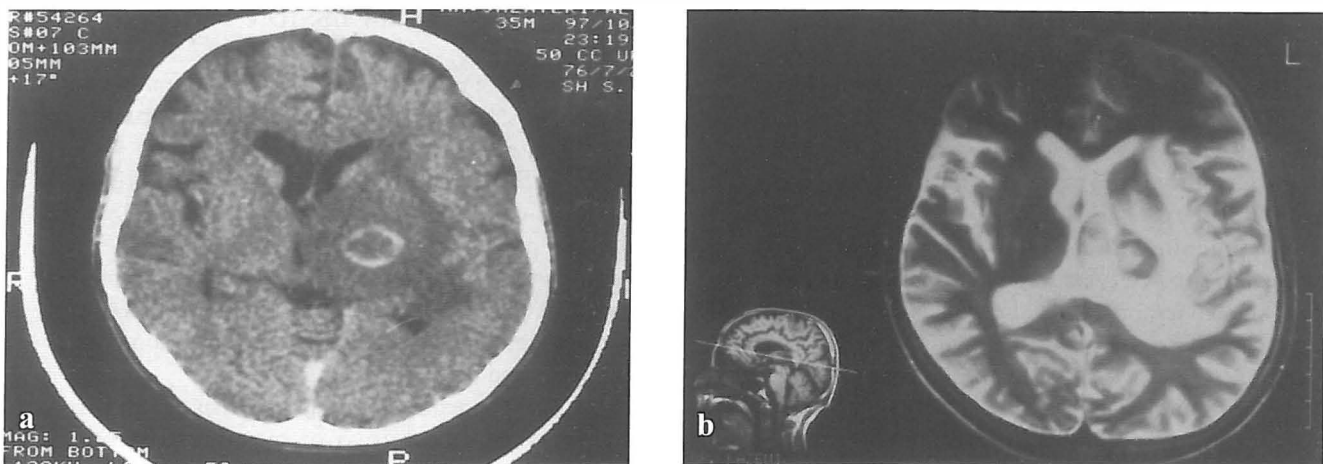
**PML-**all three patients had lesions that were mildly hypointense on T1 and hyperintense on T2 weighted images. There was minimal or no mass effect. Some of them were coalesced to give larger lesions (more than 3 cm in diameter). None of them showed any enhancement after gadopentate-dimeglumine injection (Fig. 8).

**Cryptococcoma and coccidioidomycosis-**MR images showed focal cortical and associated leptomeningeal enhancement in favor of meningo encephalitis. This involvement was mostly in basal cistern and sylvian fissures. The degree of enhancement however was less than that of TB. None of the cases showed focal parenchymal abscess in our series (Fig. 9).

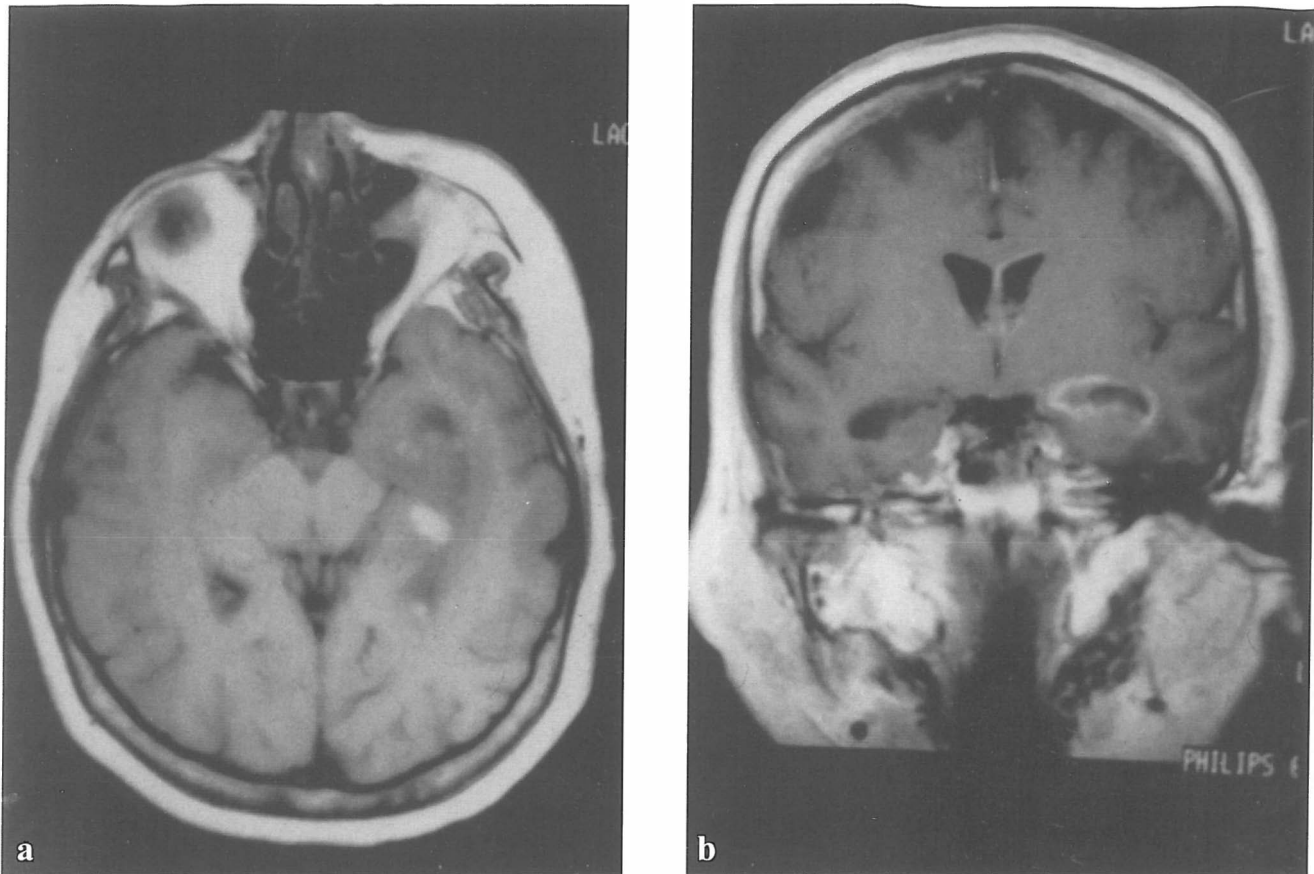
**Tuberculosis-**MR findings in TB meningo-en-



**Fig. 2. (a-b):** Toxoplasmosis solid enhancing lesions; (a) axial and (b) sagittal T1 weighted MR images with Gd. DTPA show multiple small solid enhancing lesions in subcortical and brain stem with surrounding edema.



**Fig. 3. (a-b):** Toxoplasmosis in an HIV seropositive patient; (a) CT post-contrast axial and (b) T2 weighted MR axial shows toxoplasma lesions less than 30 mm in diameter with marked surrounding edema.



**Fig. 4. (a-b):** Primary CNS lymphoma; axial (a) and coronal (b) post-contrast T1 weighted MRI shows periventricular lesions with ventricular wall involvement.

cephalitis all appeared as thick basal leptomeningeal enhancement and occasional focal encephalitis. Focal tuberculoma was less common than leptomeningitis and appeared as nodular or ring enhancing lesions. There was one case manifested as multiple focal tuberculoma in our series. The differentiating point from toxoplasmosis was its characteristic central hyposignal appearance on T2 weighted images (Fig. 10).<sup>20</sup>

**Herpes meningo encephalitis-** The two cases of herpes infection showed typical temporal lobe involvement with associated leptomeningeal enhancement. There was no atypical pattern of brain involvement in this series. (Fig. 11).<sup>26,27</sup>

**HIV leptomeningitis-** We had five cases who showed leptomeningeal enhancement all over the brain on T1 weighted post gadolinium MR images (Fig. 12). There were no clinical or lab findings in favor of superimposed infectious or neoplastic processes. It seems that this pattern of involvement of HIV in

the brain is quite common.

## DISCUSSION

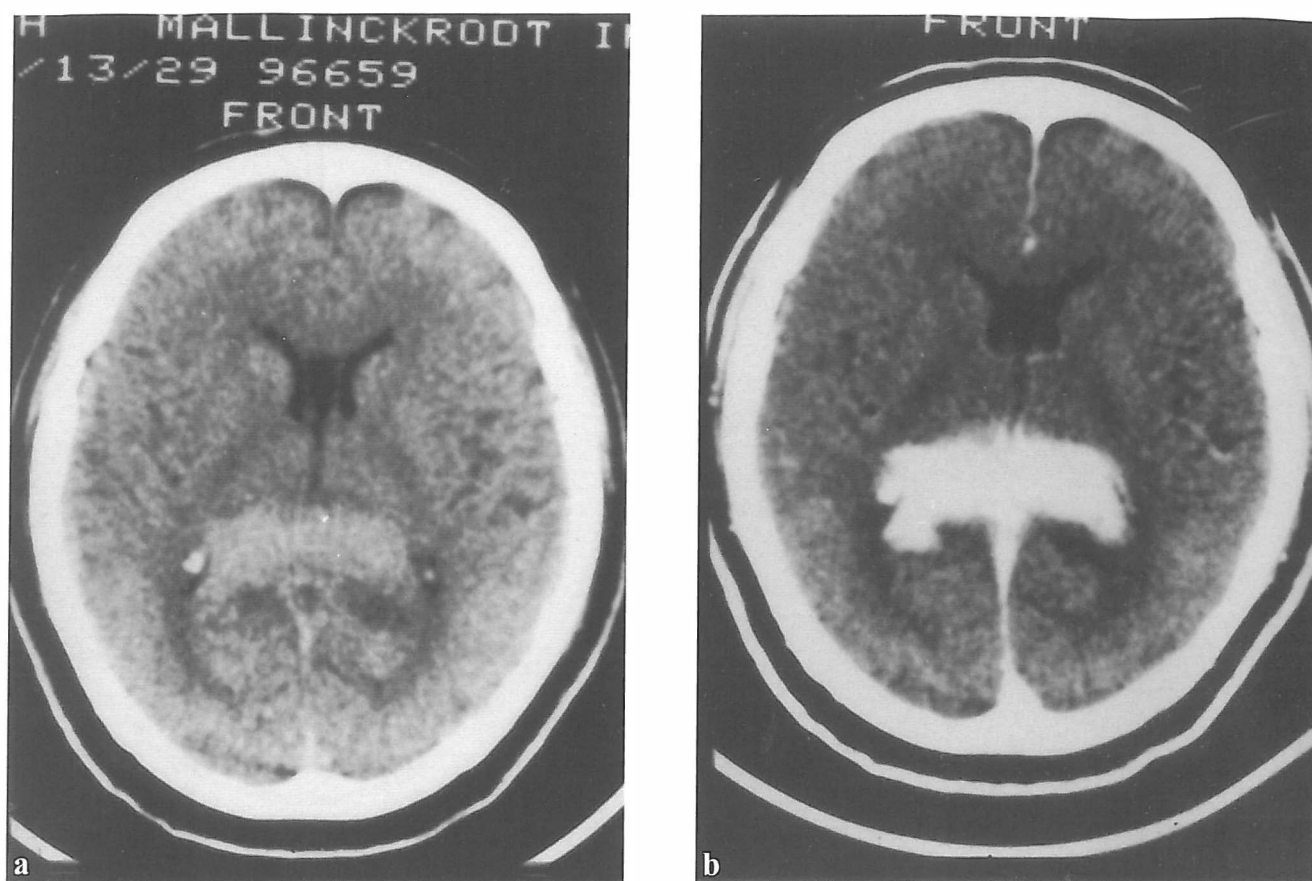
Human immune deficiency virus type I usually causes subacute encephalitis as well as acute or chronic leptomeningitis.

Besides HIV, other viruses associated with AIDS may cause aseptic meningitis, including herpesvirus, cytomegalovirus, papova virus, etc.<sup>16</sup>

Pathologically the major feature of viral encephalitis is neuronal degeneration and inflammation. Gross pathologic findings range from none to diffuse brain congestion edema and necrosis.

By MRI, the pathologic changes usually appear as scattered or confluent areas of hyperintensity on T2-weighted images and iso/hypointensity on T1-weighted images with variable mass effect.<sup>21</sup>

Beside these general features of viral encephalitis, there are additional findings with AIDS that may help in



**Fig. 5. (a-b):** Primary CNS lymphoma; axial (a) and (b) post contrast CT of brain shows an isodense periventricular mass with marked enhancement post-contrast injection.

differential diagnosis.

In the brain replicating HIV has been found most often within the macrophages and multinucleated giant cells. Polymorphic microglia are also frequently infected by HIV. Astrocytes and oligodendroglia are infrequently and neurons are rarely infected by HIV.<sup>22</sup>

Multinucleated giant cells are scattered throughout the white matter or clustered together in microglial nodules in cortex basal ganglia as well as in white matter.<sup>22</sup>

Demyelination is a secondary and late finding. MRI can detect these pathologic findings better than CT.<sup>10,21</sup>

These abnormalities consisted mainly of enlargement of the cortical sulci and ventricles and the presence of bilateral/patchy hyperintense areas in T2 weighted MR images which may progress from small scattered lesions to diffuse, confluent areas.<sup>21</sup>

Sometimes in AIDS patients, there may be a secondary infection involving the CNS. One of the common secondary viral infections is by group B papova virus, that can cause progressive degenerative leukodystrophic

disease (PML). It occurs in at least 1-4% of AIDS patients.

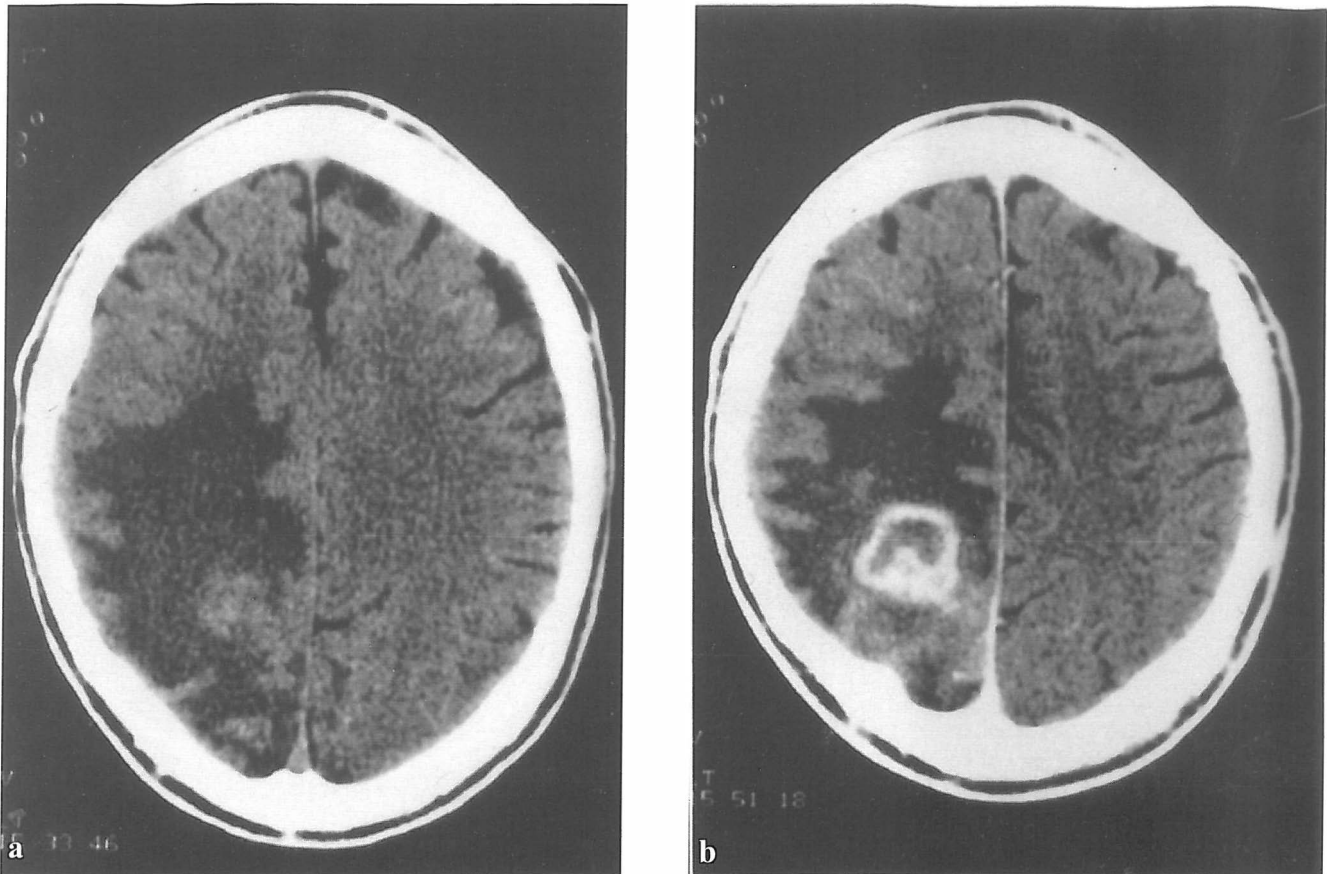
The virus infects the myelin producing oligodendrocytes resulting in destruction and causes demyelinating white matter lesions.<sup>23</sup>

The early lesions of PML are small, oval or round and begin in the subcortical white matter and spread to deeper tissue later and become large and confluent. Involvement is most often asymmetric. There is a tendency to favor the centrum semiovale posteriorly.<sup>23</sup> Typically the lesions appear as areas of hyperintensity in T2-weighted images.

Atypical patterns may be seen to involve the thalamic and basal ganglia.<sup>21</sup>

The other superimposed viral infection in AIDS patients is herpes zoster. The patterns of meningo encephalitis may not always be typical as seen in temporal lobes and may involve multiple areas in the brain especially in deep white matter.<sup>24,25</sup>

The incidence of CNS lymphoma in patients with



**Fig. 6. (a-b):** Primary CNS lymphoma; axial pre(a) and post (b) contrast CT in a patient shows a single ring enhancing lesion in supraventricular subcortical tissue with marked edema.

AIDS has increased and is second in frequency only to toxoplasmosis among CNS mass lesions in AIDS patients, while its nature in the CNS is still a big question since there is no lymphatic tissue in the CNS. Primary CNS lymphoma mostly appears subependymal or deeply seated in the brain parenchyma and may constrict a portion of ventricle.<sup>2,7,8,9,28</sup> Most of them are enhancing nodules in CT and MRI (70%) while some may also shows ring enhancement on contrast enhanced MRI. Regarding the number of lesions half of the cases are solitary and half are multiple.<sup>10,15,16</sup>

TB that was supposed to be undergoing eradication especially in developed industrialized countries is now coming back. It is a common infectious disease in immune compromised patients and especially in AIDS.

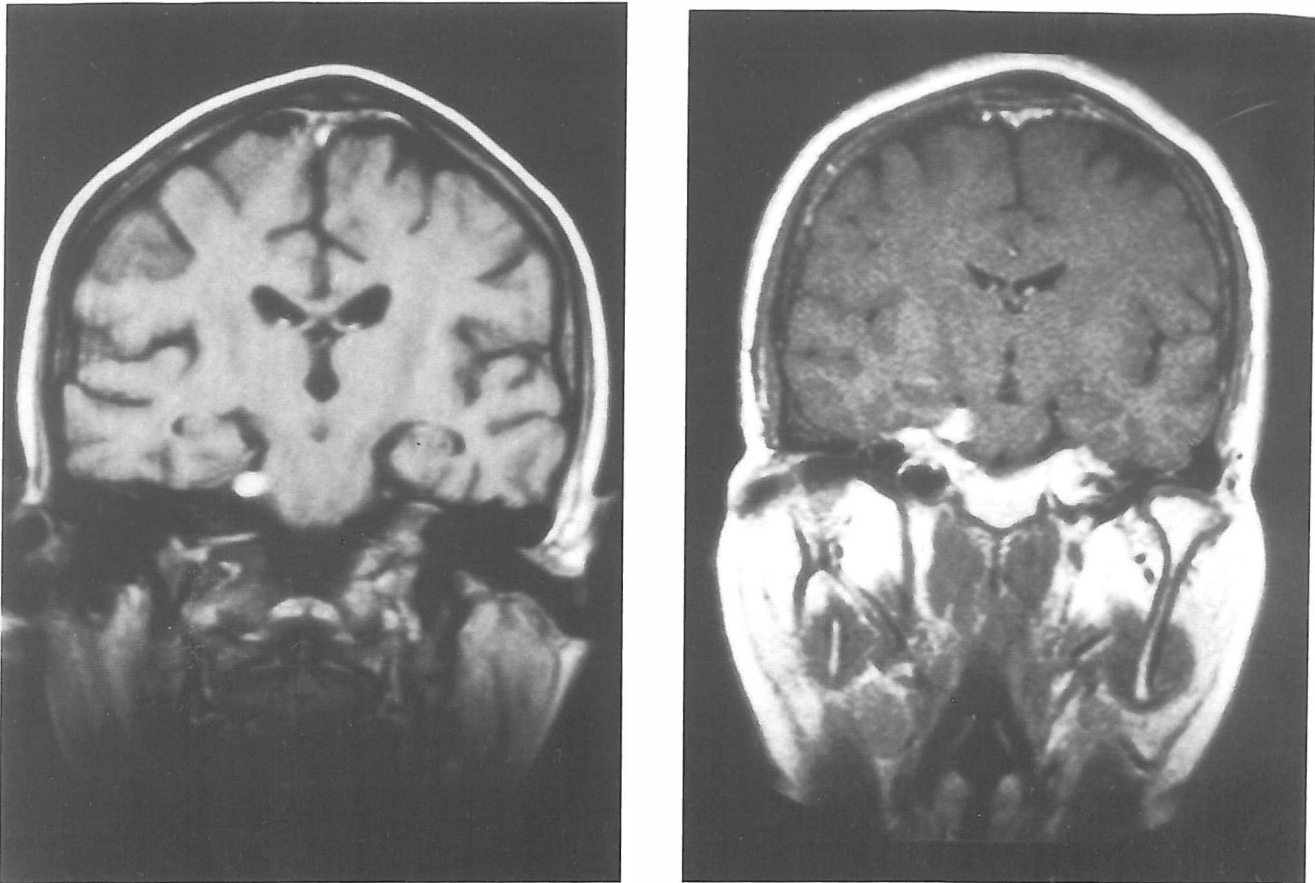
There are two routes for the involvement of brain and meninges in TB: hematogenous spread to the walls of the intraparenchymal vessels and meninges and CSF seeding,<sup>6,10,12,20</sup> and rupture of a subependymal granuloma into the CSF.

By either mechanism, the basal meninges are involved early in the course of infection. There may be associated hydrocephalus secondary to blockage of the basal cistern by the inflammatory exudate. Basal cistern and diffuse meningeal enhancement on post-gadolinium T1 weighted MR images are easily detectable in AIDS patients. On the other hand parenchymal tuberculoma appears hyposignal in T2 weighted images which seems to be due to dense fibrosis and free radicals.<sup>19,20</sup>

In AIDS patients, cryptococcosis and coccidioidomycosis are common fungal infections. As compared to toxoplasma, the cryptococcal granuloma is less widely distributed and does not demonstrate as much edema.

There are three morphologic types of intracerebral lesions described for fungal lesions: gelatinous mass, fibrogranulomatous mass and abscess.

CNS infection by cryptococcus and *Coccidioides immitis* results in meningeal inflammation and caseous granuloma particularly at the base of the brain. Focal granuloma appears less often in HIV positive patients.



**Fig. 7. (a-b):** Secondary lymphoma: coronal T1 weighted post contrast MR images in two HIV seropositive patients with Hodgkin's lymphoma show perineural extension through the cranial nerve.

The most common MR and CT findings are abnormal contrast enhancement of meningeal surfaces over the convexities and in the basal cistern.<sup>16</sup>

In AIDS patients toxoplasma may cause a fulminant necrotizing encephalitis with three distinct zones: central zone of necrosis, intermediate hypervascular zone and peripheral zone of hypovascularity. When there is leptomeningitis, it is mostly adjacent to the areas of encephalitis. On CT scan and MRI toxoplasmosis may appear as solitary or multiple ring or nodular enhancing masses.

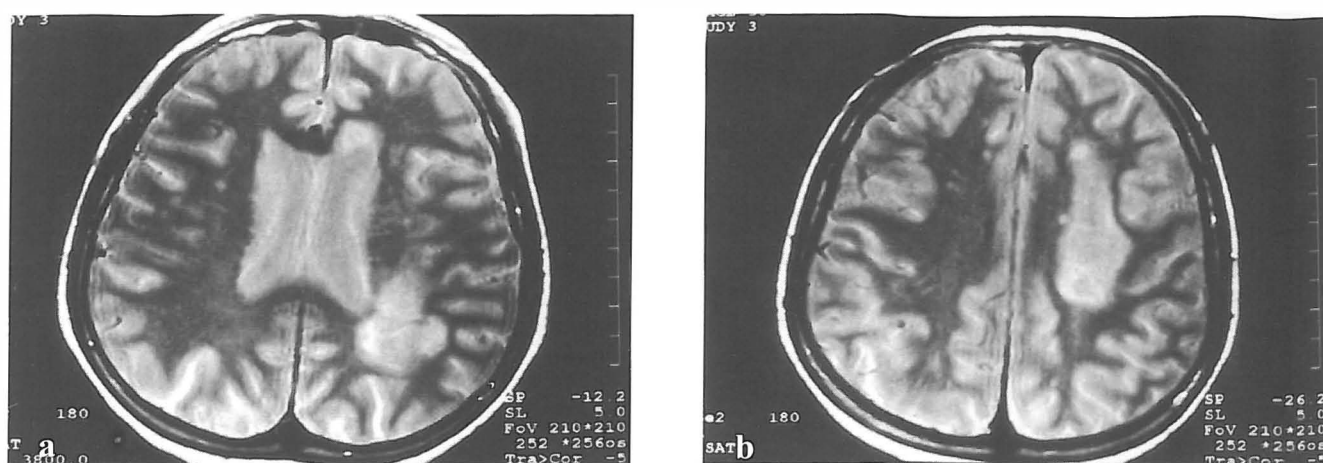
Differentiation from primary CNS lymphoma is basically the location and size of the ring enhancing lesions. Toxoplasmosis is mostly less than 30mm in diameter and can be seen anywhere in the brain parenchyma while lymphoma are larger and deeply seated. In contrast to lymphoma, toxoplasma lesions are mostly multiple and upon response to treatment, toxoplasma lesions calcify.<sup>19</sup>

## CONCLUSION

This work shows that the most common brain lesions seen in patients with AIDS have distinctly different MRI findings. By using the pattern of focal mass lesion, involvement of leptomeninges and degrees of enhancement, one may be able to differentiate between toxoplasmosis, lymphoma, PML and other granulomatous infections such as encephalitis.

According to the above data three distinct patterns of CNS lesions were experienced in AIDS neuroimaging:

1. Focal parenchymal lesion in sub-cortical and deep white matter that if associated with mass effect and enhancement are typical for primary lymphoma and toxoplasmosis. Those without enhancement and mass effect are mostly secondary to PML. Multiple ring enhancing lesions are seen more in toxoplasmosis while primary lymphoma shows more solid lesions.
2. Focal cortical lesions with leptomeningeal enhancement are mostly seen in tuberculosis, cryptococcosis,



**Fig. 8. (a-b):** PML (progressive multifocal leukoencephalopathy); Axial proton density MR images of an HIV sero-positive patient show leukodystrophic plaques in periventricular and subcortical deep white matter with no mass effect.

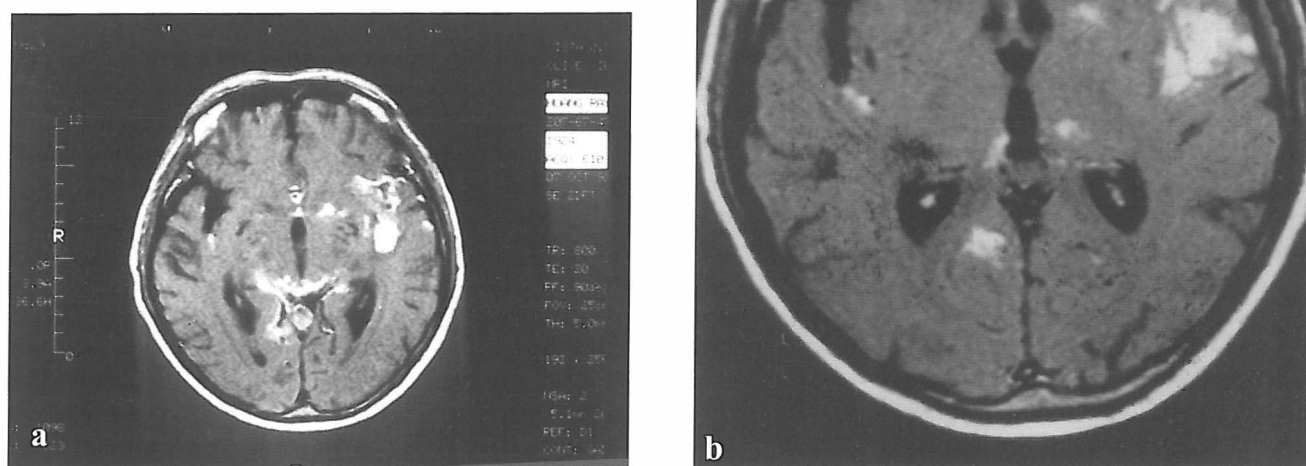
coccidioidomycosis; herpes meningo-encephalitis and secondary lymphoma; however, anatomical distribution is different.

3. Non-specific cortical sulci prominence with leptomeningeal enhancement and patchy deep white matter lesions that are non enhancing could be seen in HIV type I viral infection in early and subsequently late stages of HIV infection without superimposed pathology.

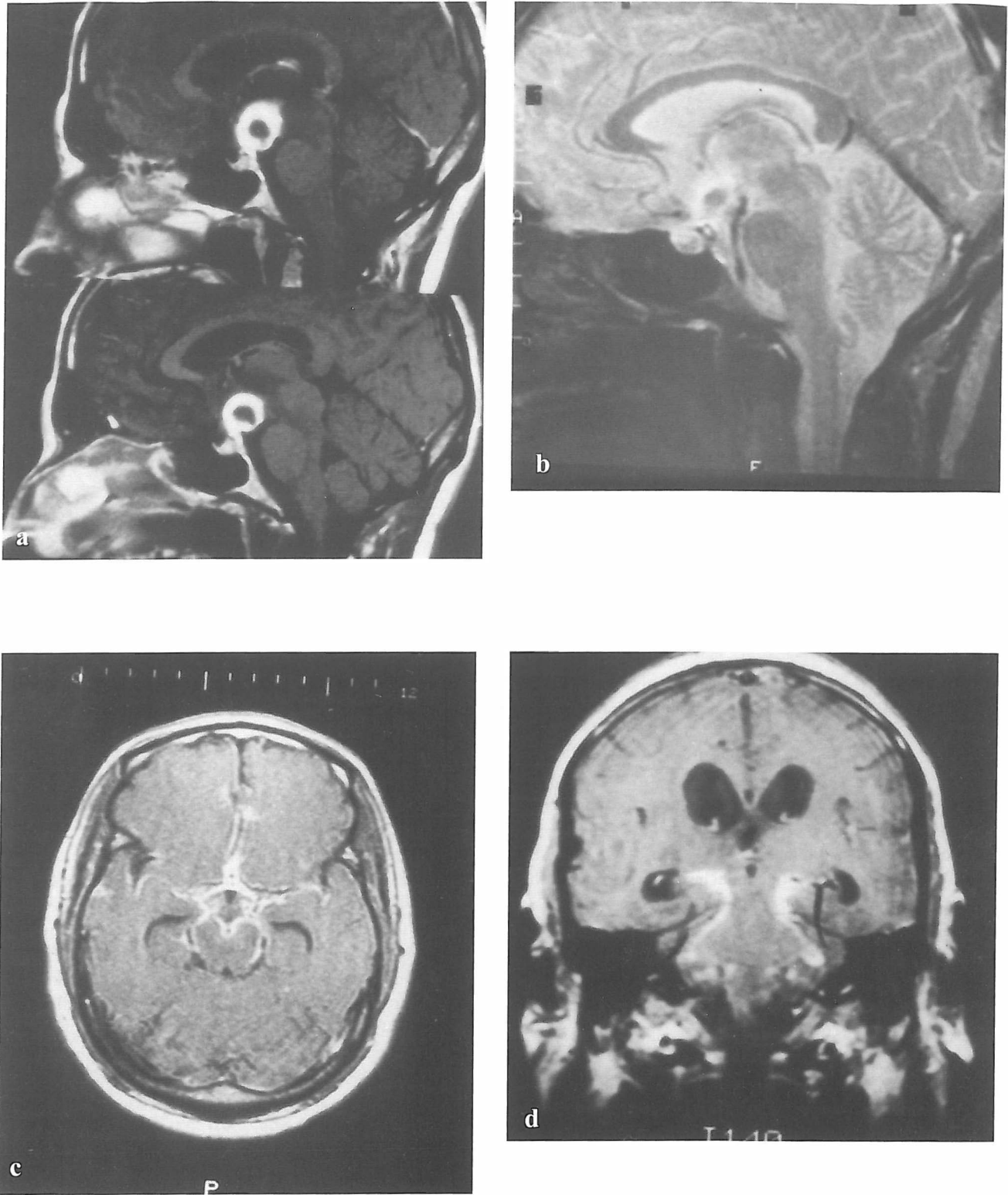
We concluded that categorization of different MR patterns of focal brain lesions and leptomeningeal enhancement may be helpful in differentiating various types of common CNS lesions in AIDS patients.

## REFERENCES

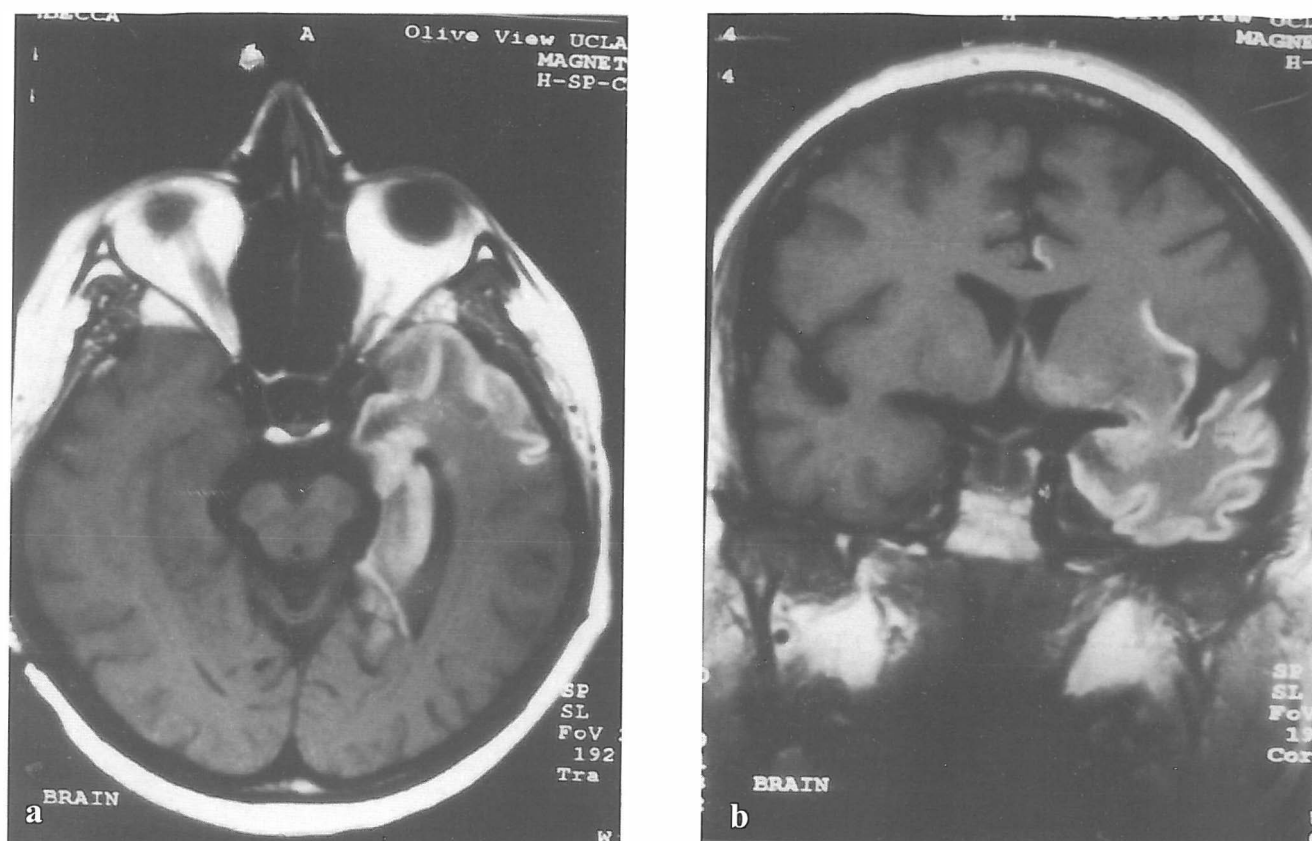
1. Chung L, Railler BL, McBride D, et al: Brain lesions in patients with AIDS. *Radiology* 197: 525-531, 1995.
2. Diana S, MacMochan E, Glass JD, et al: Primary cen-



**Fig. 9. (a-b):** Fungal meningoencephalitis in AIDS; Axial post-contrast T1 weighted MR images in (a) cryptococcal and (b) coccidioidomycotic meningo-encephalitis demonstrate focal cortical enhancement with associated lepto-meningitis in the sylvian sulcus and in basal cistern.

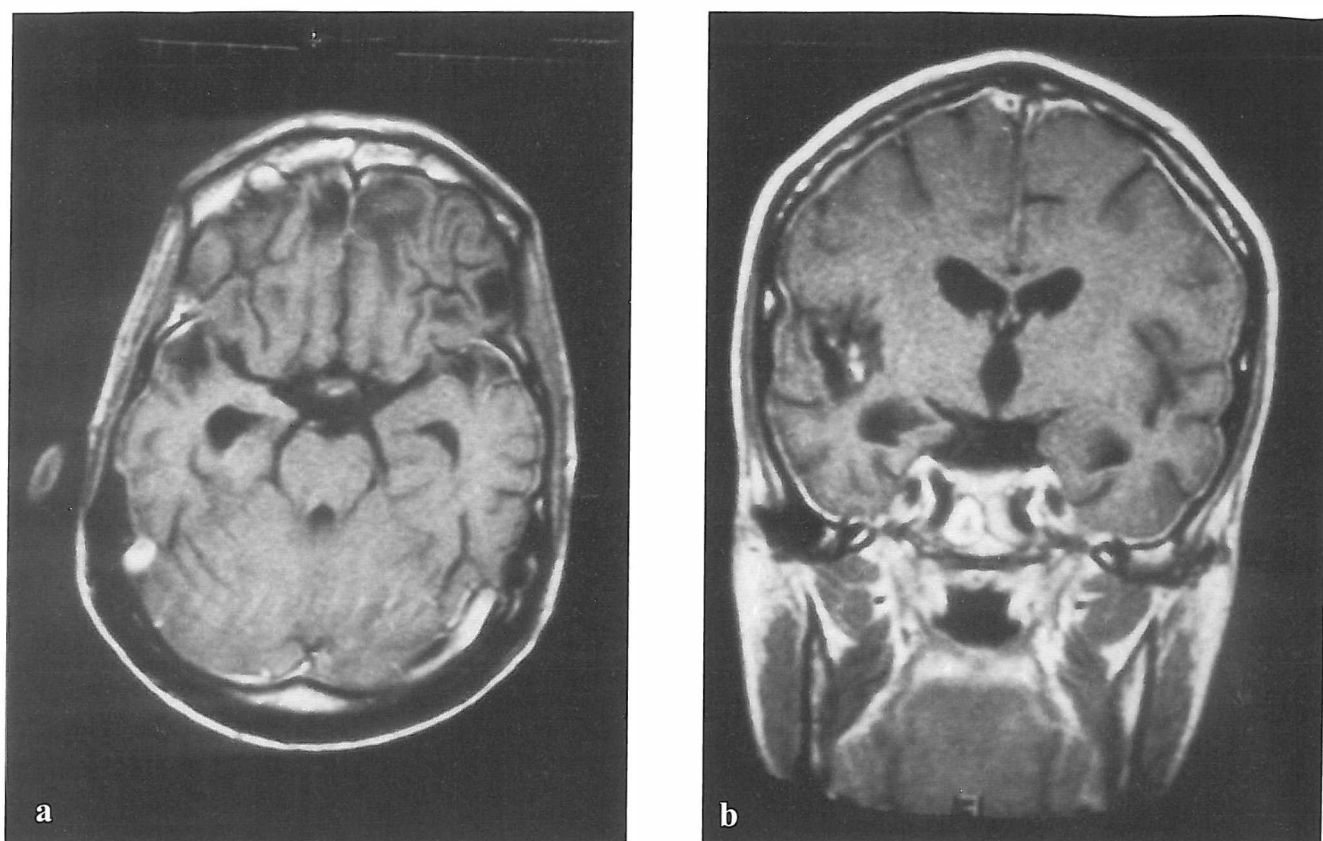


**Fig. 10. (a-b):** TB meningo encephalitis in AIDS; Sagittal T1 weighted post contrast and (b) sagittal T2 weighted MR images in a HIV sero positive patient infected by TB shows hypothalamic tuberculoma with ring enhancement which has central hypo signal intensity in T2 weighted images (c-d) Axial and coronal T1 weighted post contrast MR images shows thick basal cistern leptomenigeal enhancement.



**Fig. 11. (a-b):** Herpes meningo-encephalitis; Axial (a) and coronal (b) T1 weighted postcontrast MR images in an HIV seropositive patient infected by herpes shows typical temporal meningoencephalitis.

- tral nervous system lymphoma versus toxoplasmosis in AIDS. *Radiology* 179: 823-824, 1991.
3. Ciricillo SF, Rosenblum ML, et al: Use of CT and MR imaging to distinguish intracranial lesions and to define the need for biopsy in AIDS patients. *J Neuro Surgery* 73: 720-724, 1990.
  4. Colbassani HJ, et al: CT assisted stereotactic brain biopsy. *J Neurol Neurosurg Psychiatr* 51: 332-341, 1998.
  5. Cornford ME, et al: Aleuro pathology of the AIDS. *Can J Neurol Sci* 19: 442-452, 1992.
  6. Kioumeh F, et al: Post contrast MRI of cronial meninges. *J of Computer Assisted Tomography* 19(5): 713-720, 1995.
  7. Goldstein JD, Dickson DW, Moser FG, et al: Primary central nervous system lymphoma in AIDS. *Cancer* 67: 2756-2765, 1991.
  8. Schwaighofer BW, Hesselink JR, Press GA, Wolf RL, et al: Primary intracranial CNS lymphoma. *AJNR* 10: 725-729, 1989.
  9. Waten K, et al: Primary malignant lymphoma of the brain. *Acta Oncologica* 31(5): 545-550, 1992.
  10. Munding A, et al: CT and MRI: Prognostic tools in AIDS. *Neuroradiology* 35: 75-78, 1992.
  11. De Angeliss LM, Wang E, Rosenblum M, et al: Primary central nervous system lymphoma. *Neurology* 41: 619-621, 1991.
  12. Wrobel CJ, Meyer S, et al: MR findings in acute and chronic meningitis. *AJNR* 13: 1241-5, 1992.
  13. Roger JS, Baulanger Y, Bard C, et al: Toxoplasmosis and primary CNS lymphoma in HIV infection. *Radiology* 197: 649-654, 1995.
  14. Petito CK, Cho E, Lamana W, et al: Neuropathology of AIDS. *J Neuropath Exp Neurol* 45: 635-646, 1986.
  15. Montgomery H, et al: Cerebral mass lesions in patients with AIDS. *British Med J* 301: 226-228, 1990.
  16. Levy RM, et al: Central nervous system mass lesions in AIDS. *J Neurosurg* 61: 9-16, 1984.
  17. Rodesch G, et al: Alervous system manifestations and neuroradiologic findings in AIDS. *Neuro Radiology* 31: 33-39, 1989.
  18. Chang L, et al: Radiologic pathologic correlation. *AJNR* 16: 1-11, 1995.



**Fig. 12. (a-b):** HIV meningitis. Axial (a) and coronal (b) T1 weighted postcontrast MR images in an HIV positive patient demonstrate enhancement of pachymeninges suggestive of HIV meningitis. Generalized cortical sulci atrophy is the sequelae of chronic HIV encephalitis.

19. Paker JC: Primary CNS lymphoma in AIDS: clinical-pathologic study. *Neuropathology* 632-703, 1985.
20. Kioumehri F, Dadsetan R, Rooholamin SA, et al: CNS tuberculosis. *Neuroradiology* 36: 93-96, 1994.
21. Olsen WL, et al: Viral leuko-encephalitis in AIDS. *Radiology* 169: 445-448, 1988.
22. Petito CK: Neuro path of AIDS. *J Neuro Path Exp Neuro* 23: s54-s57, 1988.
23. Krupp LB: Primary CNS lymphoma..... *Ann Neurol* 17: 344-349, 1985.
24. Dieter E, et al: MR findings in neonatal herpes simplex encephalitis. *J of Computer Assisted Tomography* 14(3): 453-457, 1990.
25. Switzer PH, et al: GD-DTPA enhanced MRI of herpes simplex encephalitis. *J Clinical Imaging* 15: 121-124, 1991.
26. Lentz DJ: MRI in varicella zoster. Infection and inflammation. *Computer Assist Tomog* 17: 313-316, 1993.
27. Sze G: Textbook of MRI, In: Stark D, Bradley WB, (eds.), Mosby Publication, Second edition, pp. 316-343, 1992.
28. Koeller K, Smirniopoulous J, Jones R: Primary CNS lymphoma... *Radiographics* 17: 1497-1526, 1997.

