

ANGIOPLASTY AND STENTING OF CAROTID ARTERY STENOSIS WITH EMBOLIC PROTECTION DEVICES

ALI MOHAMMAD HAJI ZEINALI, M.D.,* AND DAVOOD KAZEMI
SALEH, M.D.**

*From the Interventional Department of Tehran Heart Center, Tehran University of Medical Sciences, and
Baghiatallah Hospital, Tehran, Iran.*

ABSTRACT

Background: Carotid artery stenting (CAS) has recently been recommended as an alternative to carotid endarterectomy (CEA) by some clinicians.

Objective: This study was designed to evaluate the success rate and in-hospital and 30-day adverse events in our first experiences in Iran for CAS with protection devices, to document our results and guide further use of CAS.

Methods: From December 2003 to December 2004 we performed 21 consecutive CAS procedures. 16 were men and 5 were women with mean age of 62 years (range 46-78 years). Indications for CAS included primary lesions in all patients with stenosis >50% in symptomatic and stenosis >80% in asymptomatic patients.

Results: CAS was technically successful in all 21 patients. Mean severity of stenosis before CAS was 85%+14% compared with 15%+10% after CAS. No periprocedural death occurred. No in-hospital and 30-days minor or major stroke/death was seen.

Conclusion: Our data suggest that percutaneous stenting of the carotid artery when a cerebral protection device is used is feasible and effective but not without technical difficulties and potential complications. We recommended CAS for high-risk patients for carotid endarterectomy, but this technique has a learning curve for those willing to perform the procedure with a low rate of complications.

MJIRI, Vol. 19, No. 3, 223-230, 2005.

Keywords: Carotid Stenosis , Stenting , IRAN , Protection Device , Angioplasty.

INTRODUCTION

Carotid endarterectomy (CEA) is the currently recommended standard for management of symptomatic^{1,3} and asymptomatic^{4,5} high grade extracranial carotid stenosis. Carotid artery stenting (CAS) has emerged as

a useful and potentially less invasive alternative to CEA.^{6,11} Recently published consensus statements^{12,13} have suggested that CAS may be preferred in specific subgroups of stenotic lesions, including recurrent carotid stenosis after previous CEA, stenosis in patients at high risk with significant medical comorbidity, anatomically inaccessible lesions above C₂ and radiation-induced stenosis. However, recent clinical trial reports^{14,15} have documented 30-day stroke and death rates of 10%, raising significant issues and concerns regarding the safety of this new technique. We began our experience with CAS in a prospective case series of patients that

*Assistant professor of Tehran University of Medical Sciences (Interventional Cardiologist)

**Assistant professor of Baghiatallah University of Medical Sciences (Interventional Cardiologist)

Tel-fax: 88029724, P.O.Box: 1411713138 (e-mail: Ali_Zeinali_Cardio@yahoo.com)

had some risk for CEA, to assess our in-hospital and short-term results.

PATIENTS AND METHODS

From December 2003 to December 2004 a total of 21 consecutive patients underwent percutaneous angioplasty and stenting of the extracranial carotid artery protected by embolic protection devices. Written, informed consent for intervention was obtained from all patients. The demographic and clinical data, angiographic evaluation, and neurological history characteristics of the study group are summarized in Table I and II.

Inclusion Criteria

Symptomatic patients with carotid artery stenosis >50% or asymptomatic patients with stenosis >80%. All patients had primary carotid stenosis and some of them had one or more medical comorbidities for CEA.

Exclusion Criteria

Thrombocytopenia, leucopenia, neutropenia, or GI bleeding in the previous 3 months, allergy to aspirin, clopidogrel, ticlopidine, angiographic appearance of fresh thrombus at the carotid lesion site; and angiographic appearance of carotid total occlusion.

Patient Assessment

Before treatment, all patients underwent careful neurological examination performed by an independent board-certified neurologist, echo/color flow Doppler (lesion site), cerebral CT scan or MRI, and angiographic evaluation.

Within 24 hours after the procedure and at the 30-day follow up, all patients underwent another neurological examination performed by the same independent neurologist and a complete echo/color flow Doppler evaluation. A post-procedure cerebral CT scan was performed only in patients with documented neurological complications.

Definitions

Procedural success after carotid stent deployment was defined as quantitative carotid angiography showing <30% residual diameter stenosis of all treated lesions without alterations in the intracranial circulation at the post-procedural angiographic examination (residual diameter stenosis was assessed by averaging at least 2 matched views on quantitative angiography). TIA was defined as a focal retinal or hemispheric event from which the patient made a complete recovery within 24 hours. Minor stroke was defined as a new neurological deficit that either resolved completely within 30 days or increased the NIHSS by >3. Major stroke was defined as

Table I: Clinical data and angiographic evaluation.

Clinical Data and Angiographic Evaluation	n	%
Population study	21	100%
Male	16	75%
Female	5	25%
Age (mean+SD), years	62+16	—
Angiographic evaluation		
Right carotid artery	9	45%
Left carotid artery	12	55%
Lesion length (mean) (range) mm	25(15 to 40)	—
Severity of stenosis (mean) (range) %	85% (70%-99%)	—
Bilateral carotid disease >70%	1	5%
Contralateral carotid occlusion	2	10%

Table I: Neurological history.

Neurological History	n	%
Symptomatic patients for the culprit lesion	13	60%
Asymptomatic patients for the culprit lesion	8	40%

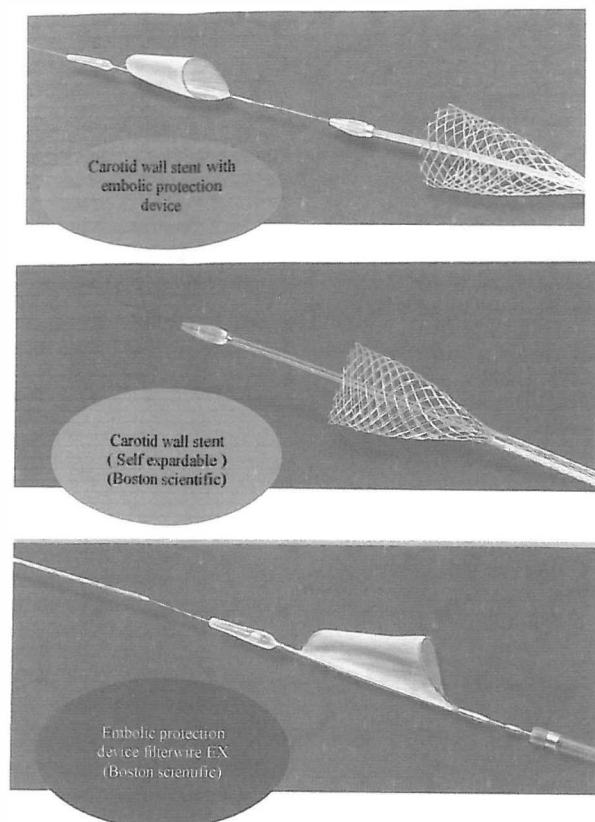


Fig. 1. The devices used.

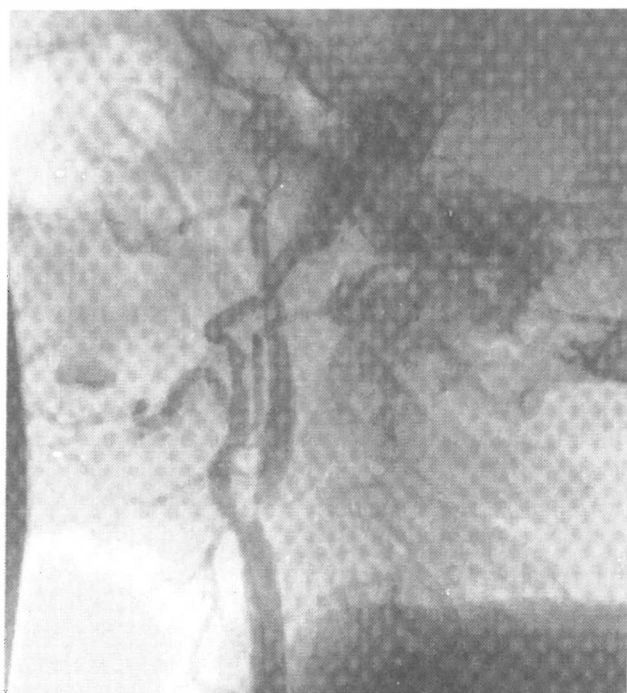

Fig. 2a. Left internal carotid (LICA) stenosis.

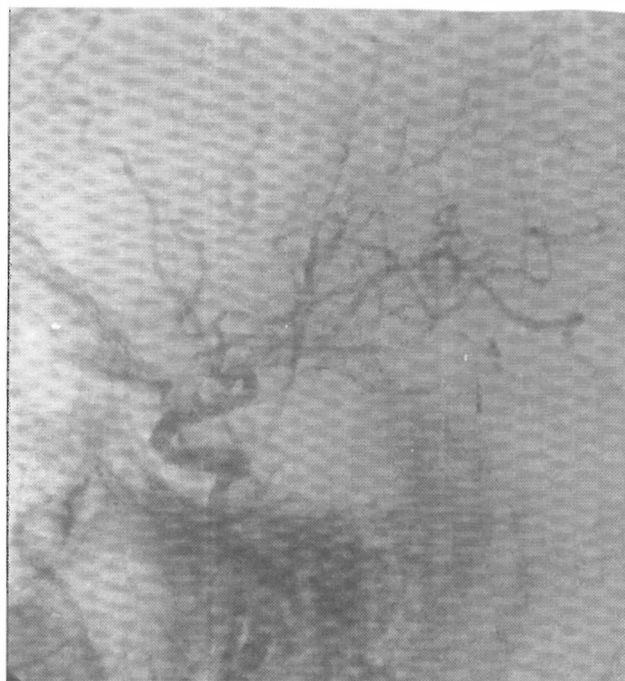


Fig. 2b. Brain flow before angioplasty.

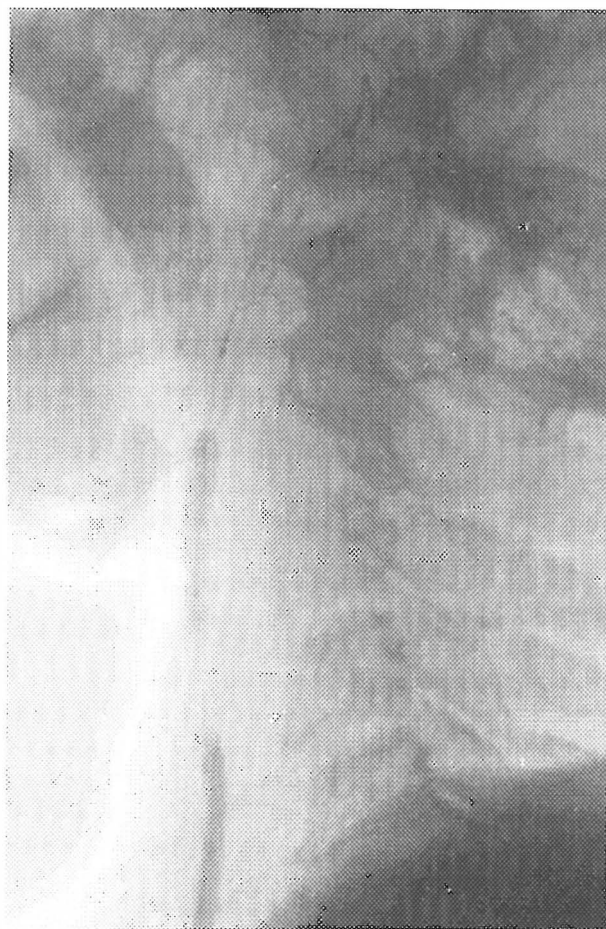


Fig. 2c. Filterwire with predilation of stenosis.

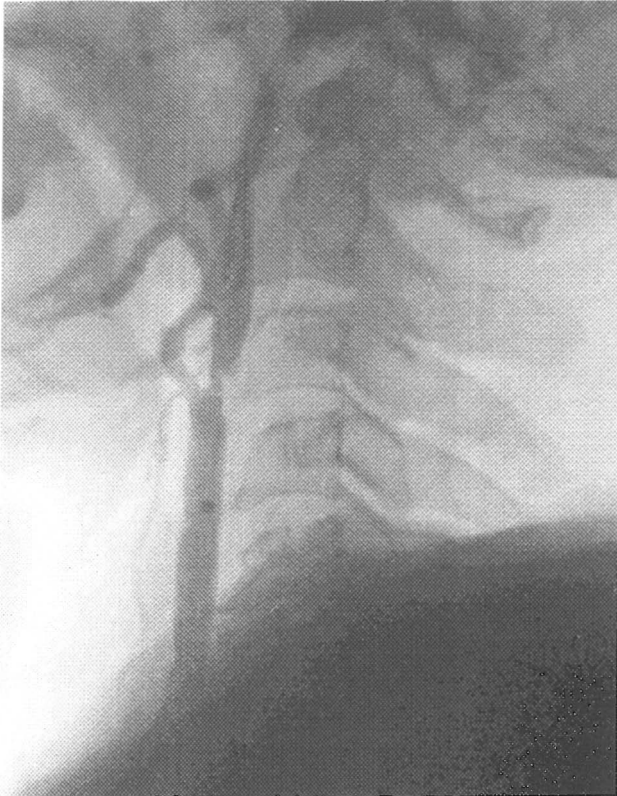

Fig. 2d. Stenosis after predilation.

a new neurological deficit that persisted for >30 days and increased the NIHSS by >4. Finally, fatal stroke was defined as death attributed to an ischemic stroke or intracerebral hemorrhagic stroke.

Medical Treatment

Before the procedure all patients were treated with ASA 325 mg/d and Plavix 75 mg/day at least 5 days before admission. During the procedure the mean dosage of Na-heparin used during the procedure was 100 u/kg. A mean of 1 mg atropine was given to patients before balloon inflation. Post-procedure plavix 75 mg/day was continued for at least 30 days and aspirin was continued indefinitely.

Carotid Artery Stenting Protocol and Devices

Local anesthetic (2% Lidocaine) was infiltrated at the access site. No sedation was given before or during the procedure. Intra-arterial blood pressure were monitored continuously, and neurologic status was assessed at regular intervals. ACT was maintained at 250 to 300 seconds.

Standard retrograde access was achieved through the common femoral artery, with a 7F vascular sheath. A 0.035

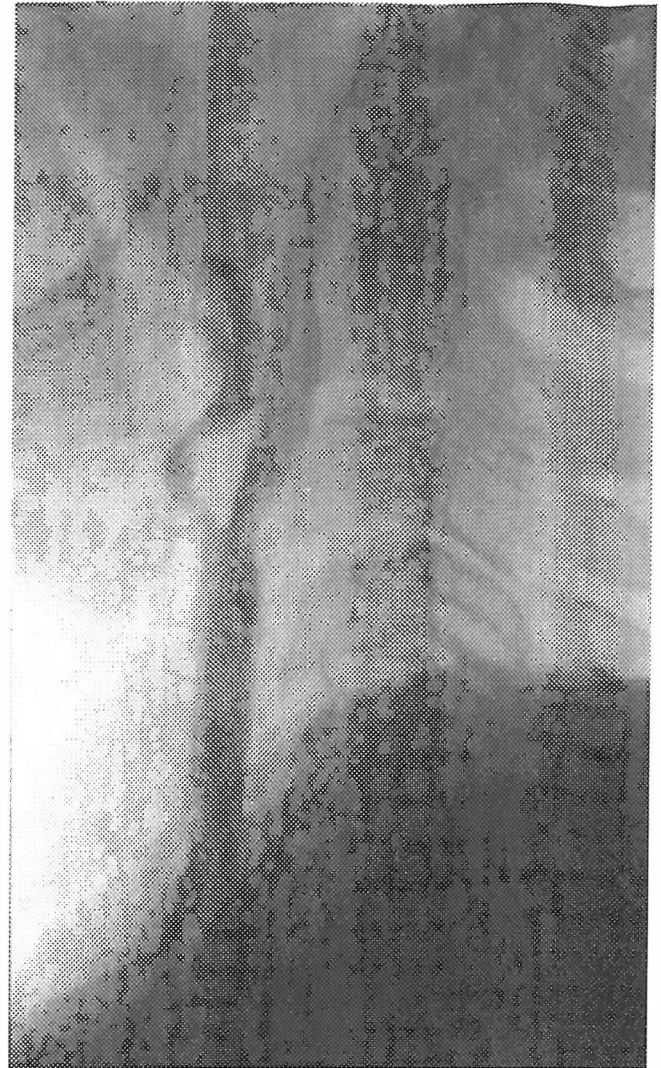

Fig. 2e. Undilated stent.

inch guide wire (175 cm) was used and the common carotid artery was selectively engaged directly by use of a primary guiding catheter. When use of primary guiding catheter was not possible because of particular anatomy of the Supra-Aortic vessels, we placed a stiff wire into the external carotid artery for positioning of a long sheath or guiding catheter into the common carotid artery. Then all patients underwent an angiographic examination of the culprit carotid lesion in 2 different projections (AP and lateral) and an angiographic examination of the intracranial circulation in the AP and lateral projection. The same angiographic checkup was performed at the end of the procedure to determine whether there was any variation in the intracranial blood flow. (Figure 1) Embolic protection devices were used for all patients. We used two models, Boston scientific filter wire EZ (15

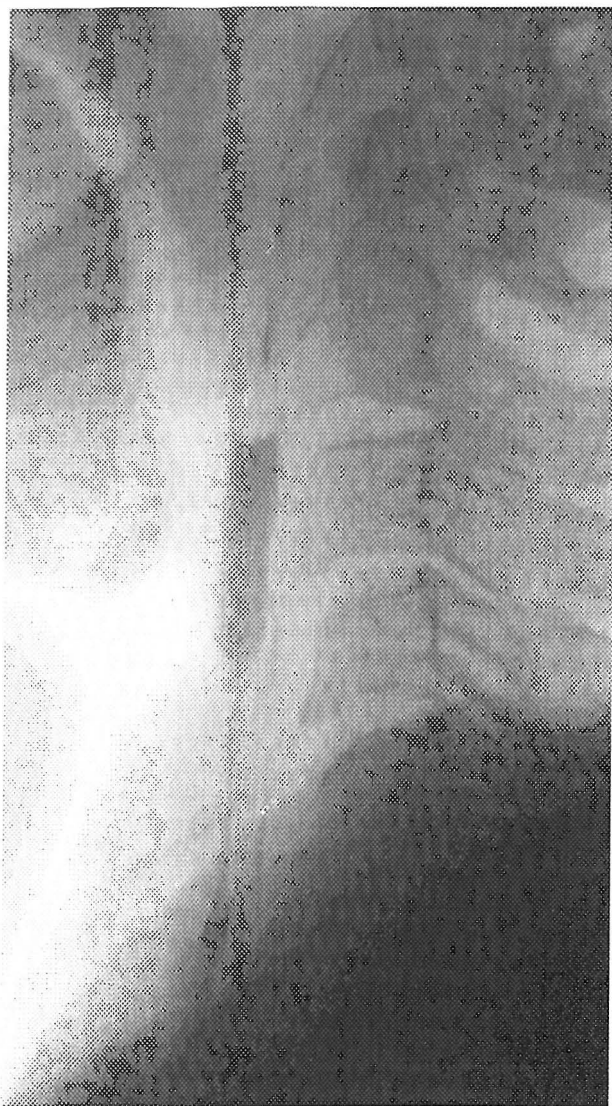

Fig. 2f. Post-dilation of stent.

cases) and filter device Accunet, Guidant (6 cases). (Figure 2)

Carotid Stenting

Carotid stenting was carried out by use of self-expandable stents in all cases. The stents were two types, Boston scientific carotid wallstent (15 cases) and Guidant Acculink (6 cases). Predilation was performed with coronary balloons in tight or subocclusive carotid stenosis. The predilation balloons were routinely undersized (Artery/balloon ratio: 1.8 to 1.5) to reduce vessel dissection and/or distal embolization. Stent placement was optimized with postdilation by using suitably sized balloons based on quantitative analysis of the vessel. During the postdilation phase, atropine (1 mg IV) was given to all patients before inflation to reduce the bradycardia and

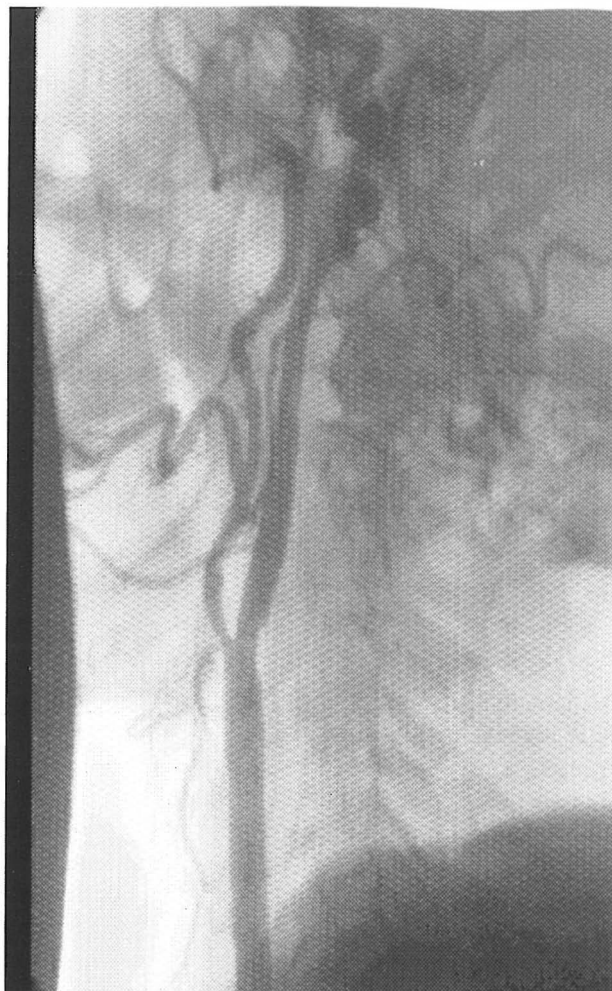

Fig. 2g. Final result.

hypotension potentially associated with carotid dilation.

Patients were transferred to the CCU for two days and were discharged on the third day. Neurologic examination was done pre-discharge with duplex and/or CT scan. A significant arterial access site complication was defined as any dissection, hematoma, pseudoaneurysm, arteriovenous fistula, or infection.

RESULTS

All CAS procedures were accomplished successfully (residual stenosis <30%). No contrast extravasation, arterial disruption, or subintimal dissections were observed. Residual stenosis after CAS did not exceed 20% in any case; mean residual stenosis was $15\% \pm 5\%$ (SD). Arterial access site hematoma was seen in two patients but no pseudo-aneurysm requiring blood transfusion or operative intervention was observed. Simple neurologi-

cal examination during the procedure and just after was normal. Mild headache and lightheadedness or slight discomfort in the neck and ipsilateral ear or mandible was observed in 5 patients, that resolved after some minutes. Significant bradycardia and one 3 second SA arrest were seen during balloon dilatation in 3 patients. Inhospital stroke and death was not seen. All patients were discharged two to four days after the procedure without any complications and complaints. All patients were re-examined in two weeks and after 30 days. Overall 30 day stroke was zero. One death occurred for one left main patient because of CABG in the third week after CAS. The reason of death was pump failure. Another patient was admitted in the second week because of CHF and was treated. In 30 days follow up there was no major or minor neurological complication such as TIA, retinal infarction or epileptic seizures.

DISCUSSION

Elective carotid artery stenting (CAS) may provide an alternative to carotid endarterectomy (CEA). Especially in those patients deemed to be at higher risk for endarterectomy. The short-term results derived from the largest series reported to date confirm other reports that suggest that the procedure can be performed with an acceptable complication rate.^{9,14,15} bility of CAS, however, has not been previously examined. CAS is now being performed in many centers around the world with low complication rates.^{14,16} Data from a worldwide registry reported a technical success rate of 98.4% and an overall minor stroke rate of 2.7%, a major stroke rate of 1.49% and a mortality rate of 0.88%.¹⁵ Although techniques vary slightly between operators and centers, these results are concordant with the findings of this study which suggest that CAS can be carried out with acceptable procedural outcomes.

The only randomized study to date, the Carotid and Vertebral Artery Transluminal Angioplasty Study (CAVATS), comparing carotid angioplasty (with bailout stenting in 26%) and CEA, demonstrated similar periprocedural stroke rates for the 2 groups (10% and 9.9% respectively).¹⁷ Meaningful comparison of the results of this present study with complication rates from published CEA studies is limited by differences in case mix, completeness of neurological evaluation, and nonstandardized end points. In particular, a large proportion of symptomatic patients in this study were NASCET ineligible.¹⁸ Nonetheless, stroke rates often CAS appear to be in a range similar to those observed in randomized trials of CEA for symptomatic patients. In NASCET, the 30-day minor stroke rate was 4%, major stroke rate was 1.6%, mortality

rate was 1.2% and overall stroke and death rate was 6.7% in patients with symptomatic carotid stenosis ($\geq 50\%$ diameter stenosis) randomized to the CEA arm.¹⁹ The veterans affairs cooperative study (VACS) also reported a 6.5% 30 day stroke and death rate,³ and the European carotid stent trial (ECST) reported an overall 7% major stroke and death rate in patients with symptomatic carotid stenosis.²⁰ For asymptomatic patients, comparison is particularly difficult. The Asymptomatic Carotid Atherosclerosis Study (ACAS) reported a periprocedural stroke and death rate of 2.3% in a lower-risk subset,²¹ and the asymptomatic surgical group in VACS suffered a 4.7% permanent stroke and death rate.⁴

In this study, we have shown that in Iran, for consecutive patients, it is possible to treat extracranial carotid atherosclerotic disease with percutaneous balloon angioplasty and stenting with elective carotid stenting. Many of our patients were thought to be very poor surgical candidates because of secondary conditions such as severe coronary artery disease, pulmonary disease, advanced age, severe cerebrovascular disease, or other factors that elevated the risk of surgery. Forty percent of the patients were referred by surgeons. Our patients had an average score of 3.5 on the Mayo Clinic carotid endarterectomy risk scale. In the Mayo Clinic series, the incidence of major complications (permanent stroke, MI or death) was 3.1% for grade 3 patients and 8.1% for grade 4 patients. With using of stenting,²² we were able to reduce balloon inflation times and minimize interruptions of cerebral blood flow to 15 to 30 seconds. This was well tolerated by patients, even those with contralateral carotid occlusions.

We accomplished carotid stenting in 21 consecutive procedures, with a technical success rate of 100%, mean residual stenosis immediately post-procedure was $15\% \pm 5$ (SD). This indicates the technical feasibility of CAS once appropriate training and experience with necessary catheter and guide wire skills are obtained. Future technical advances, will improve periprocedural outcomes for both asymptomatic and symptomatic patients.

Our good results concerning early and 30-day complications are because of the number of cases in comparison to national studies such as NASCET and ACAS studies. We are in the beginning of a long way and must add some patients to our study with long-term follow up; this can compromise our results with other multicentral studies. The potential advantages of CAS over CEA include avoidance of neck wound complications and cranial nerve palsies and a reduction in periprocedural MI. These results underscore the need to validate this less invasive procedure against CEA, the current "gold standard" surgically proven treatment for carotid

artery disease. Each institution must make decisions regarding continued use of CAS on the basis of their individual experiences.^{23,24}

CONCLUSION

This carefully conducted, prospective study has demonstrated that an experienced multidisciplinary group of operators can safely treat high risk patients with extracranial carotid disease with percutaneous techniques. This is a small, single-center series and requires confirmation in a larger, multicenter study. Ultimately, a randomized trial comparing percutaneous stenting with carotid endarterectomy may be indicated.^{25,26}

ACKNOWLEDGEMENTS

The authors wish to acknowledge the valuable contributions of Oscar A. Mendiz, MD, FACC, Head of the Department of Interventional Cardiology of Favaloro Foundation of Buenos Aires, Argentina and A. Rezaei, MD, Interventional Department of Stafford University, USA, for their assistance for two carotid stenting workshops in Tehran Heart Center.

REFERENCES

1. North American Symptomatic Carotid Endarterectomy Trial collaborators: Beneficial effect of carotid endarterectomy in symptomatic patients with high-grade carotid stenosis. *N Engl J Med* 325: 445-53, 1991.
2. European Carotid Surgery Trialists' Collaborative Group: MCR European Carotid Surgery Trial: Interim results for symptomatic patients with severe (70-99%) or with mild (0-29%) carotid stenosis. *Lancet* 337: 1235-43, 1991.
3. Mayberg MR, Wilson SE, Yatsu F, VA Symptomatic Carotid Stenosis Group: Carotid endarterectomy and prevention of cerebral ischemia in symptomatic carotid stenosis. *JAMA* 266: 3289-94, 1991.
4. Hobson RW, Weiss DG, Fields WS, Goldstone J, Moore WS, Towne JB, et al and the Veterans Affairs Cooperative Study Group: Efficacy of carotid endarterectomy for asymptomatic carotid stenosis. *N Engl J Med* 328: 221-7, 1993.
5. Executive Committee for the Asymptomatic Carotid Atherosclerosis study: Endarterectomy for asymptomatic carotid stenosis. *JAMA* 273: 1421-8, 1995.
6. Theron J, Raymond J, Casasco A, Courtheoux F: Percutaneous angioplasty of atherosclerotic and postsurgical stenosis of carotid arteries. *Am J Neuroradiol* 8: 495-500, 1987.
7. Roubin GS, Yadav S, Iyer SS, Vitek J: Carotid stent-supported angioplasty: a neurovascular intervention to prevent stroke. *Am J Cardiol* 78 (suppl 3A): 8-12, 1996.
8. Diethrich EB, Ndiye M, Reid BD: Stenting in the carotid artery: initial experience in 110 patients. *J Endovasc Surg* 3: 42-62, 1996.
9. Yadav JS, Roubin GS, Iyer S, Vitek J, King P, Jordan WD, et al: Elective stenting of the extracranial carotid arteries. *Circulation* 95: 376-81, 1997.
10. Hobson RW, Goldstein JE, Jamil Z, et al: Carotid restenosis: operative and endovascular management. *J Vas Surg* 29: 228-38, 1999.
11. Hobson RW, Lal BK, Chakhtoura EY, Goldstein J, Kubicka R, Haser PB, et al: Carotid artery closure for endarterectomy dose not influence results of angioplasty stenting for restenosis. *J Vas Surg* 35: 435-8, 2002.
12. Bettmann MA, Katzen BT, Whisnant J, and Co-chairs, American Heart Association Science Advisory Committee: Carotid stenting and angioplasty: a statement for healthcare professionals from the councils on cardiovascular radiology, stroke, cardiothoracic and vascular surgery, epidemiology and prevention, and clinical cardiology, and the American Heart Association. *Stroke* 29: 336-48, 1998.
13. Veith FJ, Amor M, Ohki T, Beebe HG, Bell PR, Bolia A, et al: Current status of carotid bifurcation angioplasty and stenting based on a consensus of opinion leaders. *J Vas Surg* 33 (2 suppl): S 111-6, 2001.
14. Henry M, Amor M, Masson I, et al: Angioplasty and stenting of the extracranial carotid arteries. *J Endovasc Surg* 5: 293-304, 1998.
15. Wholey MH, Wholey M, Mathias K, et al: Global experience in cervical carotid artery stent placement. *Cathet Cardiovasc Interv* 50: 160-167, 2000.
16. Mathias K, Jager H, Sahl H, et al: Interventional treatment of atherosclerotic carotid stenosis (in German). *Radiology* 39: 125-134, 1999.
17. Brown M: Results of the carotid and vertebral artery transluminal angioplasty study (CAVATAS). *Cerebrovasc Dis* 8 (suppl 4): 21, abstract, 1998.
18. North American Symptomatic Carotid Endarterectomy Trial Collaborates: Beneficial effects of carotid endarterectomy in symptomatic patients with high-grade carotid stenosis. *N Engl J Med* 325: 445-453, 1991.
19. Barnett HJ, Taylor DW, Eliasziw M, et al: Benefit of carotid endarterectomy in patients with symptomatic moderate or severe stenosis: North American Symptomatic Carotid Endarterectomy Trial Collaborates. *N Engl J Med* 339: 1415-1425, 1998.
20. Farrel B, Fraser A, Sandercock P, Slattery J: Randomised trial of endarterectomy for recently symptomatic carotid stenosis: Final results of the MRC European Carotid Surgery Trial (ECST). *Lancet* 351: 1379-1387, 1998.
21. Executive Committee for the Asymptomatic Carotid Atherosclerosis Study: Endarterectomy for asymptomatic carotid artery stenosis. *JAMA* 273: 1421-1428, 1995.
22. Sundt TM JR, Meyer FB, Piepgras SG, Fodee NC,

- Ebersold NJ, Marsh WR: Risk factors and operative results. In: Meyer FB, (ed.) Sundt's Occlusive Cerebrovascular Disease. 2nd. ed., Philadelphia, Pa: W.B., Saunders Co., pp. 241-247, 1994.
23. Roubin GS, New G, Iyer SS, Vitek JJ, Al-Mubarak N, Liu MW, Yadav J, Gomez C, Kuntz RE: Immediate and late clinical outcomes of carotid artery stenting in patients with symptomatic and asymptomatic carotid artery stenosis: a 5-year prospective analysis. *Circulation* 103: 532-537, 2001.
24. Wholy MH, Al-Mubarak N, Wholey MH: Update review of the global carotid artery stent registry. *Catheter Cardiovasc Interv* 60(2): 259-66, 2003.
25. Cremonesi A, Manetti R, Setacci F, Setacci C, Castriota F: Protected carotid stenting: clinical advantages and complications of embolic protection devices in 442 consecutive patients. *Stroke* 34(8): 1936-41, 2003.
26. Kunze AK, Ringleb PA, Hacke W, Hennerici M, Allenberg JR, Maurer PC, Zeumer H, Jansen O: The space study (Stent-Protected Percutaneous Angioplasty of the Carotid vs. Endarterectomy). 28th International Stroke Conference of the American Stroke Association, Phoenix, USA, February 22-26, 2004.