

# EVALUATION OF CRANIALIZATION TECHNIQUE IN THE TREATMENT OF FRONTAL SINUS FRACTURES

I. LOTFINIA, M.D.,<sup>1</sup> G. SHOKOUHI, M.D.,<sup>2</sup> F. SALEHPOOR, M.D.,<sup>3</sup>  
S. BABOLI, M.D.,<sup>4</sup> AND J. TOTONGEE, M.D.<sup>5</sup>

*From the Departments of Neurosurgery and Otolaryngology, Tabriz University of Medical Sciences,  
Tabriz, I.R. Iran.*

## ABSTRACT

Frontal sinus fractures are of surgical importance because of the microbial flora covering the frontal air sinus and its proximity with the duramater and brain. There is an increased risk of meningitis when fracture of the posterior wall of the frontal sinus is associated with a dural tear. In this condition, communication occurs between the contaminated space of the air sinus and the intracranial space, which may be concurrent with cerebrospinal fluid (CSF) leakage.

Non-depressed fracture of the posterior wall of the frontal sinus per se generally doesn't warrant surgical repair, but in some cases when conservative therapy fails to manage CSF leakage and when there is severe injury to the posterior wall of the sinus or to the sinus drainage duct, surgical treatment is warranted.

Cranialization is the surgical procedure for such patients in whom communication between the frontal air sinus and outside space is cut off and the air sinus space is integrated with the intracranial space. In this study, we evaluated 29 patients with frontal region fracture who underwent cranialization performed by a single surgery team. Of these patients, 89.7% were male and 10.3% were female. The most common cause of injury was found to be vehicle accident trauma (65.5%). These patients were also seen to have concurrent injuries involving the brain parenchyma, cranial nerves (II and III), and pneumocephalus. Post-operative complications included rhinorrhea, CSF leakage from the wound, meningitis and superficial infection of the site of surgery. All these complications improved with conservative therapy.

In general, in cases of severe injuries to the posterior wall of the frontal air sinus with nasofrontal duct injury, cranialization is an appropriate procedure. In these patients, in order to reduce complications it is essential that particular attention be paid to the repair of the damaged duramater and to the closure of the nasofrontal duct.

*MJIRI, Vol. 19, No. 3, 231-236, 2005.*

**Keywords:** Cranialization, Frontal sinus, Traumatic rhinorrhea.

## INTRODUCTION

Fractures involving the frontal region as well as the frontal sinus are relatively common injuries occurring in facial trauma, the incidence being 5-30% of all facial

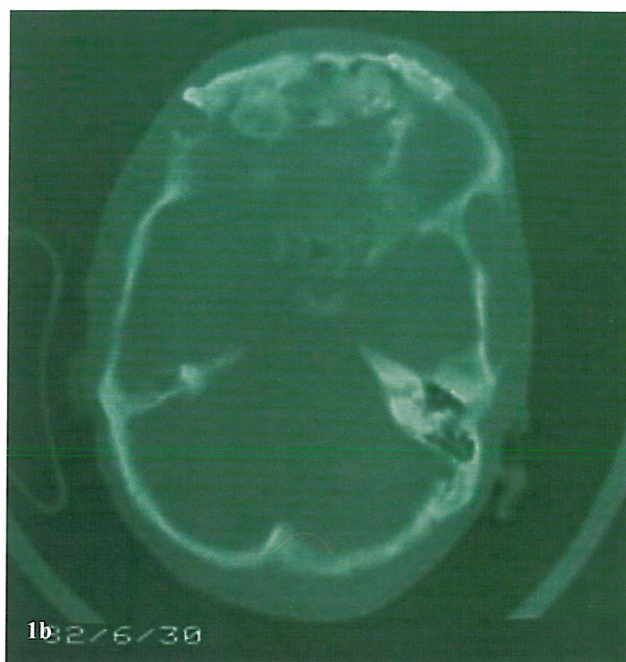
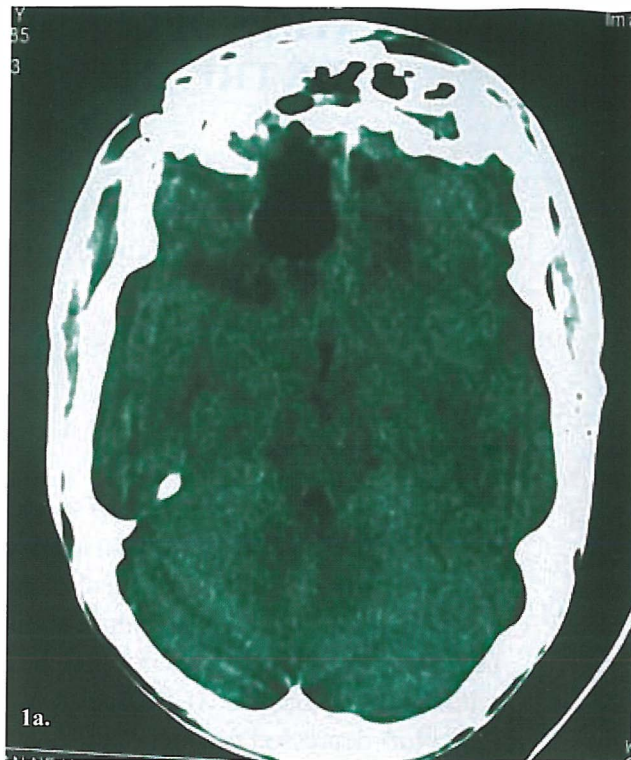
1- Assistant professor of neurosurgery  
2- Assistant professor of neurosurgery  
3- Associate professor of neurosurgery  
4- Resident of neurosurgery  
5- Assistant professor of otolaryngology, Department of Otolaryngology-Head and Neck Surgery.

trauma.<sup>1,9,23</sup> These fractures may involve the anterior, posterior, or both walls of the sinus. Appropriate management of frontal sinus fractures has been a matter of debate.<sup>1,2,3,6,7,8,12,14,20,21,25</sup>

Various techniques are used to manage different types of these fractures. In view of the fact that these fractures may be associated with intracranial injuries (12-17% of the cases),<sup>1</sup> as well as other organ injuries that necessitate more prompt treatment,<sup>15</sup> management of the fractures may be delayed. Due to the proximity of the sinus to the intracranial cavity frontal sinus fractures may be associated with serious consequences, and obstruction of the sinus drainage duct (nasofrontal duct) can result in sequela, which may appear long after the fracture.<sup>15</sup> When fractures occur in the posterior wall of the sinus, resulting in dural tears, even in the absence of an open wound, the fracture is termed open owing to the communication between the intracranial and extracranial space within the sinus cavity. In these cases, there exists the possibility of serious complications such as meningitis and even mortality. The purpose of this paper is to discuss the indication for the cranialization procedure along with findings obtained with this technique.

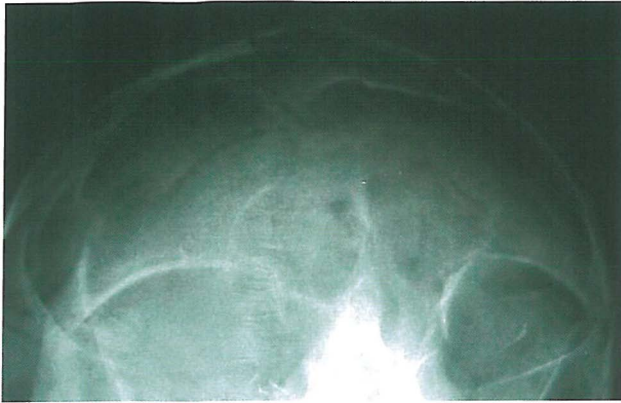
**PATIENTS AND METHODS**

Over a period of 3 years from 01-03-2000 to 01-03-2003, of all trauma patients presenting at the medical centers affiliated with the University of Tabriz 29 cases underwent cranialization on account of having suffered severe damage to the frontal sinus with its posterior wall fracture accompanied by likely nasofrontal duct injury and dural tears. In all patients, following systemic and neurological examination, brain axial computed tomography (CT scan) without contrast and with bone window was performed (Fig. 1 a and b). In patients not requiring emergency treatment, skull X-ray (anterior-posterior and lateral) was also taken (Fig. 2 a and b). In patients with exposed brain and in those with associated intracranial hematoma with decreased consciousness emergency surgical operation was performed, the rest being operated electively. In this procedure the patient was made to lie in the supine position with the head fixed on the head ring in its neutral position. In 6 cases with extensive wounds in the forehead on the sinus, surgery was performed in the same site and in patients without wounds or with small wounds, a bicoronal incision was made on the back of the hair-line. The sinus was exposed in most of the cases by removing fractured bone fragments. In others where



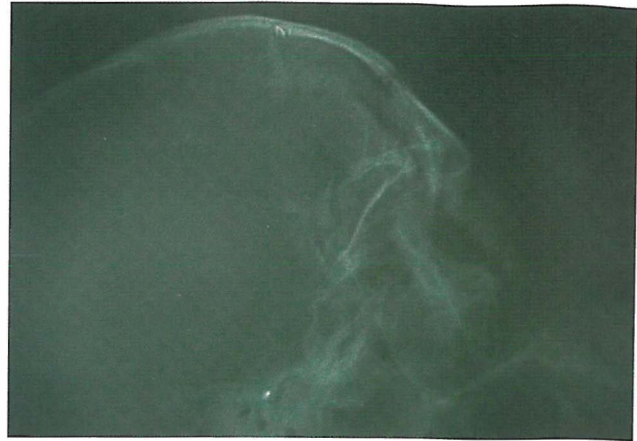
**Fig. 1.** Axial CT scan of a patient with severe frontal sinus injury (a) and bone window (b).

removal of bone fragments was not possible trephining adjacent to the sinus was performed to enable fragment removal. Next both the anterior and posterior walls of

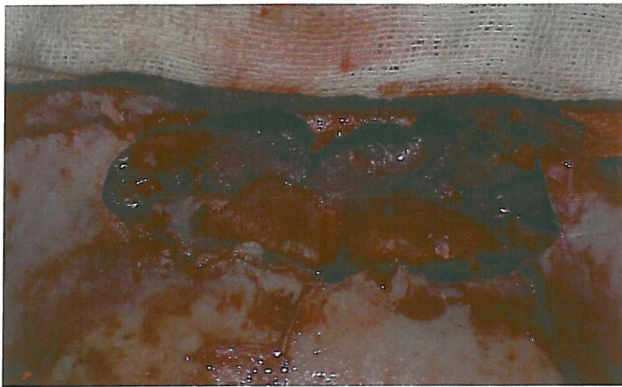


2a

Fig. 2. Radiography of a patient with severe frontal sinus injury; AP (a) and lateral view (b).

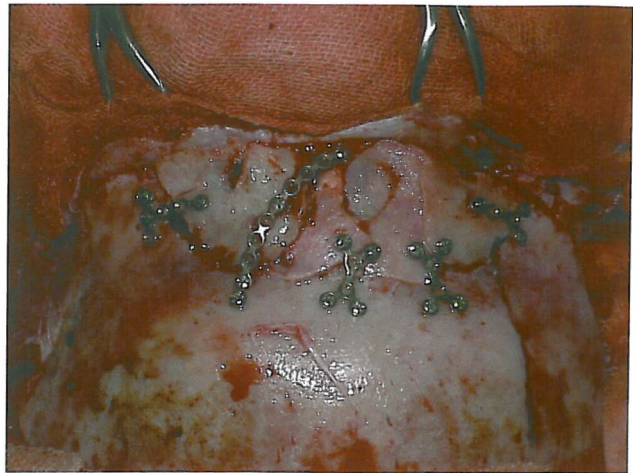


2b



3a

Fig. 3. Nasofrontal ostium obliterated with muscle (a) and anterior sinus wall repaired with miniplate and screw using bone fragments (b).



3b

the sinus were removed. In cases where there wasn't enough space for brain and dural repair, an adequate craniotomy was performed.

After that the sinus mucosa was removed carefully from the remaining area including the nasofrontal ostium. The area around the ostium or nasofrontal canal was decorticated with a rotating cutting burr and plugged using pieces of temporalis muscle and associated fascia (Fig. 3a). In patients with brain injury or dural tears, subsequent to measures required for brain repair and a watertight dural closure, only the anterior table of the frontal sinus was reconstructed with a mini-plate and screw by using bones obtained from the damaged anterior and posterior frontal sinus table (Fig. 3 b).

Ceftriaxone (1.5 gram every 8 hours in adults) was administered and continued for one week after the surgery or until no signs of infection were evident. During

surgery, the sinus and removed bone fragments were irrigated with serum containing gentamicin. Patients were monitored clinically for 7 to 18 months (average 14.2 months). Anterior-posterior and lateral skull X-rays (Fig. 4 a and b), and axial brain CT scans without contrast were performed in all the cases. An ENT specialist routinely evaluated all the patients from the second to the fourth week for signs of sinusitis and the presence of mucocele and postnasal discharge. Patients with headache or nasal discharge were re-examined by the ENT specialist.

## RESULTS

Of the 29 patients 89.7% were male and 10.3% were female. The patients ranged in age from 11 to 75 years, the mean age being 31.5 years old. The most common

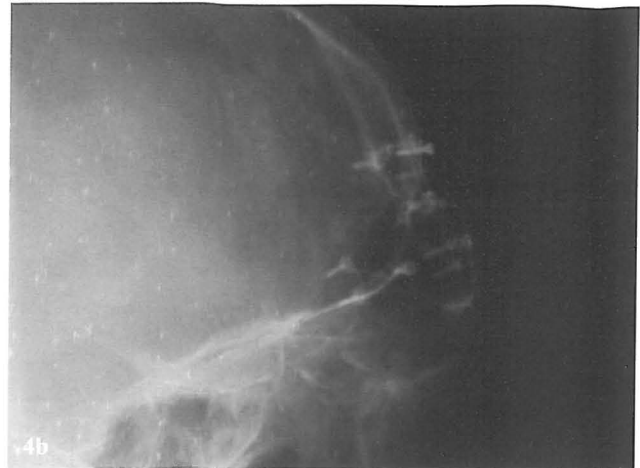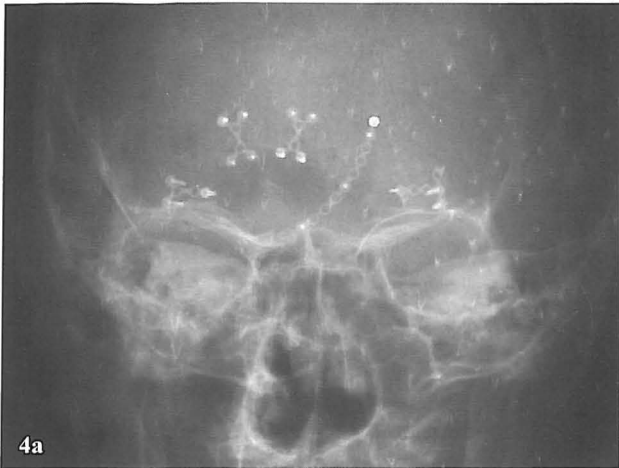


Fig. 4. Postoperative skull radiography, AP (a) and lateral (b).

cause of injury was vehicle accident trauma (65.5%) followed by falling from heights (17.5%) and direct trauma (17.5%). 55% of cases had a wound on the frontal region, extending to the subperiosteum.

The majority (93.1%) of the patients had concurrent brain injury. The most common injury was brain contusion (51.7%) followed by epidural hematoma, subdural hematoma, subarachnoid hemorrhage, intracerebral hematoma and brain edema. In 65.5% of the patients pneumocephalus was seen in preoperative CT scans. 25 cases (86.2%) had basal fracture in the anterior fossa. Most cases had a combination of these injuries. Based on the Glasgow coma scale (GCS), the degree of brain injury was severe in 3 (GCS: 3-8), moderate in 15 (GCS: 9-12) and mild in 11 cases (GCS: 13-15). Among cranial nerve injuries, unilateral involvement of the optic nerve (II) and oculomotor nerve (III) occurred in 4 (13.7%) and 2 cases (6.9%) respectively. Patients were hospitalized for 8-29 days (average hospitalization was 11.6 days).

After surgery and during hospitalization, there was CSF discharge from the operation site in one case and rhinorrhea in another case; for both, conservative treatment involving semi-sitting position in bed, and administration of lasix (1 mg/kg/d) and acetazolamide (25 mg/kg/d) was initiated. Both complications were controlled without further surgery (the first patient in 4 days and the second patient in 6 days). The second patient developed meningitis one week after discharge, and CSF examination revealed pneumococcus. Drug therapy was initiated and at 15-month follow up no problems were seen. Superficial infection and inflammation of the surgical site were observed in one patient, which were managed with drug therapy. Cosmetically, all of the patients were in appropriate condition, except for cutaneous

wound scarring in patients with open wounds. The forehead bone did not appear unsightly. Despite complaints from some patients of intermittent headache for several weeks, no mucocele and/or other complications associated with the frontal sinus were revealed on the ENT examination.

#### DISCUSSION

As discussed in the introduction, frontal sinus fractures secondary to facial trauma are relatively common injuries, and the appropriate treatment in these fractures hasn't been determined.<sup>1,2,3,6,7,12,14,20,21,25</sup> The critical factors in the determination of an appropriate treatment algorithm for these fractures are their location, presence and degree of fractured fragments displacement, status of the nasofrontal duct and the degree of injury to the duramater and brain.<sup>13,18,19,20,22</sup>

Anterior wall of sinus fractures without significant displacement are best handled conservatively.<sup>11,16,23</sup> Although some authors believe that these fractures should be surgically treated to avoid the high risk (18.2%) of complications from conservative treatment,<sup>25</sup> surgery is indicated only when there is a displaced anterior wall fracture and intact nasofrontal duct and that too for cosmetic reasons.<sup>2,4,21</sup> The fracture is fixed after reduction.<sup>24</sup> However, more aggressive treatment is suggested if there is anterior wall injury with nasofrontal duct injury.<sup>20,21</sup> Radiography or even CT scans may not clearly define fractures or injuries to the nasofrontal duct; still, some radiographic evidence may be helpful in demonstrating the nasofrontal duct status. Some authors have suggested that anterior wall fracture alone and transverse fractures of the posterior and anterior wall above the

floor of the sinus are usually without concurrent nasofrontal duct injury<sup>1</sup> but in fractures involving the base of the frontal sinus or those associated with fracture of the anterior ethmoid complex, the possibility of nasofrontal duct injury is high and thus warrants more aggressive treatment.<sup>20</sup> Evidence on brain CT scans are fractures involving the floor of the sinus, fractures of the nasoethmoidal complex, inferiorly located fractures of the posterior wall, or depressed fractures of the posterior wall which almost invariably signify injury to the frontal sinus drainage system.<sup>1</sup> The obstruction of which results in complications such as mucocele formation and chronic frontal sinusitis.<sup>20</sup> There are two treatment options for nasofrontal duct injury: the first option includes surgically enlarging the frontal sinus ostium and recess in an attempt to maintain patency; this is generally performed with stents or by reconstructing with a mucoperiosteal flap<sup>21</sup> (Sewall-Bodyen reconstruction). Since this option is prone to failure,<sup>20</sup> the second option, sinus drainage plugging, is used for fractures of the sinus associated with drainage tract injury, in which cases the frontal sinus must be excluded. There are two options

for exclusion of the frontal sinus, in both of which after entire mucosal exenteration of the sinus and drainage duct, the duct is obliterated with a variety of materials such as muscle and bone fragments.

In the obliteration procedure, after entire mucosal exenteration and ductal plugging, the sinus cavity is obliterated with autologous fat, muscle or bone.<sup>17</sup> Fat gives rise to fewer complications than other commonly used materials.<sup>10</sup> So fat is the most commonly used graft material for sinus obliteration.<sup>17</sup> This procedure is used in patients with anterior wall fracture associated with nasofrontal duct injury, which may be concurrent with mild or no posterior wall fracture. The second procedure, cranialization of the frontal sinus, is used when there are anterior and posterior wall injuries associated with displacement and / or CSF leakage,<sup>16</sup> severely damaged sinus<sup>14</sup> or severe posterior wall injury.<sup>9</sup> In this procedure, after entire exenteration of the sinus mucosa and plugging of the nasofrontal duct, the posterior wall of the sinus is removed and the anterior wall of the sinus is reconstructed with the bones obtained from the damaged anterior and posterior walls. For nasofrontal duct

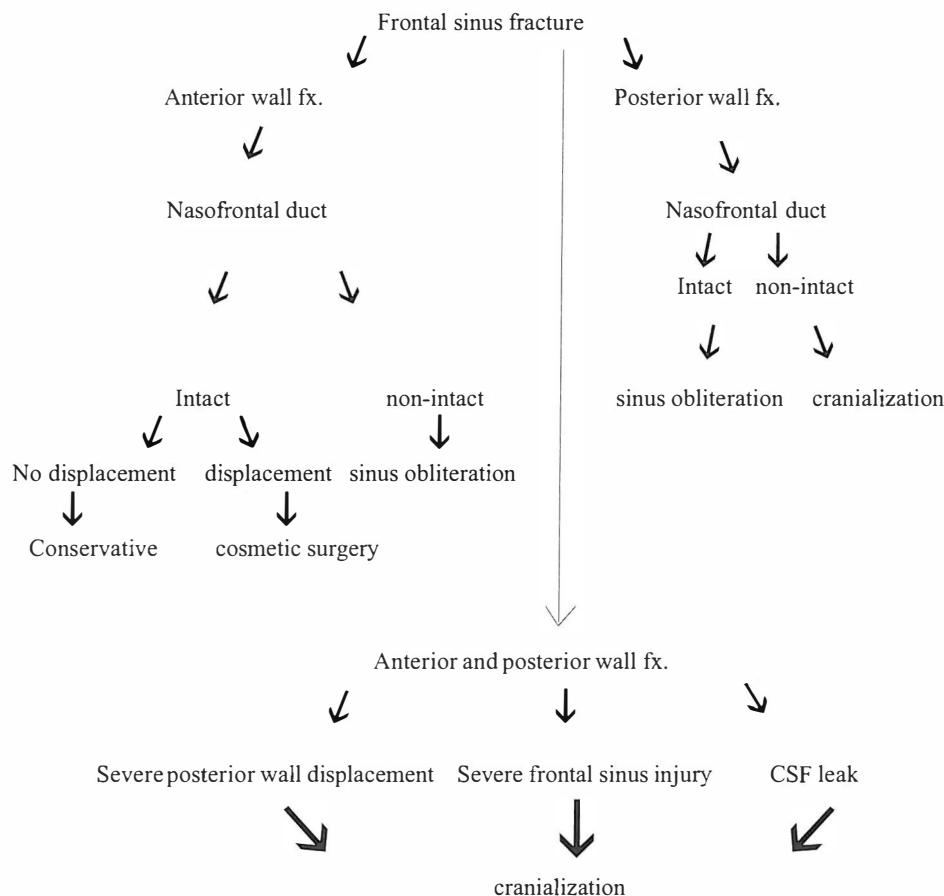


Fig. 5. The treatment approach for frontal sinus fractures.

plugging, fascia, muscle, bone or pediculated pericranial flap can be used. Being well vascularized, the flap reduces the risk of infection in an often contaminated surgical field.<sup>17</sup> The other important point is, mucosa in the human frontal sinus is able to invaginate into pits of the inner cortex and failure to remove mucosa from these pits can lead to entrapment and late formation of mucocoeles.<sup>2</sup> Due to this reason it is recommended that the wall be carefully cleaned of any mucous remnants by means of a polishing burr.<sup>5</sup>

The treatment approach can be summarized in the algorithm shown in Fig. 5.

### CONCLUSION

Cranialization is an appropriate option for treatment of patients with frontal sinus injury associated with posterior wall fracture and nasofrontal duct injury. This procedure will have few complications if entire mucosal exenteration of the sinus and nasofrontal duct is performed carefully and the nasofrontal duct is plugged appropriately. To reduce the likelihood of complications in these patients, watertight repair of the duramater is advised. In cases of postoperative CSF leakage, more aggressive management is warranted.

### REFERENCES

1. Andrews A, Chowdhury K: Frontal sinus fractures: Advances in treatment. *Otolaryngology, Head and Neck Surgery* 2 (129): 66-69, 2003.
2. Caroli E, Rocchi G, D'andrea G, Delfini R: Management of the entered frontal sinus. *Neurosurg Rev* 27: 286-288, 2004.
3. Day TA, Meehan R, Stuker FJ, Nanda A: Management of frontal sinus fracture with posterior table involvement: a retrospective study. *J Craniomaxillofac Trauma* 4(3): 6-9, 1998.
4. De ponte F, Bottini D, Sassano P, Rinna C: Bicornal approach in the management of frontal sinus fractures. *Minerva Stomatol* 44(11): 507-14, 1995.
5. El khatib K, Danino A, Mal ka G: Frontal sinus: a culprit or a victim? A review of 40 cases. *Journal of Cranio-Maxillofacial Surgery* (32): 314-317, 2004.
6. Gabrielli R, Gabrielli C, Hochuli-Vieira E, Pereira-Fillho A: Immediate reconstruction of frontal sinus fractures: review of 26 cases. *Journal of Oral and Maxillofacial Surgery* (62): 582- 86, 2004.
7. Gerbino G, Roccia F, Benech A, Caldarelli C: Analysis of 158 frontal sinus fractures: current surgical management and complications. *Journal of Cranio-Maxillofacial Surgery* (28): 133-139, 2000.
8. Kalavrezos N: Current trend in the management of frontal sinus fracture. *Injury Int J Care Injured* (35): 340-46, 2004.
9. Klotch DW: Frontal sinus fractures: anterior skull base. *Facial Plast Surg* 16(2): 127-34, 2000.
10. Larrabee WF Jr, Travis LW, Tabb HG: Frontal sinus fractures-their suppurative complications and surgical management. *Laryngoscope* 90 (11): 1810-13, 1980.
11. Levine S, Rowe L, Keane W, Atkins J: Evaluation and treatment of frontal sinus fracture. *Otolaryngol Head Neck Surg* 95(1):19-22, 1986.
12. Loannides C, Freihofer H, Vrieus J, Frien J: Fractures of the frontal sinus: a rationale of treatment. *Br J Plast Surg* 46(3) 208-14, 1993.
13. Loannides C, Freihofer H: Fractures of the frontal sinus: classification and its implication for surgical treatment. *Am J Otolaryngol* 20(5): 273-80, 1999.
14. Luce E: Frontal sinus fractures: guidelines to management. *Plast Reconstr Surg* 80(4): 500-10, 1987.
15. McGrow-Wall B: Frontal sinus fractures. *Facial Plast Surgery* 14(1): 59-66, 1998.
16. Lakhani R, Shibuya T, Mathog R, Marks S, Burgio D, Yoo G: Titanium mesh repair of severely comminuted frontal sinus fracture. *Arch Otolaryngol Head Neck Surg* 127: 665-669, 2001.
17. Parhiscar A, Har-el G: Frontal sinus obliteration with the pericranial flap. *Otolaryngology Head and Neck Surgery* (124): 3304-307, 2001.
18. Rohrich R, Hollier L: Management of frontal sinus fractures, changing concepts. *Clin Plast Surg* 19(1): 219-232, 1992.
19. Rohrich R, Hollier L: The role of the nasofrontal duct in frontal sinus fracture management. *J Craniomaxillofac Trauma* 2(4): 31-40, 1996.
20. Smith T, Han J, Todd L, Rhee J: Endoscopic management of the frontal recess In frontal sinus fractures; a shift in paradigm. *Laryngoscope* 112(5): 784-790, 2002.
21. Smith T, Loehrl T, Rhee J: Treatment algorithm for endoscopic management of the frontal recess in frontal sinus fractures. *Operative Techniques in Otolaryngology-Head and Neck Surgery* 13(4): 281-86, 2002.
22. Stassen L, Maguinness A: A simple method of plate fixation of fractures of the frontal bone. *British Journal of Oral and Maxillofacial Surgery* 37: 438-39, 1999.
23. Tarik H, El-Bary A: Neurosurgical management of the frontal sinus. *Surg Neurol* 44:80-81, 1995.
24. Whited R: Anterior table frontal sinus fractures: *Laryngoscope* 89(12): 1951-5, 1979.
25. Xie C, Mehendale N, Barrett D, Bui C, Metzinger S: 30-year retrospective review of frontal sinus fractures: the charity hospital experience. *J Craniomaxillofac Trauma* 6 (1): 7-15, 2000.