

EVALUATION OF LABORATORY FINDINGS IN CHILDREN WITH WILSON'S DISEASE IN EMAM KHOMEINI HOSPITAL DURING 1994-2003

SHAHLA BAHREMAND, M.D.,* YAHYA AGHIGHI, M.D.,**
ZOHREH OLOOMI YAZDI, M.D.,*** HESHMAT MOAYERI, M.D.,¹
LALEH RAZAVI, M.D.,[#] AND MANSOUR NATEGHI, M.D.[#]

*From the *Pediatric Gastroenterology Ward, Emam Khomeini Hospital, Tehran University of Medical Sciences, the **Pediatric Rheumatology Ward, Emam Khomeini Hospital, Tehran University of Medical Sciences, the ***Pediatric Hematology Ward, Emam Khomeini Hospital, Tehran University of Medical Sciences, the ¹Pediatric Endocrinology Ward, Emam Khomeini Hospital, Tehran University of Medical Sciences, and the [#]Pediatric Ward, Emam Khomeini Hospital, Tehran University of Medical Sciences, Tehran, Iran.*

ABSTRACT

Wilson's disease is a rare but treatable condition with variable clinical presentations. Its diagnosis depends on a combination of clinical and laboratory findings. We evaluated the clinical and laboratory findings in children with Wilson's disease (WD).

Twenty-seven children (4-14 years, 59.2% male, 40.7% female) with confirmed WD were evaluated between 1994 and 2003 at Imam Khomeini Hospital.

Seventeen patients (64%) presented with liver abnormalities, 3(11%) with neurological features, 3(11%) with fulminant hepatic failure and 4(14%) were asymptomatic siblings of patients with WD. The presence of Kayser Fleischer rings, high urine copper excretion, low ceruloplasmin level, and elevated liver copper concentration were detected in 51.8%, 77.7%, 92.5% and 72.7% of patients respectively.

We emphasize on clinical findings together with one or more laboratory findings as a diagnostic guide in WD and also recommend evaluation of serum ceruloplasmin level and 24 hour urine copper excretion particularly when liver biopsy may not be obtained. *MJIRI, Vol. 18, No. 4, 327-330, 2005.*

Keywords: Wilson's disease, laboratory findings, children.

INTRODUCTION

Wilson's disease is an autosomal recessive disease with a prevalence in most populations of 1 in 30000.¹ It is clinically characterized by hepatic and neurological manifestations related to the accumulation of copper in the liver, lenticular nuclei and by Kayser Fleischer (KF) rings. The abnormal gene in Wilson's disease was assigned to the long arm of chromosome 13 and approximately 70 individual mutations have been identified in patients with Wilson's disease,^{2,3,4} which may in part explain the clinical heterogeneity of the disease. Diagnosis of Wilson's disease is usually straight-forward if

the clinical and laboratory findings such as typical hepatic and /or neurological symptoms and signs, KF rings, low ceruloplasmin concentrations and increased urinary copper excretion are present⁵ but they are not specific. Low ceruloplasmin levels may be seen in malnutrition and nephrotic syndrome and increased urinary copper excretion also may be seen in primary biliary cirrhosis or chronic active hepatitis. Furthermore, in patients with liver disease alone, KF rings are often absent and serum ceruloplasmin levels may be normal.⁶ In this paper, we evaluate children with Wilson's disease retrospectively to assess clinical and laboratory findings and emphasize on difficulties in diagnosis of this disease.

Lab Findings in Children with Wilson's Disease

PATIENTS AND METHODS

Medical records of children with a diagnosis of Wilson's disease from 1994 to 2003 at Imam Khomeini Hospital were reviewed retrospectively (a case series, descriptive study). All patients with initial diagnosis of chronic or acute liver disease or neurological abnormalities or acute hemolysis in the pediatric ward have been evaluated for Wilson's disease and those with a confirmed diagnosis of Wilson's disease entered in our study. The principal criteria used to establish a provisional diagnosis of Wilson's disease were hepatic and/or neurological abnormalities, the presence of KF rings, a low serum ceruloplasmin concentration (less than 0.2 gr/L) and a raised 24 hour urine copper excretion (>100 microgram/ 24 h).^{1,3} The diagnosis was confirmed by the finding of a high liver copper concentration (>250 microgram/ 1 gr. dry weight of liver, which was performed by PIXE method) when the liver biopsy might be obtained (absence of any coagulation abnormality).^{1,5} In patients with fulminant hepatic failure, presence of KF, family history of Wilson's disease led to the diagnosis. During the study, 27 patients with a confirmed diagnosis of Wilson's disease were found. Their age, sex, family history, presence of KF ring, 24 hour urine copper excretion, liver copper concentration, level of serum ceruloplasmin and presenting symptoms (hepatic or neurologic) were extracted from their medical records and then evaluated.

RESULTS

Twenty-seven patients with Wilson's disease were diagnosed between 1994 and 2003. Sixteen patients (59.2%) were boys and 11 (40.7%) were girls. The mean age was 9.51 ± 2.34 years and the age range was 4-14 years. Seventeen patients (62%) had a positive family history of Wilson's disease and 10 cases (38%) had a negative family history.

Seventeen patients (64%) presented with liver abnormalities, 3 (11%) with neurological features, 3 (11%) with fulminant hepatic failure (diagnosed by KF rings in 2 cases and positive family history in 1 case) and 4 (14%) were asymptomatic siblings of patients with Wilson's disease. KF ring had been seen in 14 patients (51.8%), high urine copper excretion (100 microgram) was seen in 21 patients (77.7%) and low serum ceruloplasmin levels were detected in 25 patients (92.5%). Elevated liver copper concentration (more than 5 times of normal values) were found in 16 cases (72.7%) and in 5 (18%) patients due to abnormal coagulation tests, liver biopsy was not accomplished. Liver biopsy findings included 4 (18%) patients with fibrosis, 7 (32%) with chronic active hepatitis and 11 (50%) cases with cirrhosis. (Table, Fig. 1, 2) None of our patients had cholestasis and in patients

with fulminant hepatitis, the diagnosis was made by physical examination (KF,..), and family history as the urine copper level was not reliable in these patients.

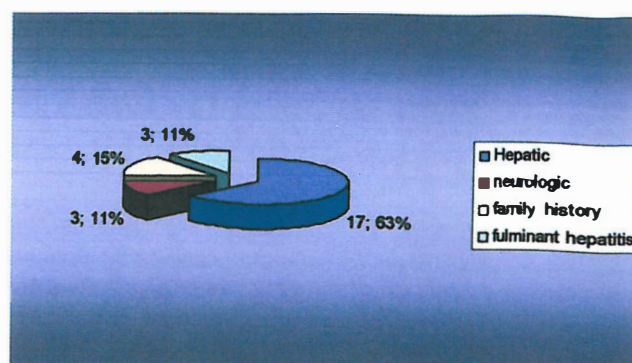


Fig. 1. Mode of presentation in pediatric patients with Wilson's disease in Emam Hospital during 1994-2003.

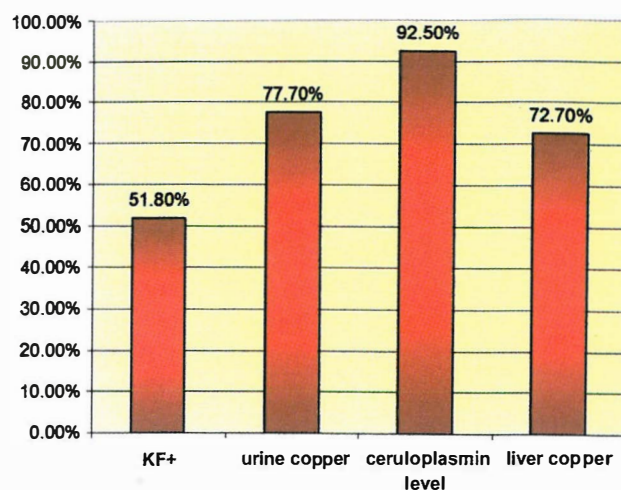


Fig. 2. Frequency of laboratory tests in pediatric patients in Emam Hospital during 1994-2003.

Unfortunately, patients with fulminant hepatic failure died. All other patients were treated with penicillamine which was well tolerated without any major complications.

DISCUSSION

According to Steindel et al's⁷ study on 55 cases with Wilson's disease, diagnosis relies on a careful clinical appraisal together with one or more laboratory findings. It was recommended that hepatic abnormalities provide the greater diagnostic difficulties, as in their study 90% of those with neurological presentation had KF and from 85% with low ceruloplasmin levels but with a liver presentation only 44% had KF and 60% reduced cerulo-

Table I. Characteristics of pediatric patients with Wilson's disease in Emam Hospital during 1994-2003.

Patient No.	Age at Diagnosis, Sex	Mode of Presentation	Low Ceruloplasmin Level (<.02g/L)	High Liver Copper(>250)	KF Ring	High Urine Copper (>100µg/24 h.)	Histology
1	4, M	Hepatic	+	+	-	-	CAH
2	6, F	Hepatic	+	+	-	+	Cirrhosis
3	6, M	Hepatic	+	+	+	+	Cirrhosis
4	7, M	Family history	+	+	-	+	Fibrosis
5	7.5, M	Hepatic	+	+	+	-	CAH
6	8, F	Fulminant hepatitis	+	Not done	+	-	-
7	8, M	Hepatic	+	-	-	+	CAH
8	8, F	Hepatic	+	+	-	-	CAH
9	8.5, M	Hepatic	+	+	+	+	Cirrhosis
10	9, M	Family history	-	-	-	-	Fibrosis
11	9, F	Fulminant hepatitis	+	Not done	+	+	-
12	9, M	Hepatic	+	+	+	+	Cirrhosis
13	9, F	Family history	+	+	-	+	Fibrosis
14	9.5, F	Hepatic	+	+	+	+	Cirrhosis
15	9.5, M	Hepatic	+	-	-	+	CAH
16	10, M	Neurologic	-	+	+	+	Cirrhosis
17	10, F	Family history	+	-	-	+	Fibrosis
18	10.5, M	Hepatic	+	+	+	+	CAH
19	11, F	Hepatic	+	Not done	-	+	-
20	11, M	Fulminant hepatitis	+	Not done	-	-	-
21	11, F	Neurologic	+	+	+	+	Cirrhosis
22	11.5, M	Hepatic	+	+	+	-	CAH
23	12, F	Hepatic	+	-	-	+	Cirrhosis
24	12, M	Fulminant	+	Not done	-	+	-
25	13, F	Hepatic	+	+	-	+	Cirrhosis
26	13, M	Neurologic	+	-	+	+	Cirrhosis
27	14, F	Hepatic	+	+	+	+	Cirrhosis

CAH: Chronic Active Hepatitis. M: male, F: female.

plasmin concentrations. In our study 55% (9 patients) of patients with hepatic presentation and all patients (100%) with neurological features had KF ring and low ceruloplasmin levels were seen in 25 patients (92.5%) [in all patients with neurological and acute hepatic failure and 90% of patients with liver disease.]. These findings are also compatible with Steindl's study.⁷ In our study elevated urine copper excretion was found in 17 cases (77.7%) and high liver copper concentration was detected in 16 patients (72.7%).

In 5 cases liver biopsy wasn't accomplished due to abnormal coagulation tests. In another study by Yucw

et al. in Turkey⁸ on 33 children with confirmed Wilson's disease, all patients had hepatic disease, with neurological involvement in 4 patients. High urinary copper excretion, elevated liver copper concentration, low serum ceruloplasmin levels and presence of KF ring were present in 100%, 88%, 82% and 63% of patients respectively. These findings also confirm our results.(Fig. 2).

62.9% of our patients had a positive family history and 4 of them were asymptomatic. These findings emphasize on the importance of screening tests in families of patients.^{9,10,11,12} In a study in Tehran University by Chavoshzadeh¹³ on 20 patients with Wilson's disease,

Lab Findings in Children with Wilson's Disease

elevated liver copper was seen in 17 patients and in another study in Pediatrics Medical Center¹⁴ high liver copper was detected in 19% of 31 patients with Wilson's disease.

According to references,^{4,15,16,17} we also consider liver biopsy with quantitation of copper as the gold standard for the diagnosis but as it may not be obtainable in patients with coagulation abnormalities, we recommend evaluation of serum ceruloplasmin levels and 24 hour urine copper excretion particularly when liver biopsy can't be performed. In Yucw's study⁸ and Farahmand's study¹⁸ in Pediatrics Medical Center, 24 hour urinary copper excretion was also recommended as the most sensitive diagnostic test. We also believe that Wilson's disease still remains on occasion a difficult diagnosis to establish and reliance must be placed on high index of clinical suspicion which will lead to the appropriate investigations. Recently, many investigations are being undertaken to apply genetic techniques such as haplotype analysis and analysis of mutations in the ATP7B gene in establishing the diagnosis of Wilson's disease.

ACKNOWLEDGEMENT

The authors wish to thank the attending staff of the pathology ward in Emam Khomeini Hospital.

REFERENCES

1. Sternlieb L: Perspectives on Wilson's disease. *Hepatology* 12: 1234-1239, 1990.
2. Ansari R, Malekzadeh R, Ebrahimi Daryani N, et al: Wilson's disease in Iran. *Arch Iran Med* 3: 114-123, 2000.
3. Sokol RJ, Narkewicz MR: Copper and Iron storage disorders. In: Suchy FJ, Sokol RJ, Balistreri WF: *Liver Disease in Children*. Williams & Wilkins. Philadelphia: pp. 595-640, 2001.
4. Shah AB, Chernov I, Zhang HT, et al: Identification and analysis of mutations in Wilson's disease gene (ATP7B): population frequencies, genotype- phenotype correlation and functional analyses. *Am Hum Genet* 61: 317-328, 1997.
5. Gow PJ, Smallwood KA, Angus PW, et al: Diagnosis of Wilson's disease: an experience over three decades. *Gut* 46(3): 415-423, 2004.
6. Sherlock SH, Dooley J: Wilson's disease. In: Sherlock SH, Dooley J, (eds.), *Disease of the Liver and Biliary System*. 10th ed, Oxford: Blackwell Science, pp. 417-426, 1997.
7. Steindl P, Ferenci P, Dienes HP, et al: Wilson's disease presenting with liver disease: a diagnostic challenge. *Gastroenterol* 113: 212-218, 1997.
8. Yucw A, Kocak N, Demir H, et al: Evaluation of diagnostic parameters of Wilson's disease in childhood. *Indian J Gastroenterol* 22(1): 4-8, 2003.
9. Nicoll DJ: Wilson's disease presenting in a family with an apparent dominant history of tremors. *J Neurol Neurosurg Psych* 70(4): 4-9, 2000.
10. Loudianos G, Gitlin JD: Wilson's disease. *Semin Liver Dis* 20(3): 353-64, 2000.
11. Prashanth LK, Taly AB, Sinha S, et al: Wilson's disease diagnostic errors and clinical implications. *J Neurol Neurosurg Psychiatry*. 75(6): 907-9, 2004.
12. Cauza E, Maier-Dobers Berger T, Polli C, et al: Screening for Wilson's disease in patients with liver disease by serum ceruloplasmin. *J Hepatol* 27 (2): 358-62, 1997.
13. Chavoshzadeh Z: Evaluation of liver copper in patients with Wilson's disease in 1994-2003 in Tehran University. Tehran Medical University, 2004.
14. Baghchehsara J: Wilson's disease in Pediatric Medical Center in 1993-1994. Tehran Medical University, 1995.
15. Yucw A, Kocak N, Demir H et al. Wilson's disease with hepatic presentation in childhood. *Indian Pediatr* 37(1): 31-6, 2000.
16. Yucw A, Kocak N, Demir H, et al: Wilson's disease with normal ceruloplasmin levels. *Turk Pediatr* 44(1): 99-102, 1999.
17. Balisteri WF: Metabolic liver disease. In: Behrman RE, Kilegman RM, Genson HB, (eds.), *Nelson Textbook of Pediatrics*. 16th ed. Philadelphia: W.B. Saunders, pp. 1209-1211, 2000.
18. Farahmand F: Comparison between urinary copper and liver copper in diagnosis of Wilson's disease in Pediatric Medical Center during 1997-98. Tehran Medical University, 1998.