




The effect of silicone gel versus contractubex gel on the upper-extremity postsurgical scars: A randomized, double-blinded, controlled trial

Seyed Esmail Hassanpour¹, Nazila Farnoush*¹ , Mohammad Yasin Karami², Alireza Makarem³

Received: 29 Oct 2019

Published: 29 Oct 2020

Abstract

Background: Wound healing is a process that has three overlapping inflammatory, proliferative, and reconstruction phases. Silicone gel and Contractubex (onion extract gel) are two main topical agents used for the prevention and treatment of hypertrophic scars. This clinical trial study aimed to evaluate the efficacy and safety of onion extract and silicone gel on hypertrophic scars of the upper extremity and compare it to non-treated patients.

Methods: This randomized, double-blind, parallel, clinical trial was done on 120 male patients who had undergone upper extremity sharp injury repair. Patients were assigned to three groups, i.e., Silicone gel (Kelo-cort™; WA, USA) (group 1; 40 patients), Onion extract (Contractubex™, Merz Pharma, Frankfurt, Germany) gel (group 2; 40 patients), and No Intervention (group 3; 40 patients), using drawing sealed envelopes and a computer-based table of randomization. Data were recorded using the Vancouver scale in each visit by two surgeons who were blinded to the study groups. IBM SPSS Statistics for Windows, Version 22.0. (Armonk, NY: IBM Corp). Data were compared using the ANOVA test. A P-value of less than 0.05 was considered statistically significant.

Results: Vascularity ($p=0.200$), pliability ($p=0.058$), pigmentation ($p=0.701$), and height ($p=0.438$) as subjective scar parameters were approximately similar in post-upper extremity sharp injury wound hypertrophic scar among the three groups.

Conclusion: Vascularity, pliability, pigmentation and height, as subjective scar parameters, were not statistically different in post-upper extremity sharp injury wound hypertrophic scar among the groups. Even though onion extract gel and Silicone gel show preventive effects in the literature, especially in burns wounds, further studies are recommended to be conducted to prove the topical effects of above-mentioned gels in patients.

Keywords: Contractubex gel, Silicone gel, Hypertrophic scar, Upper-extremity

Conflicts of Interest: None declared

Funding: None

*This work has been published under CC BY-NC-SA 1.0 license.

Copyright© Iran University of Medical Sciences

Cite this article as: Hassanpour SE, Farnoush N, Karami MY, Makarem A. The effect of silicone gel versus contractubex gel on the upper-extremity postsurgical scars: A randomized, double-blinded, controlled trial. *Med J Islam Repub Iran.* 2020 (29 Oct);34:146. <https://doi.org/10.47176/mjiri.34.146>

Introduction

Wound healing is a process that has three inflammatory phase, proliferative phase, and reconstruction phases. The normal scar treatment duration is about 6 months to 2 years (1, 2).

Surgical wounds scar varies from asymptomatic scars to

hypertrophic scars and keloids that may cause pain, pruritus, contraction and disfigurement, secondary infections, and psychological problems (3-8). Each year in the world, about one hundred million people suffer from scar related injuries (9). The management and treatment of keloid and

Corresponding author: Dr Nazila Farnoush, nazilafarnoush@sbmu.ac.ir

¹ Department of Plastic Surgery, 15 Khordad Educational Hospital, School of Medicine, Shahid Beheshti University of Medical Sciences, Tehran, Iran

² Breast Diseases Research Center, Shiraz University of Medical Sciences, Shiraz, Iran

³ Department of Urology, Faculty of Medicine, Shiraz University of Medical Sciences, Shiraz, Iran

↑What is “already known” in this topic:

Onion extract gel and Silicone gel show preventive effects in the literature, especially in burns wound, further studies are recommended to be conducted to prove the topical effects of above-mentioned gels in patients.

→What this article adds:

Our research results were contrary to prior expectations. Onion extract gel and Silicone gel fell short of surgeons' expectations in the prevention of post-surgical upper extremity wound hypertrophic scars.

hypertrophic scar are unsolvable problems; such issues include excision, radiation, cryotherapy, laser therapy, interferon therapy, intralesional corticosteroids, pressure therapy and some other treatments reduce the collagen synthesis (3, 10, 11). These kinds of treatment have different adverse effects (e.g., radiation therapy induces basal cell carcinoma and hyperpigmentation by corticosteroid therapy). Topical agents have been considered recently as the main form of treatment and prevention for keloids and hypertrophic scars (12-14).

Silicone gel and onion extract gel are two main topical agents used for the prevention and treatment of hypertrophic scars. The mechanism of silicone gel is unknown, but it may be through occlusion and hydration of the scar surface and avoidance of repeated epidermal avulsion. Onion extract gel has anti-inflammatory, bacteriostatic, and anti-proliferative effects on the fibroblasts (1, 12, 15-22).

This clinical trial study was designed to assess the efficacy and safety of onion extract and silicone gel on hypertrophic scars of the upper extremity and compare it to untreated patients (as the control group).

Methods

Patients

This randomized, double-blind, clinical trial was conducted for one year from February 2018 to February 2019 in 15 Khordad Hospital (Tehran, Iran), affiliated to Shahid Beheshti University of Medical Sciences.

The study protocol was approved by both the Institutional Review Board and Medical Ethics Committee of Shahid Beheshti University of Medical Sciences (Ethics committee reference number: IR.SBMU.RETECH.REC. 1397.458)

All the participants gave their written informed consent before the study. The patients were allowed to leave the study at any point. This clinical trial was registered in the Iranian Registry of Clinical Trials (IRCT20141218020364 N10).

The inclusion criteria were upper extremity sharp injury, male gender, and aged between 18-45 years old.

The exclusion criteria were peripheral vascular diseases; mental disorders, acute viral diseases, men with surgical complications like wound infection, men with a history of keloid or hypertrophic scarring in their upper extremity, men taking steroids that would affect wound healing, comorbidity diseases such as scleroderma or active dermatologic conditions, and men with an allergy to silicone or

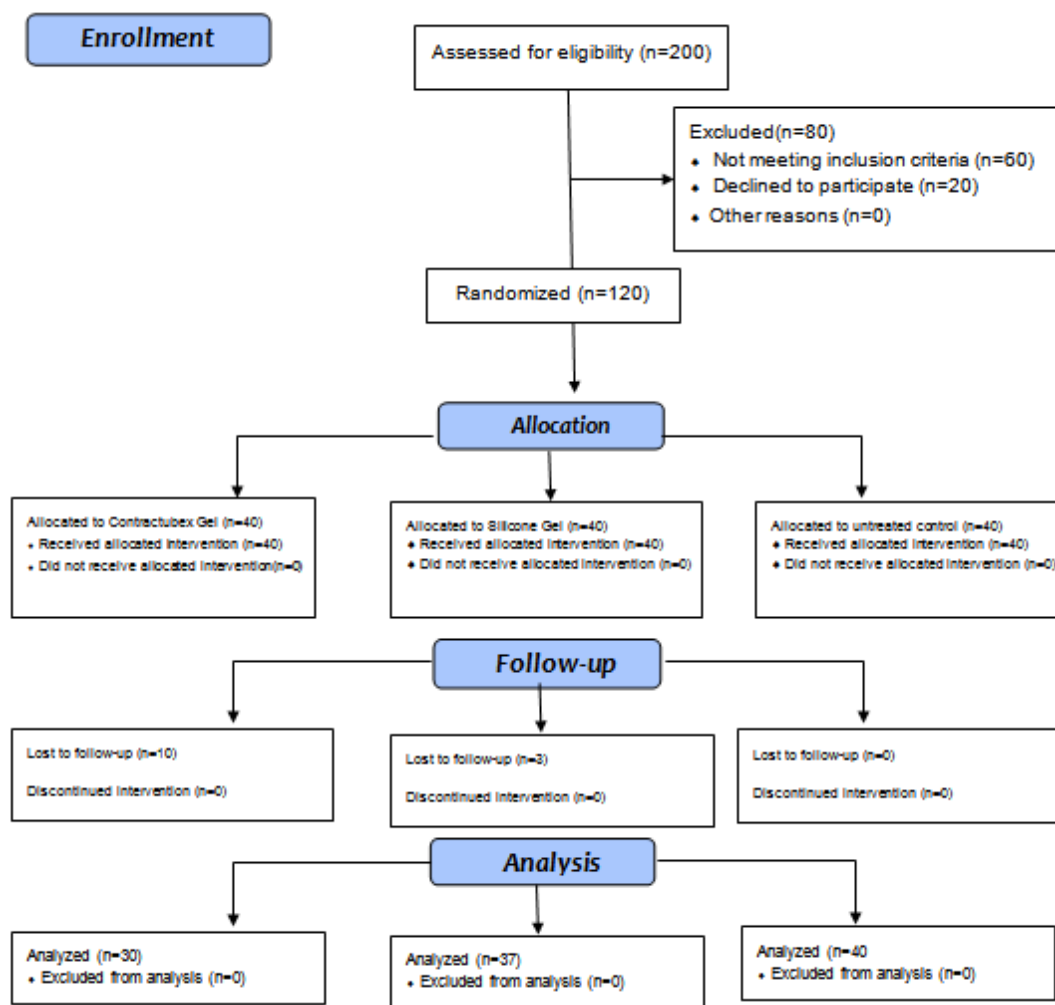


Fig.1. The CONSORT diagram showing the allocation process throughout the trial

onion. A total of 200 patients were diagnosed with upper extremity sharp injury and enrolled in the study. Sixty patients did not meet the inclusion criteria and twenty patients refused to participate in the study. Finally, 120 patients participated in the study (Fig. 1).

The patients were instructed about the clinical features of surgical procedures; then, they were referred to a Plastic Surgery clinic.

The participants were randomized into three groups by online randomization software (<http://www.randomization.com>). A sequence of randomized group numbers (i.e., 1 to 3) was generated by research assistant A, and the randomized group numbers were put into sealed envelopes. Participants enrolled by the first author using numbered sealed envelopes.

In this double-blind trial study, the participant, investigator, and outcomes assessor were not familiar with the groups. The safety and data monitoring committee and the main researcher (Surgeon) were informed about the study groups. The data analyzer did not know the study groups. All surgical procedures were performed by one surgeon.

Allocation process

All patients who had undergone upper extremity sharp injury repair enrolled in the study. Patients were assigned into three groups, i.e., Silicone gel (Kelo-cort™; WA, USA) (group 1; 40 patients) and Onion extract (Contractubex™, Merz Pharma, Frankfurt, Germany) gel (group 2; 40 patients), and No Intervention (group 3; 40 patients) using drawing sealed envelopes and a computer-based table of randomization.

Outcome and follow-up

From the day of suture removal (day ten), the treatment was applied once daily in group one and two times daily in group 2, half a fingertip for every 10 cm of wound length (equivalent to one gram of onion extract gel or silicone gel) for 4 months (23, 24).

Group 3 was left untreated as the control. Patients were followed up for 4 months, and outcomes were compared in the three groups between the second week and the sixteenth week. Data were recorded using the Vancouver scale (25, 26) in each visit by two surgeons who were blinded to the study groups. The patient's wound photograph was taken by a 5 megapixel camera (Nikon) and analyzed by the computer program of color and pigmentation. Outcome measures scar assessment was done using the Vancouver scar scale.

Four skin characteristics were assessed using a numerical scale, where 0 represents the person's normal skin.

The characteristics include height, pigmentation, vascularity (range 0-3), and pliability (range 0-5). Follow up period was four months (16 weeks) (Table 1).

Statistical Analysis

The collected data were recorded. Thirty-seven patients were required in each group for a study to have 90% power to detect significant differences between corresponding variables ($P=0.05$, two-sided). To compensate for possible non-valuable data, we enrolled 40 participants in each

Table 1. Vancouver scar scale.

Feature	Scale
Pigmentation	0: Normal color 1: Hypopigmentation 2: Mixed pigmentation 3: Hyperpigmentation
Vascularity	0: Normal color 1: Pink 2: Red 3: Purple
Pliability	0: Normal 1: Supple 2: Yielding 3: Firm 4: Banding-rope like tissue 5: Contracture
Height	0: Normal (flat) 1: <2mm 2: <5mm 3: >5mm

group. IBM SPSS Statistics for Windows, Version 22.0. (Armonk, NY: IBM Corp). Data were compared using the ANOVA test. A P-value of less than 0.05 was considered statistically significant.

Results

From February 2018 to September 2018, about 650 sharp injury patients were referred to 15 Khordad Hospital affiliated to Shahid Beheshti University of Medical Sciences.

Two hundred male patients had sharp injury trauma to the upper extremity and initially enrolled in the study. The final sample size was 120. Figure 1 presents the consort statement flow diagram. There were no significant differences among the three groups in terms of age, BMI, hemoglobin and white blood cell count before surgery, corticosteroid use, cigarette smoking, comorbidity diseases, surgery period and hospital stay (Table 2).

Vascularity, pliability, pigmentation, and height, as subjective scar parameters, were approximately similar in post-upper extremity sharp injury wound hypertrophic scar among the three groups (Table 3).

The mean overall Vancouver Score was lower in the untreated control wound (8.72 ± 0.78) than silicone gel (9.48 ± 0.76) and onion extract gel (9.13 ± 0.81) groups ($p=0.0001$). Wound infection and dehiscence were not presented in all patients during the post-operative period and follow-up.

Discussion

Hypertrophic scar is defined as dermal tissue proliferation after skin injury. The scar formation tendency varies between the normal population (3, 7). There are many probable factors influencing scar treatment, like races, different anatomical regions, wound depths, injury types, genetic factors, and prolonged immunologic responses (4). There is no fixed single successful treatment for hypertrophic scars and all the standard treatment protocols to hypertrophic scars begin with corticosteroid injection, surgical excision and pressure dressings (6). We aimed to test the effectiveness of silicone gel and onion extract gel compared with the untreated control group with adequate randomization and objective outcome measurements using Vancouver scale

Table 2. Demographic, laboratory indicators, surgical and medical data of patients

Items	Groups			p	
	Contractubex Gel (n=30)	Silicone Gel (n=37)	Control (n=40)		
Age	30.7±7.10	30.93±7.39	31.63±6.29	0.830	
Male (%)	30 (100)	37 (100)	40 (100)	0.999	
Hb (Mean ± SD)	10.8 (2.80)	12 (1.30)	11.1 (1.70)	0.140	
WBC(Mean ± SD)	6350 (3175)	6989 (2000)	7347 (2800)	0.340	
Cigarette smoking Frequency (%)	Yes	6 (28.6)	5 (25)	4 (21.10)	0.488
	No	15 (71.4)	15 (75)	15 (78.90)	
Surgery period (minute)	131.16±21.32	133.24±25.19	128.87±22.40	0.710	
Hospital Stay (day)	2.00±0.00	2.00±0.00	2.00±0.00		
Blood Loss (ml)	128.00±78.75	114.18±57.86	124.25±41.44	0.608	
Wound Infection	0	0	0	0.999	
Wound Dehiscence	0	0	0	0.999	

Table 3. Subjective scar parameters difference between groups

variable	Silicone Gel (n=37)	Contractubex Gel (n=30)	Control (n=40)	p*
Pigmentation	1.38±0.492	1.47±0.507	1.37±0.490	0.701
Pliability	4.00±0.816	3.70±0.877	3.60±0.545	0.058
Height	1.78±0.750	1.83±0.747	1.63±0.667	0.438
Vascularity	2.35±0.716	2.35±0.716	2.12±0.335	0.200
Overall Vancouver Score	9.48±0.768	9.13±0.819	8.72±0.784	<0.0001

*ANOVA

score.

There is limited high-quality study regarding the effect of topical prevention as compared to other treatment, negative placebo or untreated controls

This randomized parallel clinical trial showed no significant difference in terms of post-surgical hypertrophic scar among the groups. Vascularity, pliability, pigmentation, and height, as subjective scar parameters, were not statistically different in post-upper extremity sharp injury wound hypertrophic scar among the interventional groups. However, overall Vancouver score was less in the untreated control wound than the experiment groups.

It seems that wound hypertrophic scar prevention with the aforementioned topical treatment was not achieved with the current dose and assessment method.

Onion extract gel value and efficacy in the treatment of hypertrophic scars and reducing scar size have been well known for decades.

Silicone gel sheeting may prevent the formation of hypertrophic scars by decreasing the collagen remodeling phase of healing (27-29). Its effect is due to increased wound hydration (30). In a meta-analysis of five trials including 402 non-burn patients at risk for hypertrophic scarring, the rate of abnormal scarring was lower with silicone gel sheeting compared with control, but the difference was not statistically significant (31). Silicone gel can be used to reduce the risk of unpleasant scarring and erythema and to improve scar pliability in areas where silicone sheets will not conform to the shape or size of the burn wound (20).

An alternative therapy to silicone is onion extract gel; however, the evidence supporting this therapy for prevention of scarring is inconclusive and conflicting, with most trials in non-burn populations (23, 31-34). In one small trial that compared onion extract with silicone products (gel, gel sheet), the cosmetic appearance of burn hypertrophic scars was worse with onion extract gel after six months from injury as measured by the Vancouver Scar Scale (35).

BEUTH et al.'s study showed that after a minimum of 28 days of local treatment with onion gel and corticosteroid,

onion gel proved to be significantly superior in terms of safety and efficacy (32). Won Jin Ko's study showed that onion extract gel effectively reduced the amount of scar tissue (36). Kamonwan Jenwitheesuk et al.'s study showed silicone derivative plus onion extract gel might improve hyperpigmentation, pain and pruritis of the scar (37).

de Giorgi study (12) showed that silicone gel could decrease scar formation and improve the healing process

Different studies have shown the efficacy of silicone gel for hypertrophic scar treatment (38, 39). Ahn et al.'s study revealed the effectiveness of silicone in the treatment of chronic scar (40). Also, Kin Yoong Chan et al.'s study indicated that silicone gel sheet was effective in the prevention of hypertrophic scar development in sternotomy wounds (41).

In a review study (42) on fourteen topical preparations regarding their efficacy to prevent pathological scars, onion extract gel showed the best results. Previously, Hsu and colleges (43) revealed that silicone gel had a positive effect on the prevention of hypertrophic scars of skin lesion wounds.

The results of the study conducted by Jackson and Sheltons showed no significant difference in scar erythema and pruritis in pre- and post-treatment of patients using the onion extract gel (23).

Similar to the present study, Saulis et al.'s study in the rabbit ears model showed that there was no significant reduction in the scar hypertrophy or erythema in the scars treated by the onion extract gel compared to the untreated scars (44).

Prevention and treatment of hypertrophic scars remain a special unresolvable issue, especially for plastic surgeons. Topical preparations are an attractive therapeutic option. However, the efficacy of these topical preparations in the prevention of scars is questioned.

The main limitation of our study was the large number of people who were excluded during the study and lack of before treatment assessment.

Conclusion

Our research results were contrary to prior expectations. Onion extract gel and Silicone gel fell short of surgeons' expectations in the prevention of post-surgical upper extremity wound hypertrophic scars. Even though onion extract gel and Silicone gel show preventive effects in the literature, especially in burns wound, further studies are needed to strengthen the body of evidence and prove the therapeutic efficacy of topical preparations in general.

Acknowledgment

The authors would like to thank Shiraz University of Medical Sciences, Shiraz, Iran, and the Center for Development of Clinical Research of Nemaazi Hospital for their support. We also thank Dr. Nasrin Shokrpour for editorial assistance.

Conflict of Interests

The authors declare that they have no competing interests.

References

- De Giorgi V, Sestini S, Mannone F, Papi F, Alfaioli B, Gori A, et al. The use of silicone gel in the treatment of fresh surgical scars: a randomized study. *Clin Exp Dermatol*. 2009;34(6):688-93.
- Stavrou D, Weissman O, Winkler E, Yankelson L, Millet E, Mushin OP, et al. Silicone-based scar therapy: a review of the literature. *Aesthetic Plast Surg*. 2010;34(5):646-51.
- Augusti K. Therapeutic values of onion (*Allium cepa* L.) and garlic (*Allium sativum* L.). *Indian J Exp Biol*. 1996;34(7):634-40.
- Shaffer JJ, Taylor SC, Cook-Bolden F. Keloidal scars: a review with a critical look at therapeutic options. *J Am Acad Dermatol*. 2002;46(2):S63-S97.
- Niessen FB, Spauwen PH, Schalkwijk J, Kon M. On the nature of hypertrophic scars and keloids: a review. *Plast Reconstr Surg*. 1999;104(5):1435-58.
- Singer AJ, Clark RA. Cutaneous wound healing. *N Eng J Med*. 1999;341(10):738-46.
- Tsao S, Dover J, Arndt K, Kaminer M, editors. Scar management: keloid, hypertrophic, atrophic, and acne scars. *Seminars in cutaneous medicine and surgery*; 2002.
- Brissett AE, Sherris DA. Scar contractures, hypertrophic scars, and keloids. *Facial Plast Surg*. 2001;17(04):263-72.
- Zekavat O, Amanat A, Karami M, Paydar S, Gramizadeh B, Zareian-Jahromi M. Wound healing studies using *Punica granatum* Peel: an animal experimental study. *Adv Skin Wound Care*. 2016;29(5):217-25.
- Ho S, Marçal H, Foster LJR. Towards scarless wound healing: a comparison of protein expression between human, adult and foetal fibroblasts. *BioMed Res Int*. 2014;2014.
- Craig R, Schofield J, Jackson S. Collagen biosynthesis in normal human skin, normal and hypertrophic scar and keloid. *Eur J Clin Invest*. 1975;5(1):69-74.
- Mustoe TA, Cooter RD, Gold MH, Hobbs F, Ramelet A-A, Shakespeare PG, et al. International clinical recommendations on scar management. *Plast Reconstr Surg*. 2002;110(2):560-71.
- Momeni M, Hafezi F, Rahbar H, Karimi H. Effects of silicone gel on burn scars. *Burns*. 2009;35(1):70-4.
- Mustoe TA. Evolution of silicone therapy and mechanism of action in scar management. *Aesthetic Plast Surg*. 2008;32(1):82.
- Reish RG, Eriksson E. Scar treatments: preclinical and clinical studies. *J Am Coll Surg*. 2008;206(4):719-30.
- Willital G, Heine H. Efficacy of Contractubex gel in the treatment of fresh scars after thoracic surgery in children and adolescents. *Int J Clin Pharmacol Res*. 1994;14(5-6):193-202.
- Stein G. Erfahrungen mit der behandlung von keloiden und hypertrophen narben unterschiedlicher genese mit Contractubex comp. *Therapiewoche*. 1985;35(11):1199-207.
- Maragakis M, Willital G, Michel G, Görtelmeyer R. Possibilities of scar treatment after thoracic surgery. *Drugs Exp Clin Res*. 1995;21(5):199-206.
- Berman B, Perez OA, Konda S, Kohut BE, Viera MH, Delgado S, et al. A review of the biologic effects, clinical efficacy, and safety of silicone elastomer sheeting for hypertrophic and keloid scar treatment and management. *Dermatol surg*. 2007;33(11):1291-303.
- Chernoff WG, Cramer H, Su-Huang S. The efficacy of topical silicone gel elastomers in the treatment of hypertrophic scars, keloid scars, and post-laser exfoliation erythema. *Aesthetic Plast Surg*. 2007;31(5):495-500.
- Puri N, Talwar A. The efficacy of silicone gel for the treatment of hypertrophic scars and keloids. *J Cutan Aesthet Surg*. 2009;2(2):104.
- Rhee SH, Koh SH, Lee DW, Park BY, Kim YO. Aesthetic effect of silicone gel on surgical scars in Asians. *J Craniofac Surg*. 2010;21(3):706-10.
- Jackson BA, Shelton AJ. Pilot study evaluating topical onion extract as treatment for postsurgical scars. *Dermatol surg*. 1999;25(4):267-9.
- Kim SM, Choi JS, Lee JH, Kim YJ, Jun YJ. Prevention of Postsurgical Scars: Comparison of Efficacy and Convenience between Silicone Gel Sheet and Topical Silicone Gel. *J Korean Med Sci*. 2014;29(Suppl 3):S249-S53.
- Fearmonti R, Bond J, Erdmann D, Levinson H. A review of scar scales and scar measuring devices. *Eplasty*. 2010;10:e43-e.
- Sullivan T, Smith J, Kermode J, Melver E, Courtemanche D. Rating the burn scar. *J Burn Care Rehabil*. 1990;11(3):256-60.
- Nedelec B, Carter A, Forbes L, Hsu SC, McMahon M, Parry I, et al. Practice guidelines for the application of nonsilicone or silicone gels and gel sheets after burn injury. *J Burn Care Res*. 2015;36(3):345-74.
- Kuhn MA, Moffit MR, Smith PD, Lyle WG, Ko F, Meltzer DD, et al. Silicone sheeting decreases fibroblast activity and downregulates TGFbeta2 in hypertrophic scar model. *Int J Surg Investig*. 2001;2(6):467-74.
- Musgrave MA, Umraw N, Fish JS, Gomez M, Cartotto RC. The effect of silicone gel sheets on perfusion of hypertrophic burn scars. *J Burn Care Rehabil*. 2002;23(3):208-14.
- Gilman TH. Silicone sheet for treatment and prevention of hypertrophic scar: a new proposal for the mechanism of efficacy. *Wound Repair Regen*. 2003;11(3):235-6.
- O'Brien L, Jones DJ. Silicone gel sheeting for preventing and treating hypertrophic and keloid scars. *Cochrane Database Syst Rev*. 2013(9):Cd003826.
- Beuth J, Hunzelmann N, Van Leendert R, Basten R, Noehle M, Schneider B. Safety and efficacy of local administration of Contractubex® to hypertrophic scars in comparison to corticosteroid treatment. Results of a multicenter, comparative epidemiological cohort study in Germany. *In vivo*. 2006;20(2):277-83.
- Chanprapaph K, Tanrattanakorn S, Wattanakrai P, Wongkitisophon P, Vachiramon V. Effectiveness of onion extract gel on surgical scars in Asians. *Dermatol Res Pract*. 2012;2012:212945.
- Chung VQ, Kelley L, Marra D, Jiang SB. Onion extract gel versus petrolatum emollient on new surgical scars: prospective double-blinded study. *Dermatol Surg*. 2006;32(2):193-7.
- Karagoz H, Yuksel F, Ulkur E, Evinc R. Comparison of efficacy of silicone gel, silicone gel sheeting, and topical onion extract including heparin and allantoin for the treatment of postburn hypertrophic scars. *Burns*. 2009;35(8):1097-103.
- Ko WJ, Na YC, Suh BS, Kim HA, Heo WH, Choi GH, et al. The effects of topical agent (kelo-cote or contractubex) massage on the thickness of post-burn scar tissue formed in rats. *Arch Plast Surg*. 2013;40(6):697.
- Jenwitheesuk K, Surakunprapha P, Jenwitheesuk K, Kuptarmond C, Prathane S, Intanoo W. Role of silicone derivative plus onion extract gel in presternal hypertrophic scar protection: a prospective randomized, double blinded, controlled trial. *Int wound J*. 2012;9(4):397-402.
- Alster TS, West TB. Treatment of scars: a review. *Ann Plast Surg*. 1997;39(4):418-32.
- O'Sullivan ST, O'Shaughnessy M, O'Connor TP. Aetiology and management of hypertrophic scars and keloids. *Ann R Coll Surg Engl*. 1996;78(3 (Pt 1)):168-75.
- Ahn ST, Monafó WW, Mustoe TA. Topical silicone gel: a new treatment for hypertrophic scars. *Surgery*. 1989;106(4):781-6;discussion 6-7.
- Chan KY, Lau CL, Adeeb SM, Somasundaram S, Nasir-Zahari M. A randomized, placebo-controlled, double-blind, prospective clinical trial of silicone gel in prevention of hypertrophic scar development in

- median sternotomy wound. *Plast Reconstr Surg.* 2005;116(4):1013-20; discussion 21-2.
42. Fischer S, Ernst HR, Drucke D, Diehm Y, Lehnhardt M, Daigeler A. [Topical Preparations for Prevention and Treatment of Hypertrophic Scars and Keloids: A Literature Review]. *Handchir Mikrochir Plast Chir.* 2015;47(4):253-67.
43. Hsu KC, Luan CW, Tsai YW. Review of Silicone Gel Sheeting and Silicone Gel for the Prevention of Hypertrophic Scars and Keloids. *Wounds.* 2017;29(5):154-8.
44. Saulis AS, Mogford JH, Mustoe TA, Tredget EE, Anzarut A. Effect of Mederma on hypertrophic scarring in the rabbit ear model. *Plast Reconstr Surg.* 2002;110(1):177-83.