

Case Reports

ACUTE APPENDICITIS DUE TO METASTASIS OF PROSTATIC CARCINOMA

B. ARYA,* M.D., B. GHAZI-MOGHADAM,** M.D., M.J.
GOOLALIPOUR,*** Ph.D, AND R. AZARHOOSH,**** M.D.

From the *Departments of General Surgery, **Urology, ***Histology and Embryology, and ****Pathology, Golestan University of Medical Sciences, Gorgan, I.R. Iran.

ABSTRACT

A 70 year old male presented with right lower quadrant pain and anorexia for about 72 hours prior to hospital admission. He underwent laparotomy with impression of acute appendicitis. The operative finding was an inflamed tumoral appendix without appendicular base involvement, and appendectomy was done. The patient had an uneventful post-op course.

Due to the pathology report of prostatic carcinoma he underwent cystoscopy and biopsy of prostate on the 4th post-op day. Histopathology of the appendix was consistent with metastatic adenocarcinoma of the appendix with prostatic origin. Histopathology of the prostatic specimen was consistent with high grade prostatic adenocarcinoma.

MJIRI, Vol. 17, No. 3, 263-265, 2003.

Keywords: Appendix, Adenocarcinoma, Prostate.

INTRODUCTION

Appendiceal tumours can be divided into primary and metastatic; the latter usually originate from the gastrointestinal tract, breast, and female genital tract.^{1,2}

Metastatic prostatic carcinoma may rarely be seen in the testis, skin, penis, central nervous system, liver, adrenal gland, kidneys, breasts & lungs.³ But metastasis to the appendix from prostatic carcinoma has not been reported in the reviewed literature.

CASE REPORT

A 72 year old male patient was referred with a chief complaint of right lower quadrant (RLQ) pain and anorexia since 72 hours before admission. There was no history of nausea, vomiting, constipation, diarrhea or uri-

nary frequency, dribbling or dysuria. In physical examination there were no remarkable signs except for RLQ tenderness and guarding.

On rectal examination there was a firm palpable prostate. Urinalysis was unremarkable except for trace proteinuria. All biochemical findings such as blood sugar, BUN, electrolytes and serum creatinine all were normal. Hematological indices were as follows: Hgb=11, WBC count 10500 with 73% neutrophils, 25% lymphocytes and 2% monocytes. With a diagnosis of acute appendicitis the patient underwent laparotomy. Upon operation we found an inflamed tumoral appendix with a normal looking appendicular base and a palpable 0.5x0.5 cm retroperitoneal mass in the course of the right ureter. The appendicular tip was positioned in the upper pelvic area. Urologic consultation was done and post-op follow-up planned. There were no post-op complications. Histopathological finding was consistent with acute inflammation and the presence of metastatic adenocarcinoma (Fig.1) which was confirmed using immunohistochem-

*Correspondence: Dr Biezhnan Arya, Department of General Surgery, 5th of Azar Hospital, Gorgan, Iran, Tel: 0098-171-2240923.

Acute Appendicitis Due to Metastasis of Prostatic Carcinoma

istry study for prostate specific antigen (PSA) which was positive in our case (Fig. 2).

Following the above finding the patient underwent a complete check-up by a urologist. Lab tests such as SGOT, SGPT, bilirubin, calcium, and phosphorous, were in the normal range. On the 4th post-op day cystoscopy and biopsy of the prostate was done. Histopathologic examination of the prostate confirmed prostatic adenocarcinoma (Fig. 3). The patient was discharged later with no complication.

The patient was readmitted to the hospital about 3 months after appendectomy, at which time he underwent TURP and bilateral orchiectomy followed by chemotherapy due to advanced cancer. The other readmission of this patient was due to abdominal pain, jaundice and multiple hepatic metastases. Unfortunately he died about two months later, sixteen months after his first admission.

DISCUSSION

Appendiceal malignancies are not common, occurring in 0.5% of all appendectomies, and usually discovered in laparotomy either as an incidental finding or in association with acute inflammation of the appendix or an abdominal mass.^{4,5,6,7} Appendiceal tumors can be divided into primary and metastatic tumors. The most common lesion is carcinoid tumor which accounts for some 90% of all primary tumors of the appendix.^{8,9,10} Other primary appendiceal malignant tumors are adenocarcinoma, malignant mucocele and lymphoma, in order of frequency.⁴ Benign tumors of the appendix are rare, including mucoceles, neuromas, leiomyomas, villous adenomas,¹¹ granular cell tumors and paragangliomas.² Metastasis to the appendix usually originates in carcinomas of the gastrointestinal tract, breast or female genital tract.^{1,2} Although it is very rare¹² metastasis to the appendix from small cell bronchogenic carcinoma,^{13,14} adenocarcinoma of the lung,¹⁵ gastric cancer,¹² choriocarcinoma of the me-

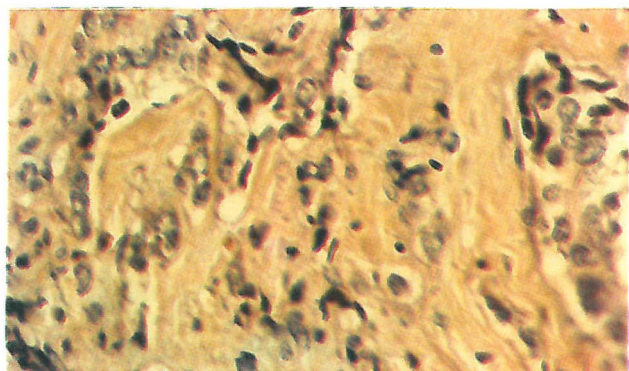


Fig. 1. Metastasis of prostatic carcinoma to submucosa of the appendix (H & E $\times 400$).

diastinum¹⁶ and breast cancer¹⁷ has been reported in the literature, although metastasis of prostatic cancer to the appendix has not been reported.

Carcinoma of the prostate is the most common visceral cancer in males ranking as the second most common cause of cancer-related deaths in men older than 50 years of age, after carcinoma of the lung. It is predominantly a disease of older males, with a peak incidence between the ages of 65 and 75 years.^{18,19} Carcinomas of the prostate are often clinically silent particularly during their early stages. Later in the course of illness it may become symptomatic. Symptoms of prostatism and lower urinary tract obstruction and even symptoms of metastasis may become evident.^{18,19}

The usual sites of metastasis are pelvic lymph nodes, bone and the lungs. However, many unusual sites of metastasis are possible including kidneys, breast, brain,³ liver, adrenals, seminal vesicles, bladder and rectum.¹⁹ Metastasis of prostatic carcinoma to the appendix has not been reported.

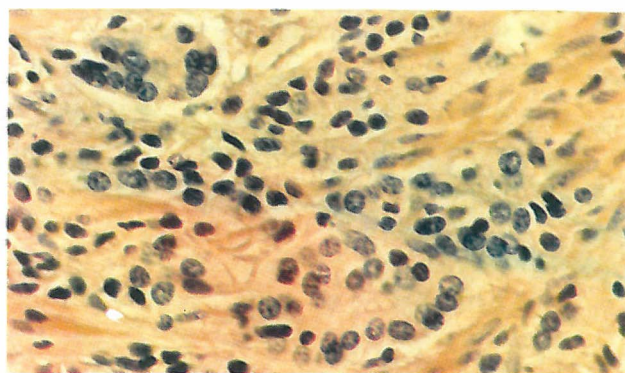


Fig. 2. PSA reactivity in tumor glands (Immunohistochemical staining $\times 400$).

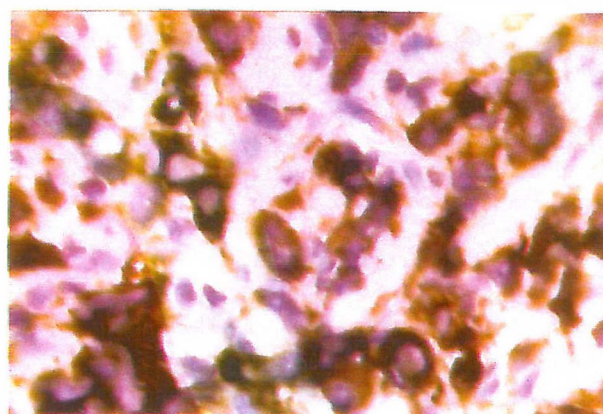


Fig. 3. Prostatic adenocarcinoma, composed of irregular glands lined by epithelial cells with relatively monomorphic nuclei, arranged in one-cell layer (H & E $\times 400$).

Primary adenocarcinoma of the appendix needs right hemicolectomy for treatment^{4,5,6,8} but the secondary type probably needs appendectomy and treatment of the primary tumor as metastatic cancer.

REFERENCES

1. Rosai J: The appendix. In: Rosi J, (ed.), Ackerman's Surgical Pathology, 7th ed, St. Louis: Mosby Company, p. 569, 1989.
2. Petrus RE, Goldblum JR: Appendix. In: Damjanov L, Linder J, (eds.), Anderson's Pathology, 10th ed, St. Louis: Mosby Company, pp. 1734-6, 1996.
3. Bostwick DG, Amin MB: Prostate and seminal vesicles. In Damjanov L, Linder J, (eds.), Anderson's Pathology, 10th ed, St. Louis: Mosby Company, p. 2219, 1996.
4. Kozar RA, Roslyn JJ: The appendix. In: Schwarz SI, Shires GT, Spencer FC, et al. (eds.), Principles of Surgery, 7th ed. New York: Mc Graw-Hill, p. 1392, 1999.
5. Didolkar MS, Fanous N: Adenocarcinoma of the appendix: a clinicopathologic study. *Dis Colon Rectum* 20(2): 130-4, March 1977.
6. Delgado RRJR, Mullen JT, Ehrlich FE: Primary adenocarcinoma of the appendix. *South Med J* 68(8): 976-8, Aug 1975.
7. Edmonds P, Merino MJ, Livolsi VA, Duray PH: Adenocarcinoid (mucinous carcinoid) of the appendix. *Gastroenterology* 86(2): 302-9, Feb 1984.
8. Sabiston DC jr: Appendicitis. In: Sabiston DC jr, Lyerly HK, (eds.), Sabiston Textbook of Surgery, 15th ed, Philadelphia: W.B. Saunders Company, p. 970, 1997.
9. Dymock RB: Pathological changes in the appendix : a review of 1000 cases. *Pathology* 9(4): 331-9, Oct 1977.
10. D'Aleo C, Lazzareschi I, Ruggiero A, Riccardi R: Carcinoid tumors of the appendix in children: two case reports and review of the literature. *Pediatr Hematol Oncol* 18(5): 347-51, Jul-Aug 2001.
11. Schmutzer KJ, Bayar M, Zaki AE, Regan JF, Poletti JB: Tumors of the appendix. *Dis Colon Rectum* 18(4): 324-31, May-June 1975.
12. Gillesse EG, Mud HJ, Prins ME: An unusual cause of acute appendicitis. *Neth J Surg* 39(5): 153-4, Oct 1987.
13. Pang LC: Metastasis induced acute appendicitis in small cell bronchogenic carcinoma. *South Med J* 81(11): 1461-2, Nov 1988.
14. Gonzalez-Vela MC, Garcia-Valtuille AL, Fernandez FA, Val-Vernal JE: Metastasis from small cell carcinoma of the lung producing appendicitis. *Pathol Int* 46(3): 216-20, March 1996.
15. Haid M, Larson R, Christ M: Metastasis from adenocarcinoma of the lung producing acute appendicitis. *South Med J* 85(3): 319-21, March 1992.
16. Ramia JM, Alcalde J, Cubedo R: Metastasis from choriocarcinoma of the mediastinum producing acute appendicitis. *Dig Sci* 43(2): 332-4, Feb 1998.
17. Burney RE, Koss N, Goldenberg IS: Acute appendicitis secondary to metastatic carcinoma of the breast. A report and review of two cases. *Arch Surg* 108(6): 872-5, Jun 1974.
18. Burns DK: The male genital system, In: Kumar V, Cotran RS, Robbins SL, (eds.), Basic Pathology, 6th ed, Philadelphia: W.B. Saunders Company, pp. 586-8, 1997.
19. Epstein JI: Pathology of adenocarcinoma of the prostate. In: Walsh PC, Retik AB, Vaughan EDjr, Wein AJ, (eds.), Campbell's Urology, 7th ed., Vol. 3, Philadelphia: W.B. Saunders, pp. 2498-9, 1998.

