

# FAMILIAL COLLOID CYST OF THE THIRD VENTRICLE: A CASE REPORT AND REVIEW OF THE LITERATURE

SOHRAB SADEGHI, M.D., GUIVE SHARIFI, M.D.,  
AND ALI ALIASGARI, M.D.

*From the Dept. of Neurosurgery, Loghman-Hakim Medical Center, Shahid Beheshti University of Medical Sciences, Tehran, Iran.*

## ABSTRACT

Familial colloid cyst of the third ventricle is very rare. This is one of the two largest families reported and the first in which all affected members are siblings. One asymptomatic sister was found by screening, emphasizing the value of screening.

A brother and two sisters from a family consisting of three brothers and three sisters who were diagnosed as having colloid cyst of the third ventricle are presented. The index case like his sister underwent a tumor resection by middle frontal gyrus approach. Brain CT scan was performed for the other first degree family members for screening and colloid cyst was detected in another sister.

When two or more members of a family are affected, screening has an important value for detecting other asymptomatic members with colloid cyst of the third ventricle.

*MJIRI, Vol. 17, No. 3, 267-269, 2003.*

**Keywords:** colloid cyst, third ventricle, familial.

## INTRODUCTION

Colloid cysts of the third ventricle are rare conditions accounting for approximately 0.5 to 1.0 percent of primary brain tumors.<sup>8,13</sup> Histological analyses have documented that colloid cysts form when ectopic endodermal elements migrate into the velum interpositum during development of the central nervous system.<sup>7,4</sup> Possible other sources such as paraphysis, choroid plexus, ependymal, primitive ectoderma have been suggested. Despite the disputable tissue of origin, the congenital nature of this lesion is generally accepted.<sup>6,9</sup> They arise in the anterior portion of the third ventricle and obstruct the foramen of Monroe. Colloid cysts may be found incidentally at autopsy in patients who expressed no neurological complaints or in other patients by obstructing

the foramina of Monroe producing hydrocephalus, intracranial hypertension and subsequent neurological dysfunction such as intermittent headaches, memory loss, seizure, and drop attacks.<sup>2</sup> To our knowledge five familial colloid cyst cases have been reported to date.<sup>1,3,5,10,12</sup>

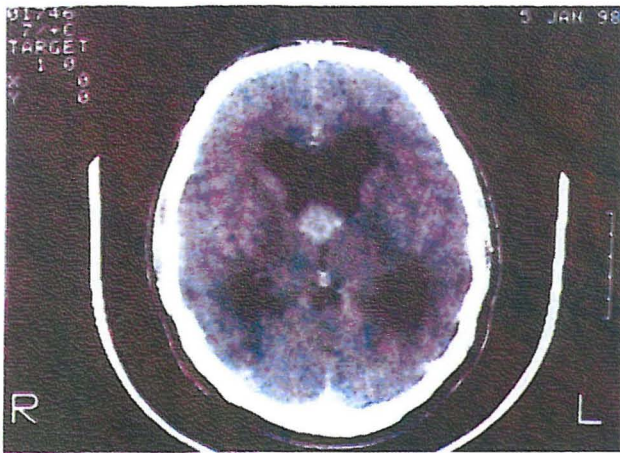
## CASE REPORTS

### Case 1

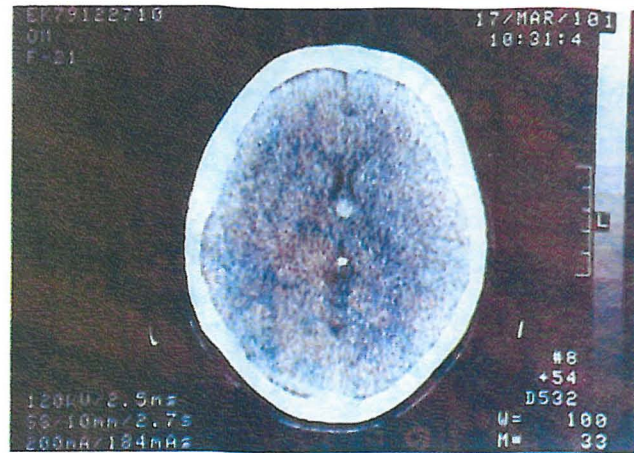
A 26-year-old man presented with severe headache, obtundation and refractory vomiting. The patient had a history of bifrontal headache for 3-4 months. A neurological examination revealed unsteady gait and bilateral extensor plantar reflex. The patient's consciousness deteriorated rapidly and he became comatose. Brain CT scan (Fig. 1) revealed severe hydrocephalus with a large third ventricle colloid cyst obstructing the foramen of Monroe. Emergency bilateral frontal ventriculostomy was performed after which the patient's consciousness became normal. The colloid cyst was resected using middle frontal gyrus approach. The patient was discharged with-

**Corresponding Address:** Guive Sharifi, M.D., Department of Neurosurgery, Loghman-Hakim Medical Center, Kamali Ave., Tehran, Iran, Telephone: +98-21-544065; +98-21-549005-9. Fax: +98-21-544065. Email: guivesharifi@hotmail.com

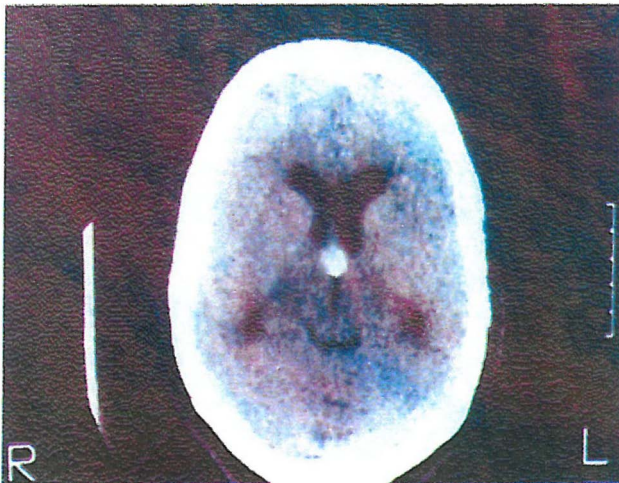
## Colloid Cyst of Third Ventricle



**Fig. 1.** CT scan shows a hyperdense, relatively large colloid cyst in the third ventricle (case 1).



**Fig. 3.** CT scan of the asymptomatic sister showing a small colloid cyst without hydrocephalus (case 3).



**Fig. 2.** An anterior third ventricle hyperdense colloid cyst (case 2).

out any neurological problem. Pathological study confirmed colloid cyst.

### Case 2

A 33-year-old woman presented with severe headache. The patient had a history of bifrontal headache for 3 years for which she had received different types of medications. Her headache was aggravated for three weeks with symptoms of elevated ICP. The optic disc was blurred in the neurological examination but no other positive finding was detected. Brain CT scan (Fig. 2) revealed mild to moderate hydrocephalus and a colloid cyst in the anterior third ventricle. Her brother (case 1) had had a colloid cyst resection three years before.

Her tumor was resected using the middle frontal gyrus approach. The patient was discharged while having

a normal neurological examination. Colloid cyst was confirmed pathologically.

### Case 3

Screening brain CT scan for diagnosing colloid cyst was performed in the first degree relatives of the index family. The family consists of three daughters and three sons. Another 18-year-old daughter also had a third ventricle colloid cyst (the tumor size was smaller than the previous two patients) without hydrocephalus (Fig. 3). The patient had no neurological sign and underwent a follow-up program.

## DISCUSSION

Familial colloid cysts of the third ventricle are very rare. Five familial colloid cyst cases have been reported so far, consisting of colloid cysts in twin brothers,<sup>5</sup> in two nontwin brothers,<sup>3</sup> in a father and his son,<sup>1</sup> in a brother and sister<sup>12</sup> and in a mother and her two daughters.<sup>10</sup> In our case a brother and two sisters from a family of eight members are affected. In our case, like the latter case, screening has been worthy and has helped in finding the asymptomatic sister. This once again places emphasis on the value of screening in families in which two or more members are affected.

In one of the two case reports chromosomal study has been performed with negative results, but we didn't perform such an analysis.

In our case one of the family's sons was moderately mentally retarded. There was no history of serious medical disease, metabolic disease or connective tissue disease in the family.

Previous studies on asymptomatic colloid cyst cases with tumors smaller than 1 cm have shown the possibil-

ity of maintenance of CSF circulation around the tumor, suggesting follow-up with serial imaging as an alternate to surgery.<sup>2,11</sup> We chose this policy in our asymptomatic case.

The occurrence of colloid cyst in first degree relatives is unlikely to be by chance alone and a genetic factor may play a role in the pathogenesis of this tumor which needs more precise genetic studies.

#### REFERENCES

1. Akins PT, Roberts R, Coxs MS, Kaufman BA: Familial colloid cyst of the third ventricle: case report and review of associated condition. *Neurosurgery* 38: 392-395, 1996.
2. Apuzzo MLJ, Chen TC, Hinton DR, Krieger M, ZeeES: *Surgery of the third ventricle*. Baltimore: Williams & Wilkins, 2nd ed., pp. 1096-1125, 1998.
3. Bengtson BP, Hedeman LS, Bauserman SC: Symptomatic neuroepithelial (colloid) cysts of the third ventricle. A unique case report in non-twin brothers. *Cancer* 66(4): 779-85, 1990.
4. Ho KL, Garcia JH: Colloid cysts of the third ventricle, ultrastructural features are compatible with endodermal deviation. *Acta Neuropathol (Berlin)* 83: 605-612, 1992.
5. Ibrahim AWM, Farag H, Naguib M, Ibrahim E: Neuroepithelial (colloid) cyst of the third ventricle in identical twins: case report. *J Neurosurg* 65: 401-403, 1986.
6. Kondzioldka D, Bilbao JM: An immunohistochemical study of neuroepithelial (colloid) cysts. *J Neurosurg* 71: 91-97, 1989.
7. Lach B, Scheithauer BW, Gregor A, Wick MR: Colloid cyst of the third ventricle: a comparative immunohistochemical study of the neuraxis cysts and choroid plexus epithelium. *J Neurosurg* 78: 101-111, 1993.
8. Little JR, MacCarty CS: Colloid cyst of the third ventricle. *J Neurosurg* 40: 230-235, 1974.
9. Mackenzie IRA, Gilbert JJ: Cysts of neuraxis of endodermal origin. *J Neuro Neurosurg Psychiatry* 54: 572-575, 1991.
10. Nader-Sepahi A, Hamlyn PJ: Familial colloid cysts of the third ventricle: case report. *Neurosurgery* 46: 751-753, 2000.
11. Pollock BE, Shereiner SA, Huston J: A theory on the natural history of the colloid cysts of the third ventricle. *Neurosurgery* 46: 1077-1083, 2000.
12. Stoodley MA, Nguyen TP, Robbins P: Familial fatal and near-fatal third ventricle colloid cysts. *Aust N Z J Surg* 69 (10):733-6, 1999.
13. Zulch KJ: *Brain tumors their biology and pathology*, 3rd. ed. Berlin: Springer Verlag, pp. 332-335, 1986.