

# LYMPH NODE REVEALING SOLUTION: A NEW USEFUL METHOD FOR ISOLATION OF MINUTE AXILLARY LYMPH NODES IN BREAST CANCER

B. GERAMIZADEH AND A. RAZAVI

*From the Department of Pathology, Shiraz University of Medical Sciences, Shiraz, I.R. Iran.*

## ABSTRACT

Breast cancer is one of the most common malignancies in the world. The most important prognostic factor in this cancer is the stage of the tumor. Detection of lymph nodes with or without malignancy is essential for determining the stage of the tumor and setting a therapeutic plan.

There are different methods for isolating lymph nodes in surgical specimens of breast cancer in the pathology department.

The most popular method is routine palpation, but isolation of very small lymph nodes is difficult and time consuming and some may be missed. The main goal of this paper is to describe a new, precise and easy technique for finding nodes in breast cancer specimens.

In this study 50 cases of breast cancer were randomly selected. In these cases axillary fat was examined for lymph nodes by traditional method, and then the entire axillary fat was immersed overnight in a lymph node revealing solution (LNRS) composed of various traditional fixatives and fat solvent. After overnight fixation the lymph nodes stood out as white chalky nodules on the background of yellow fat. They were then excised, processed and stained by routine H&E method.

The total number of lymph nodes found by traditional method in these 50 cases was 660. After application of LNRS, 178 additional lymph nodes measuring from 0.5 to 9 mm were found. The LNRS increased the mean number of nodes per case from 13.20+/-6.61 found by traditional method to 16.67+/-7.64 nodes per case (p value<0.01).

The size of lymph nodes identified by LNRS was significantly smaller than those found by traditional method (p value<0.01).

In 8 cases, tumor stage was increased by application of LNRS in addition to routine palpation.

As a whole LNRS is a useful, rapid and good fixative. It significantly enhances the yield of lymph nodes in the axillary fat of breast cancer specimens.

*MJIRI, Vol. 17, No. 1, 11-14, 2003.*

## INTRODUCTION

Breast cancer is one of the most common malignan-

cies in the world, so it is the focus of intensive study relative to various aspects, especially prognostic factors. The most important prognostic factor is axillary lymph

## Use of Lymph Node Revealing Solution for Better Lymph Node Isolation

node status. Without lymph node involvement the 10-year disease-free survival rate is close to 70-80%, which falls to 35-40% with 1-3 positive nodes and 10-15% in the presence of more than 3 positive nodes. In this regard several methods have been proposed for the isolation of lymph nodes,<sup>1</sup> one of these is a type of fixative (lymph node revealing solution) which we used for lymph node separation.

### MATERIAL AND METHODS

In this prospective study fifty cases of breast cancer who underwent mastectomy between 1998-2000 were selected. The specimens had been sent to the pathology department and were routinely handled, i.e., after overnight fixation in 10% buffered formalin, axillary fat was dissected and lymph nodes were identified by palpation and visualization. Then they were excised and processed as usual. This procedure was performed by one pathologist who was unaware of this study. The remaining axillary tissue was immersed overnight in 3-4 times its volume of LNRS.

100 mL LNRS is a mixture prepared of:

|       |                         |
|-------|-------------------------|
| 65 mL | 95% ethanol             |
| 20 mL | diethyl ether           |
| 5 mL  | glacial acetic acid     |
| 10 mL | buffered formalin (10%) |

After overnight fixation in LNRS the axillary fat was washed thoroughly under running tap water and sectioned again at intervals of 2-3 mm apart. The remaining lymph nodes stood out as white chalky nodules against a background of yellowish fat (Fig. 1).

The revealed lymph nodes were then excised, embedded in paraffin, sectioned, and stained with H&E (Hematoxylin and Eosin).

The total number of lymph nodes found with the traditional method and with LNRS was recorded.

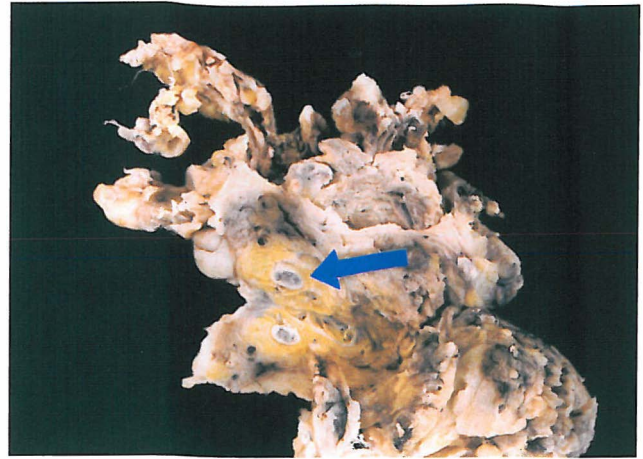
For staging of the tumors, the TNM classification suggested by the American Joint Committee (AJCC) was used.

Additionally the average number of isolated lymph nodes by traditional method in mastectomy specimens of 203 breast cancer patients during the last 5 years in the pathology department was recorded as a control.

### RESULTS

Generally after fixation with LNRS the stained slides showed better quality than after fixation with formalin alone.

In case No. 1 no lymph node was detected, and in 12 cases less than 10 lymph nodes were detected (case No. 2-13) by routine, traditional formalin fixation and palpation.



**Fig. 1.** A fragment of axillary fat which has been fixed overnight in LNRS (Note the small lymph node which had been missed by formalin, arrow).

As a whole 660 lymph nodes were identified by routine method (Mean  $13.20 \pm 6.61$ ).

After overnight fixation with LNRS an additional 178 lymph nodes were identified with a mean of  $3.65 \pm 2.48$  nodes per case (ranging between 0 to 9).

The LNRS increased the total number of lymph nodes per case to  $16.76 \pm 7.641$ .

Comparing the two methods, the increase in the number of lymph nodes by LNRS was statistically significant ( $p$  value  $< 0.01$ ).

By using the traditional method a total of 150 metastatic nodes was identified (Mean =  $3 \pm 4.22$ ) in all 50 mastectomy specimens.

The LNRS revealed an additional 48 metastatic lymph nodes with a mean of  $0.96 \pm 2.47$ .

LNRS changed the pathologic staging in 8 (16%) of the studied cases (which was not statistically significant,  $p$  value = 0.10883).

Fig. 2. shows the change in staging in cases No. 1, 6, 7, 10, 18, 33, 36 and 49.

In one of the cases (No. 1) the lymph node stage was changed from N0 to N1bii and in 2 others (No. 7, 18) the lymph node stage changed from N1bi to N1bii.

Mean size of the lymph nodes by traditional and LNRS method was  $6.68 \pm 1.46$  and  $3.51 \pm 1.20$  mm respectively.

The mean number of isolated lymph nodes in 203 cases of breast cancer during the recent 5 years obtained by usual formalin fixation was  $13.192 \pm 5.893$  (average number of lymph nodes in breast specimens in our department).

These values showed that the number of lymph nodes isolated increased significantly by LNRS ( $p$  value  $< 0.01$ ) in comparison with the average of the department.

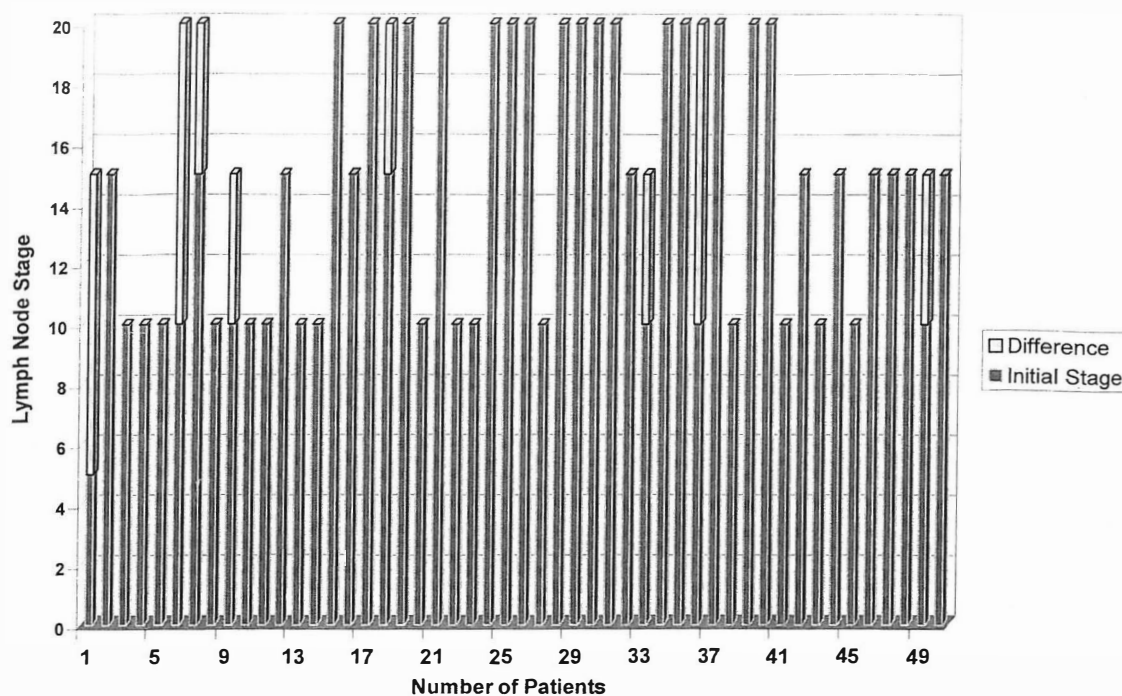


Fig. 2. Comparison of lymph node stage by the two methods.

## DISCUSSION

Prior to 1968 the prognosis of patients with primary breast cancer was related to the presence or absence of axillary lymph node involvement, with no regard for the number of nodal involvement. In that year, a report from the first clinical trial of the national surgical adjuvant breast and bowel project (NSABP) indicated that increasing numbers of positive axillary lymph nodes were associated with a greater incidence of treatment failure.<sup>2</sup>

Consequently all subsequent analysis of NSABP data, grouped patients with positive nodes into those having 1-3 and >4. So lymph node isolation, dissection and finding of lymph nodes in the axillary fat is an important task that must be done by the pathologist.

The routine method of palpation and lymph node isolation in 10% formalin may miss some of the lymph nodes, so clearing of axillary fat for demonstration of lymph nodes is a more practical technique.<sup>3-8</sup>

Several reports have proposed different protocols to enhance lymph node isolation.

Hida et al.<sup>5</sup> added Methylene-Blue to formalin followed by prolonged immersion in alcohol and acetone to reveal tiny lymph nodes by transillumination. Herrera-Ornales<sup>4</sup> used progressive concentrations of alcohol. Schmitz and colleagues<sup>7</sup> used acetone and xylol.

These various techniques are however time-consuming, expensive and demand specialized lab staff.

Fisher et al.<sup>9</sup> have demonstrated that increasing the number of removed axillary nodes doesn't increase the number of positive nodes. However increasing the number of the examined axillary lymph nodes did increase the number of patients demonstrating 4 or more positive nodes. When 10 or less lymph nodes are removed it is likely that those identified 1-3 positive nodes will actually have 4 or more positive nodes. Not infrequently less than 10 lymph nodes are identified.

In order to increase the number of identified lymph nodes, the fat clearing technique was introduced by Hartriet et al.<sup>10</sup> He used this method in 63 node negative breast specimens and found only one node containing a microscopic deposit of tumor that had not been identified by routine procedure.

Marrow et al.<sup>11</sup> used the fat clearing technique in 42 patients, however none of the added lymph nodes contained metastasis and the stage of disease was not changed.

Due to these findings investigators concluded that clearing of the axillary fat tissue wouldn't make a contribution to pathologic examination of the specimens obtained from the patients with breast cancer and the technique is indicated only at research settings. There are some reports in regard of colon cancer with identical results.<sup>12</sup>

On the contrary the results of several studies by Koren et al.<sup>13-16</sup> on breast, colon and bladder cancer showed that

## Use of Lymph Node Revealing Solution for Better Lymph Node Isolation

LNRS allows a more accurate staging in the assessment of the prognosis and need for adjuvant therapy.

Other studies<sup>17</sup> point to the effectiveness of this solution in rapid and good fixation of other surgical specimens like thyroid.

In view of these findings in the present study we used LNRS in an attempt to detect additional lymph nodes in a group of 50 cases of breast cancer.

After using LNRS the number of lymph nodes significantly increased. Although the number of metastatic lymph nodes per case was not significantly increased, in 8 cases the lymph node stage was changed, and in 3 of them TNM stage was also changed. This could have a major influence on the treatment modalities.

These results are similar to the results obtained by Koren et al.<sup>13,14,15,18</sup>

13 patients had less than 10 isolated nodes by traditional method, which after application of LNRS, in 30.8% of them the node stage was changed. The sizes of lymph nodes detected by LNRS were significantly smaller than those by traditional method.

We found that using LNRS can significantly enhance the average number of isolated lymph nodes per case. It seems that the use of LNRS in contrast to fat clearing method is suitable for routine use in the pathology lab at least when the number of isolated lymph nodes are too small to find probable metastatic nodes and then staging will be more accurate.

Furthermore fixation of lymph nodes for other purposes can be done by LNRS because the lymph nodes fixed by LNRS were qualitatively better than formalin-fixed cases.

LNRS is relatively inexpensive and easy to prepare and even the inexperienced pathology residents can easily recognize very small lymph nodes by LNRS.

### REFERENCES

1. Millis R, Hand MA, Oberman HA: The Breast. In: Sternberg SS, Antonioli DA, Carter D, Mills SE, Oberman HA, (eds.), Sternberg Diagnostic Surgical Pathology. New York: Wolters Kluwer Co., 1999.
2. Fisher B, Ravdin RG, Ausman RK, et al: Surgical adjuvant chemotherapy in cancer of breast. Results of a decade of cooperative investigation. *Ann Surg* 168: 337-356, 1968.
3. Cawthorn SJ, Gibbs NM, Marks CG: Clearance technique for the detection of lymph nodes in colorectal cancer. *Br J Surg* 73: 58-60, 1984.
4. Herrera-Ornales L, Justiniano J, Catillo N, et al: Metastasis in small lymph nodes from colon cancer. *Arch Surg* 122: 1253-6, 1987.
5. Hida J, Mori N, Kubo R, et al: Metastasis from carcinoma of the colon and rectum, detected in small lymph nodes by the clearing method. *J Am Coll Surg* 178: 223-8, 1994.
6. Mirikawa E, Yasutoni M, Shindou K, et al: Distribution of metastatic lymph nodes in colorectal cancer by the modified clearing method. *Dis Colon Rectum* 37: 219-3, 1994.
7. Shmitz-Moorman P, Thomas C, Phol C, et al: Anatomical demonstration of lymph node metastasis in surgical specimens. *Path Res Prac* 174: 403-11, 1982.
8. Scott KW, Grace RH: Detection of lymph node metastasis in colorectal carcinoma, before and after fat clearance. *Br J Surg* 76: 1165-7, 1989.
9. Fischer B, Wolmark N, Baver M, et al: The accuracy of clinical nodal staging and of limited axillary dissection as a determinant of histologic nodal status in carcinoma of breast. *Surg Gynecol Obstet* 152: 765-72, 1981.
10. Hartreit F, Siegal A, Klein B, Halpern JF: Routine histological investigation of axillary nodes in breast cancer. *Clin Oncol* 8: 121-6, 1982.
11. Marrow M, Evans J, Rosen PP, et al: Does clearing of axillary lymph nodes contribute to accurate staging of breast carcinoma? *Cancer* 53: 1329-32, 1984.
12. Jan Yi, Huang PC, Chen JT, Ho WL: Lymph node revealing solution and traditional 10% buffered formaldehyde for detecting lymph nodes in colorectal carcinoma. *Chung Hua 1 Hsueh Tsa Chin (Taipei)* 63(2): 131-7, 2000.
13. Koren R, Kyzer S, Paz A, et al: Lymph node revealing solution, a new method for detection of minute axillary lymph nodes in breast cancer specimens. *Am J Pathol* 21(11): 1387-90, 1997.
14. Koren K, Paz A, Konichevsky M, et al: Lymph node revealing solution: a rapid method for the isolation of cystectomy specimens. *Pathol Res Pract* 195(2): 77-80, 1999.
15. Koren R, Siegl A, Klein B, et al: Lymph node revealing solution: a new method for detecting minute lymph nodes in colon carcinoma. *Dis Colon Rectum* 40: 7-10, 1997.
16. Ustan MO, Onal B, Tugyan N, Rezanko T: Lymph node revealing solution: is it effective on detecting lymph nodes? *Adv Clin Pathol* 3(4): 135-8, 1999.
17. Wolfson R, Koren R, Yanir E, et al: A new technique for the fixation of thyroid gland surgical specimens. *Pathol Oncol Res* 5(1): 70-2, 1999.
18. Koren R, Paz A, Lask D, et al: Lymph node revealing solution: a new method for detecting minute lymph nodes in cystectomy specimens. *British J of Urology* 80: 40-43, 1997.