

Case Reports

MACRODYSTROPHIA LIPOMATOSA: CT AND MR FINDINGS

MARYAM RAHMANI, M.D., AND
MOHAMMADALI SHABANI, M.D.

*From the Department of Radiology, Emam Khomeini Medical Center,
Tehran University of Medical Sciences, Tehran, I.R. Iran.*

ABSTRACT

Macrodystrophia lipomatosa is a rare congenital form of localized gigantism characterized by an increase in all mesenchymal elements, particularly fibroadipose tissue. MR imaging can be used to examine the soft tissue and detect the fibrous and fatty hypertrophy that characterizes this condition and also diagnose an associated fibrolipomatous hamartoma of the median or plantar nerve. We describe the clinical and radiological findings (including CT scan, MRI and bone scan) and also progression of this rare entity during a 10 year period.

MJIRI, Vol. 16, No. 2, 111-114, 2002.

Keywords: Macrodystrophia lipomatosa (MDL), Fibrolipomatous hamartoma (FLH). Magnetic resonance imaging, Computed tomography

INTRODUCTION

Macrodystrophia lipomatosa (MDL) is a rare disease typically causing localized gigantism of an extremity, usually the hand or foot, and is characterized by an increase in all mesenchymal elements, particularly fibroadipose tissue.

In the hands, it is often associated with FLH of the median nerve. Patients are generally asymptomatic, but seek a physician's advice for cosmesis.

CASE REPORT

A 48-year-old right-hand-dominant woman presented with progressive enlargement & limitation of movement of her left second finger as her chief complaint since she was 10 years old. She had no pain or numbness. There was no family history of isolated extremity gigantism.

In physical examination, slight enlargement of the left arm and forearm was noted, the midhumeral circumference was 2cm larger than the right arm and there was great enlargement of the second and less so of the third finger with slight ulnar deviation (Fig. 1a).

No skin nodules, ulcer, pitting edema or cafe-au-lait spots were present. No audible bruits or thrills were heard

at the elbow or wrist or fingers. Allen test was negative. The results of neurologic and vascular examinations were unremarkable.

The patient had lichen-planus type lesions on her lower limbs since last year, but after reviewing the literature there was no relation between these two entities and we considered these as coincidental findings.

A radiograph of the left hand showed soft tissue swelling containing mottled lucencies around the second and to a lesser degree the third digit. No soft tissue or vascular calcification was seen. There was enlargement of the bony parts of all phalanges in the 2nd & 3rd fingers and to a lesser degree in the 2nd metacarpal with a preserved trabecular pattern, also osteochondromatose-like projections were present near the IP (interphalangeal) joints with extensive secondary DJD changes in the IP joints (Fig. 1b). Slow progression of these changes during the last 10 years, in comparison of the X-rays, was obvious (Fig. 1c), and in skeletal survey, no other bony changes of this type were noted.

In whole body isotope scan with Tc_{99m}, slight increased activity was observed in the left hand, over the second finger and metacarpal, corresponding to increased activity of mesenchymal elements (Fig. 2).

CT scan of the left upper limb was performed with a

Macrodystrophia Lipomatosa

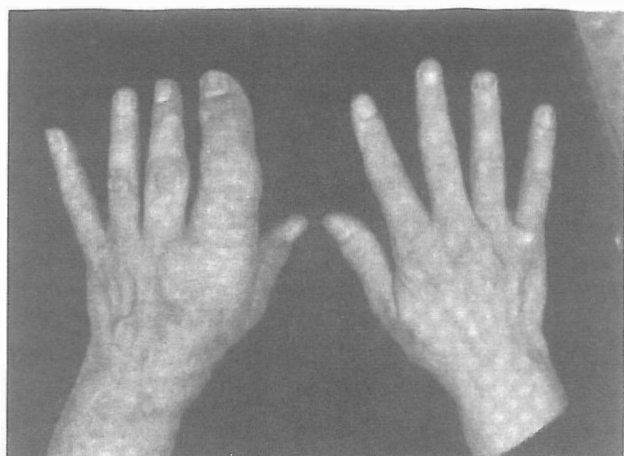


Fig. 1a. Photograph of the hands shows macrodactyly of the second digit of the left hand

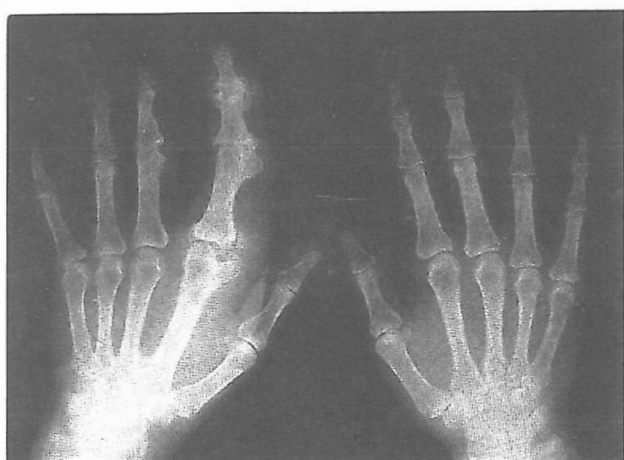

Fig. 1b. Radiograph of hands show soft tissue swelling and mottled lucencies around the index and middle fingers. Exostosis-like projections and secondary DJD changes in IP joints are also noted.

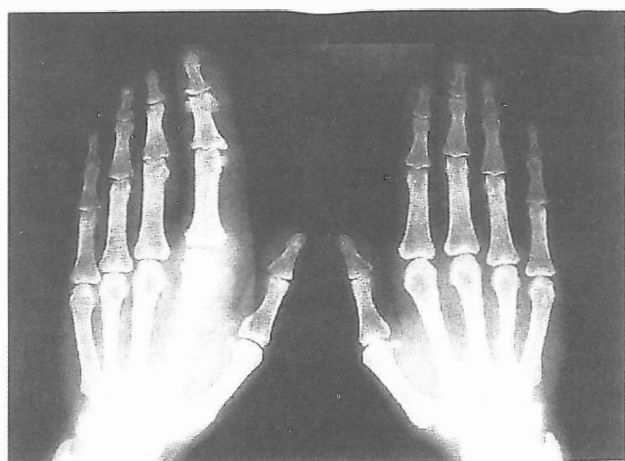

Fig. 1c. This is the radiograph of the patient's hands 10 years ago. In comparison with Fig. 1b progression is obvious.

spiral Toshiba CT scan, X vision, which showed asymmetric accumulation of adipose tissue (-100 Hu) in the 2nd & 3rd fingers, more in the tip of the finger than the base, and also in the wrist and less in lateral parts of the arm and forearm (Fig. 3a, b).

MR imaging performed with a G.E. 1.5T scanner showed asymmetric fat infiltration with similar intensity as subcutaneous fat without any obvious capsule or nerve involvement, including nerve hypertrophy or carpal tunnel syndrome, no medullary abnormality was identified (Fig. 4a,b).

Angiography was not performed, as it has been proven to be nonspecific.¹⁰

DISCUSSION

Macrodystrophia lipomatosa (MDL) was first described in 1925 by Friz.¹ It is a rare, unilateral, nonhereditary condition involving one or more digits of the extremities in distribution of the median nerve in the upper limb, or plantar nerve in the lower limb. Most often the middle and index fingers are involved.^{2,6}

Most reported cases were present at birth and associated with a high incidence of anomalies including syndactyly, polydactyly, and clinodactyly.³ Digital overgrowth ceases at puberty with MDL and cosmesis is the primary reason for surgery.⁵

The differential diagnosis includes neurofibromatosis type I, hemangiomatosis, lymphangiomatosis, and Klippel Trenaunay-Weber syndrome.¹⁷ In general, the clinical history and a thorough physical examination can help to distinguish these entities. Neurofibromatosis can be diagnosed by a positive family history and cutaneous cafe-au-lait spots. Bony changes in neurofibromatosis include thinned bone shafts and wavy cortices.⁴

Also a plexiform neurofibroma produces an enlarged,

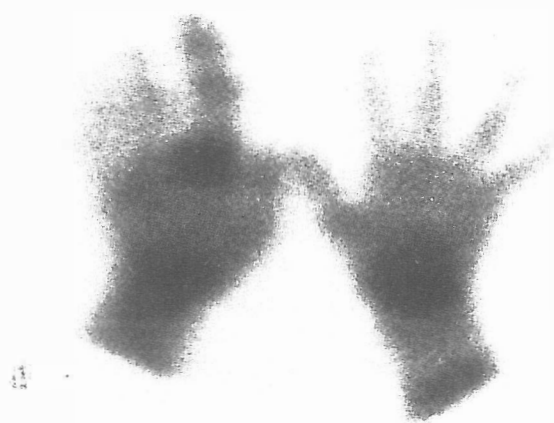

Fig. 2. Isotope bone scan with Tc99 shows mild increased activity over the second finger and metacarpal.

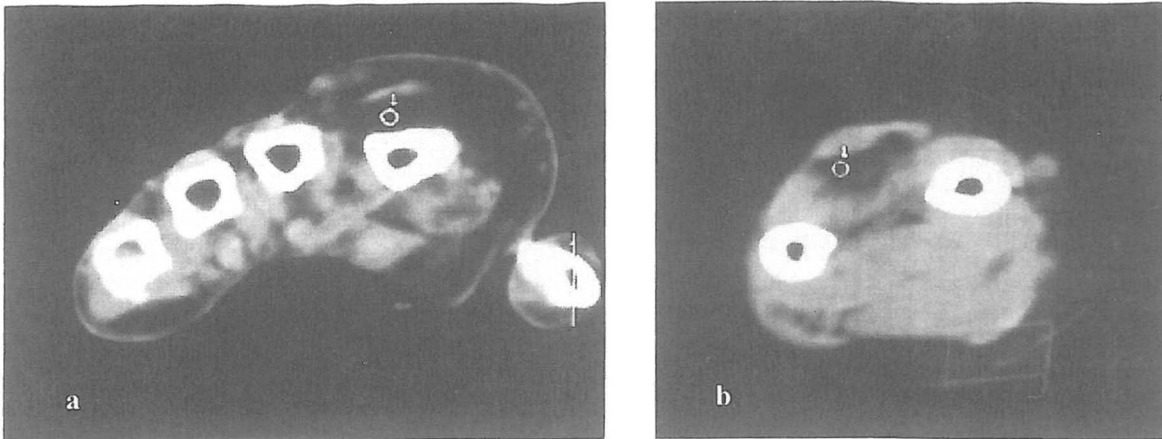


Fig. 3. CT scan of the fingers (a) and forearm (b) shows asymmetric fat accumulation (-99Hu).

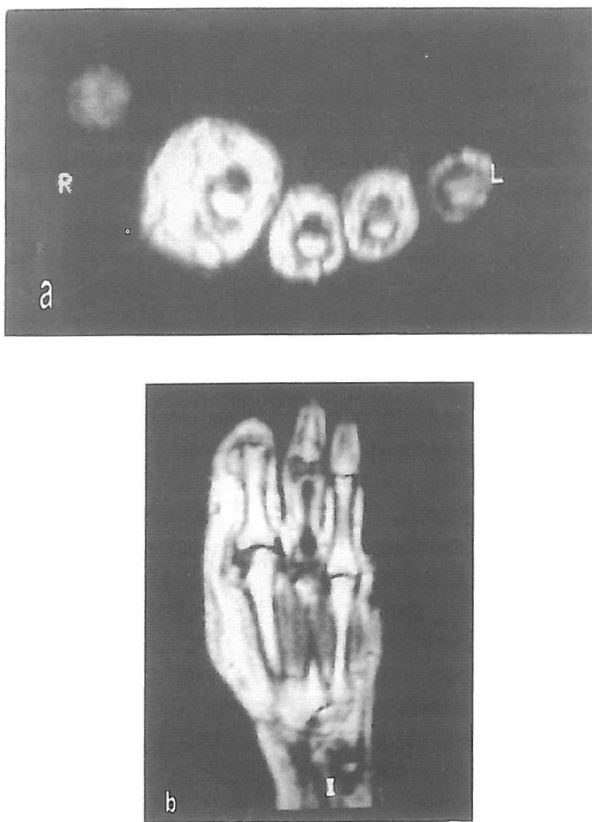


Fig. 4. Axial (a) and coronal (b) T1 MRI FSE images demonstrate fatty hypertrophy around the index and less around the middle finger, without evidence of a capsule. No increased intensity in T2 images noted.

tortuous nerve studded by soft tissue nodules pathologically; demonstration of fat within the nerve sheath on MRI excludes the possibility of neurofibromatosis.⁵ In MR imaging, neurofibromas show marked hyperintensity on T2 - weighted images and are close to the nerves.⁷

Klippel - Trenaunay - Weber syndrome can be diagnosed on the basis of its characteristic cutaneous capil-

lary hemangiomas and varicose veins. Diffuse swelling and pitting edema are often seen with lymphangiomatosis and on MRI, high signals on T1 (relative to muscle) and low signals on T2 (relative to fat) are seen.⁸ A bruit may be auscultated with hemangiomatosis, and in addition, one would expect a heterogenous hyperintense lesion on T2-weighted sequences that correspond to the interconnecting vascular channels separated by variable amounts of supporting connective tissue.^{9,10}

Fibrolipomatose hamartoma of nerves occasionally can be seen in association with macrodactyly. Indeed, 27-66% of patients with FLH show macrodactyly of either fingers or toes.^{11,12} Conversely, Tsuge & Ikut¹³ studied 27 patient with Macrodystrophia Lipomatosa and reported underlying nerve abnormalities microscopically indistinguishable from FLH in all of them.

MRI findings of FLH consist of fusiform nerve enlargement caused by thickened nerve bundles embedded in fatty tissue (not seen in our patient).¹⁴ When nerve involvement is present distinction between MDL & FLH becomes quite difficult, as these two conditions are indistinguishable on CT and MRI and pathology.¹⁵ Based on Sawhney and Berry's report, the appearance of MDL on CT scan is also diagnostic.¹⁶

The main principle in treating this lesion surgically should be improving cosmetic appearance and preserving neurologic function.¹⁵

In conclusion MRI remains uniquely suited in its ability to provide accurate soft-tissue characterization to assist in the work-up and evaluation of macrodactyly and peripheral nerve tumors. Correlation of the MRI appearance with the clinical presentation and physical findings should confirm this unusual diagnosis.^{15,17}

REFERENCES

1. Feriz H: Macrodystrophia lipomatosa progressive. *Virchows Arch* 260: 308-368, 1925.

Macrodystrophia Lipomatosa

2. Barsky AJ: Macroductyly. *J Bone Joint Surg* 49A: 1255-1265, 1967.
3. Hildebrandt JW, Olson P, Paratained H, Griffiths HJ: Macrodystrophia lipomatosa. *Orthopedics* 16: 1075-1077, 1993.
4. Blacksin M, Barnes FJ, Lyons MM: MR diagnosis of macrodystrophia lipomatosa. *AJR* 158:1295-1297, 1997.
5. Boren W, Henry REC, Wintch K: MR diagnosis of fibrolipomatous hamartoma of nerve: association with nerve territory-oriented macroductyly (Macrodystrophia lipomatosa). *Skeletal Radiol* 24: 296-297, 1995.
6. Kelikian H: Congenital deformities of the hand and forearm. Philadelphia: Saunders, pp. 610-635, 1974.
7. Cerofolini E, Landi A, Desantis G, Maiorana A, Cenossi G, Romagnoli R: MR of benign peripheral nerve sheath tumors. *J Comput Assist Tomogr* 15: 593-597, 1991.
8. Kransdort MJ, Jelinek JS, et al: Soft-tissue masses: diagnosis using MR imaging. *AJR* 153: 541-547, 1989.
9. Suh JS, Abenoza P, Galloway HR: Peripheral (extracranial) nerve tumors: correlation of MR imaging and histologic findings. *Radiology* 183: 341-346, 1992.
10. Guthikonda M, Rengachary SS, Balko MG, van Loveren H: Lipofibromatous hamartoma of median nerve: case report with MRI correlation. *Neurosurgery* 35: 127-131, 1994.
11. Silverman TA, Enzinger FM: Fibrolipomatous hamartoma of nerve: a clinicopathologic analysis of 26 cases. *Am J Surg Pathol* 9: 7-14, 1985.
12. Amadio PC, Reiman HM, Dobigins JH: Lipofibromatous hamartoma of nerve. *J Hand Surg (A)* 130: 67-76, 1988.
13. Tsuge K, Tkuta Y: Macroductyly and fibro-fatty proliferation of the median nerve. *Hiroshima Med Sci* 22: 22-28, 1973.
14. De Maseneer M, Jaovisidha S, Lenchik L, Witte D, Schweitzer ME, Sartoris DJ, Resnick D: Fibrolipomatous hamartoma: MR imaging findings. *Skeletal Radiol* 26: 155-160, 1997.
15. Brodwater BK, Major NM, Goldner RD, Layfield LJ: Macrodystrophia with associated fibrolipomatous hamartoma of median nerve. *Pediatr Surg Int* 16: 216-218, 2000.
16. Jain R, Sawhney S, Berry M: CT diagnosis of macrodystrophia lipomatosa. *Acta Radiology* 33, 6, 1992.
17. Sone M, Ehara S, Tam Akaw Y, Nishida J, Hungoh S: Macrodystrophia lipomatosa: CT & MR findings. *Radiat Med Mar. Apr*; 18(2): 129-32, 2000.