

# HENOCH-SCHONLEIN PURPURA IN CHILDREN: OUR EXPERIENCE WITH 165 CASES FROM SOUTHERN IRAN

M. HAGHIGHAT, M.D., G. HASHEMI, M.D.,  
AND L. HASHEMI, M.D.

*From the Department of Pediatric Gastroenterology and Nephrology,  
Shiraz University of Medical Sciences, Shiraz, I.R. Iran.*

## ABSTRACT

During a 6 year period from September 1992 to September 1998, 165 children with a final diagnosis of Henoch-Schonlein purpura (HSP) were managed and followed in our center.

There were 87 (52%) boys and 78 (48%) girls, with age ranges of 1-16 years and mean age of 7.8 years. Forty-one percent of the patients had evidence of preceding upper respiratory tract infection (URI). The main clinical features were: skin eruption in 100%, GI symptoms in 79.5%, joint problems in 59.5% and renal involvement in 26.5% of cases.

Thrombocytosis in 31% and increased ESR in 55% of cases were the main significant laboratory findings. Abdominal sonography was done in 58 cases with GI symptoms, and was abnormal in 28 cases (48%): free peritoneal fluid in 26%, thickened bowel wall in 14%, ileus in 5% and intussusception in 3%. Sixty percent of the patients received prednisolone for GI problems or renal involvement. Nine percent of the cases had relapse and there was no death.

It was concluded that:

- a) There is no significant sex difference in children with HSP in this area.
- b) The age of children with HSP in this area is the same as those in eastern countries, but relatively higher than that reported in western countries.
- c) Abdominal sonography can be a helpful means of diagnosis in patients with GI manifestations of HSP before skin eruption.
- d) The morbidity and mortality of HSP is very low if the disease is diagnosed in its early stages and managed properly.

*MJIRI, Vol. 16, No. 1, 5-8, 2002.*

**Keywords:** Henoch-Schonlein purpura, Children, Ultrasonography, Mortality and Morbidity.

## INTRODUCTION

Henoch-Schonlein purpura (HSP) or anaphylactoid purpura is a systemic vasculitis of unknown etiology that is characterized by purpuric rash, arthritis, nephritis and gastrointestinal symptoms (abdominal pain, GI bleeding).<sup>1-5</sup>

HSP is a disease of children and young adults (age range 5-15 years) that occurs twice as commonly in males compared to females.<sup>2, 5-6</sup>

Although most children with HSP have the clinical triad of purpura, GI symptoms (colicky abdominal pain or GI bleeding) and arthritis, up to 50% of cases may present with symptoms other than purpura.<sup>7</sup>

There is no single, gold standard diagnostic test for HSP, however the diagnosis is not difficult when the classic triad of typical skin rash, GI manifestations, and hematuria or arthritis is present.

HSP is a benign, self limited disease in the majority of

cases, but may be complicated with GI (GI bleeding, perforation or intussusception) or renal involvement. We carried out a prospective study to evaluate the age and sex distribution, clinical presentation and clinical course (morbidity and mortality) in 165 consecutive children with HSP.

## MATERIAL AND METHODS

During a 6 year period from Sept. 1992 to Sept. 1998, 165 children with final diagnosis of HSP were managed and followed in our center. The diagnosis was made by observing the typical skin rash with one of the following: GI manifestations (abdominal pain or GI bleeding), arthritis or arthralgia or signs and symptoms of renal involvement. Their records were reviewed for: age and sex distribution, clinical presentation and physical findings, significant laboratory changes, ultrasonographic (US) findings and course of the disease.

## RESULTS

Of 165 children with HSP, 87 (52%) were boys and 78 (48%) were girls (male to female ratio was 1.1:1). The mean age at presentation was 7.8 years (range 1-16 years). Seventy-seven percent of the patients were older than 5 years (Fig. 1). Forty-one percent of cases had evidence of a preceding URI.

### Clinical presentation

The clinical presentations of our cases are shown in Figs. 1-5 and Table I. Although all of our patients (100%) developed a typical skin rash, only 75 cases (45.5%) had skin eruptions at the time of presentation (Fig. 2 and Table I).

Edema of the hands and feet, around the mouth, lips and face was present in 73 (44%) cases, and 14 cases of these also had scrotal edema. 131 cases (79.5%) had GI manifestations (Fig. 3). In 61 cases (37%) GI symptoms presented before skin eruption. 5 cases had concomitant skin rash and GI symptoms and 2 cases had intussusception. Joint involvement (arthritis and arthralgia) were present in 98 cases (59.5%) (Fig. 4). In 16 cases (10%), joint involvement was the first clinical presentation. 8 cases had concomitant joint and skin involvement. 44 cases (26.5%) had renal involvement, 38 of them had nephritis and 6 had nephrotic syndrome. Seven cases developed chronic renal failure. No patient had renal involvement at presentation. Thrombocytosis in 51 cases (31%) and increased ESR in 91 cases (55%) were the main significant laboratory findings. Kidney biopsy was done in 10 cases, showing histopathologic changes compatible with vasculitis. Endoscopy was done in 13 cases with GI bleeding, and was abnormal in 12 cases (93%). Endoscopic findings were: petechial eruption, mucosal erosion and superficial ulceration in the stomach or duodenum. Abdominal US was done in 58 cases with abdominal pain at

presentation, and was abnormal in 28 cases (50%). Intrapertitoneal fluid in 15 cases, thickening of bowel wall in 8 cases, ileus in 3 cases and intussusception in 2 cases were the ultrasonographic findings (Fig. 5).

### Management

Management was mainly supportive. ASA was given for joint pain and steroids used in 99 cases (60%) with severe abdominal pain, GI bleeding or renal involvement. 9 cases (3.5%) with severe abdominal pain were operated, of these 2 had intussusception, 2 had gangrene of bowel loops, and in the remaining 5 cases there was no significant pathologic finding. Recurrence of HSP was noted once in 13 cases (8%) and twice in 2 cases. None of our patients died.

## DISCUSSION

Henoch-Schonlein purpura is known to affect more boys than girls.<sup>1-8-10</sup> In our series the male/female ratio was 1.1: 1, in contrast with above reports, but the same as those reported by Al-Harbi<sup>11</sup> from Saudi Arabia and Blazer et al.<sup>12</sup>

In our series the mean age was 7.8 years (age range 1-16 years). Seventy-seven percent of them were older than 5 years. We found that the disease affects an older age group in this area compared to that reported previously<sup>9,13-14</sup> mainly from western countries, with 50% under 5 years of age at the time of presentation. The age range of our patients are relatively the same as those reported by Al-Rasheed,<sup>9</sup> Al-Harbi<sup>11</sup> from Saudi Arabia and Wang from China.<sup>10</sup> The higher age of involvement in our patients suggests that the epidemiology of HSP in our area may be the same as in other eastern countries and different from western areas.

We found that the clinical presentation of our patients is relatively similar to other parts of the world.<sup>2-6,10,11</sup> A higher percentage of our cases presented with GI symptoms as compared with other reports.<sup>9,13-14</sup>

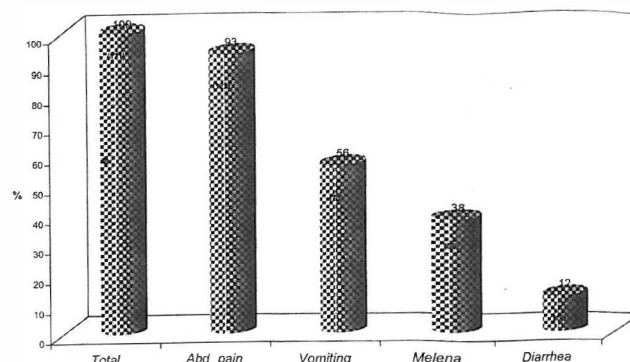
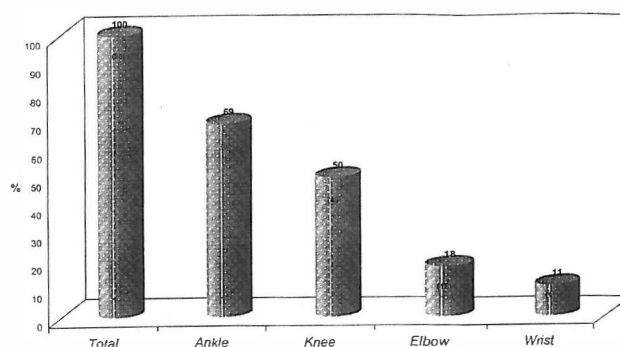
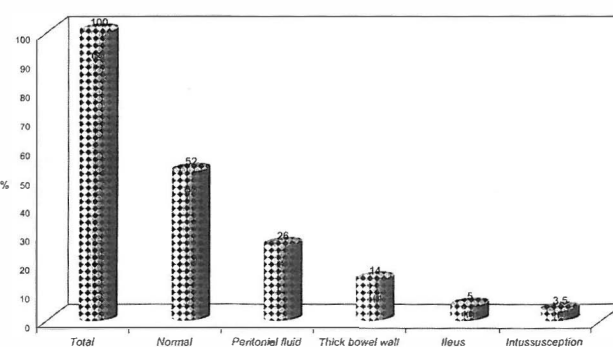
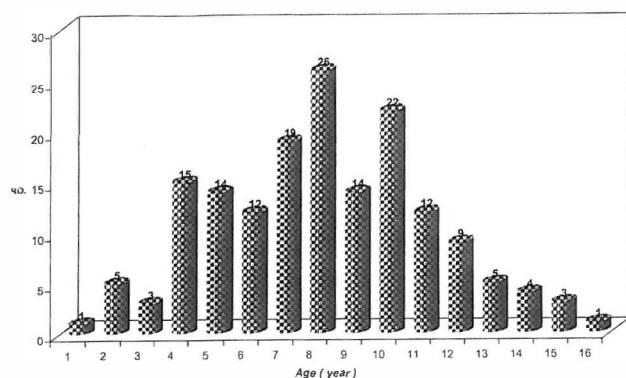
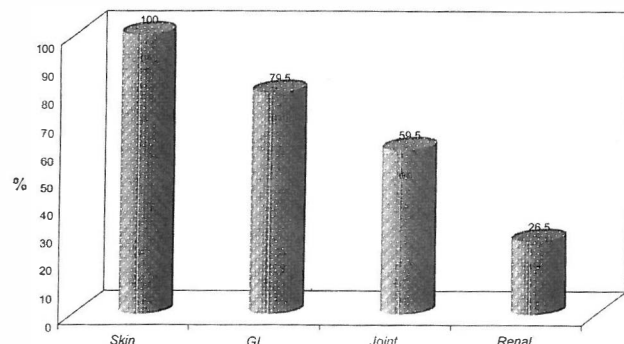
In our series, 65% had thrombocytosis and 55% had an increased ESR. These findings have been reported previously too.<sup>5</sup> Endoscopic findings in this study were the same as reported by others.<sup>15</sup> Fifty percent of our patients with abdominal pain had significant ultrasonographic findings, which have been reported previously by others also.<sup>15,16</sup> As noted in our study and reported in other similar studies, a significant number of cases of HSP presented with colicky abdominal pain before skin rash. In these cases US seems to be the imaging modality of choice for abdominal evaluation, mainly in those who are candidates of surgical intervention.<sup>1,5,16</sup>

It is concluded that:

- There is no significant sex difference in children with HSP in this area.
- The age of children with HSP in this area is the same as those in eastern countries, but relatively higher than those reported in western countries.

**Table I.** Early clinical presentation in 165 children with HSP.

Clinical Presentation	No.	Percent
Skin	75	45
GI	61	37
Joint	16	10
Skin and Joint	8	5
Skin and GI	5	3
Renal	0	0
Total	165	100

**Fig. 3.** GI manifestations in 165 cases with HSP.**Fig. 4.** Joints involved in patients with HSP.**Fig. 5.** Ultrasonographic findings in children with HSP.**Fig. 1.** Age distribution of 165 cases with HSP.**Fig. 2.** Clinical manifestations of 165 children with HSP.

c) Abdominal sonography can be a helpful means of diagnosis in patients with GI manifestations of HSP before skin eruptions.

d) The morbidity and mortality of HSP is very low if the disease is diagnosed in early stages and managed properly.

## REFERENCES

1- Connolly B, O'Halpin D: Sonographic evaluation of the abdo-

men in Henoch-Schonlein purpura. *Clinical Radiology* 49: 220-230, 1994.

2- Al-Sheyyab M, El-Shanti H: The clinical spectrum of Henoch-Schonlein purpura in infants and young children. *Eur J Pediatr* 154: 969-972, 1995.

3- Ben-Chaim J, Kovat E, Shenfeld O: Acute scrotum caused by Henoch-Schonlein purpura. *Journal of Pediatric Surgery* 30 (10): 1509-10, 1995.

4- Gow KW, Murphy III JJ, Blair GK: Multiple enteroenteric fistulae: an unusual complication of Henoch-Schonlein purpura. *Journal of Pediatric Surgery* 31 (6): 809-11, 1996.

5- Kraft DM, McKee D, Scoff C: Henoch-Schonlein purpura:

## Henoch-Schonlein Purpura in Iran

- a review. *American Family Physician* 58 (2): 405-8, August 1998.
- 6- Blanco R, Martinez-Taboada VM, Roderiguez-Valverde V, et al: Henoch-Schonlein purpura in adulthood and childhood. *Arthritis and Rheumatism* 40 (5): 850-64, 1997.
  - 7- Szer IS: Henoch-Schonlein purpura: when and how to treat. *The Journal of Rheumatology* 23 (2): 233-9, 1996.
  - 8- Kanakriyeh MS, Madanaf FF: A review of Henoch-Schonlein purpura. *Jordan Med J* 16: 35-8, 1982.
  9. Al-Rasheed SA, Abdurahman MB: Henoch-Schonlein purpura in Saudi Arabia. *J Trop Pediatr* 37: 127-31, 1991.
  10. Wang YT, Shian WT: Clinical studies of Henoch-Schonlein purpura in Chinese children. *Change Hua t Hsueh Tsa Chih Taipei* May 51 (5): 345-9, 1993.
  11. Al-Harbi NN: Henoch-Schonlein syndrome in children: experience from Southern part of Saudi Arabia. *East African Medical Journal* 73 (3): 191-3, 1996.
  12. Blazers Alonu U, Berant M: Henoch-Schonlein purpura: paucity of renal disease. *Isr J Med Sci* 17: 41-5, 1981.
  13. Allen DM, Diamond LK, Howell DA: Anaphylactoid purpura in children. *Amer J Dis Child* 98: 833-6, 1960.
  14. Dawod ST, Akik F: Henoch-Schonlein syndrome in Qatar. *Ann Trop Pediatr* 10: 285-9, 1990.
  15. Kato S, Shibuya H: Gastrointestinal endoscopy in Henoch-Schonlein purpura. *Eur J Pediatr* 151: 482-4, 1992.
  16. Couture A, Veyrac C: Evaluation of abdominal pain in Henoch-Schonlein syndrome by high frequency ultrasound. *Pediatr Radiol* 22: 12-17, 1992.