

# PHAEOHYPHOMYCOSIS OF THE SINUSES AND CHEST BY *CLADOSPORIUM BANTIANUM*

S. BASIRI JAHROMI, A. KHAKSAR, AND K. IRAVANI\*

From the Department of Medical Mycology, Pasteur Institute of Iran, Tehran, and the E.N.T. Ostad Motahari Hospital, Jahrom University of Medical Sciences, Jahrom, Islamic Republic of Iran.

## ABSTRACT

Fungal sinus infections are being recognized with increasing frequency. We report a case with rhinocerebral and chest phaeohyphomycosis infection caused by *Cladosporium bantianum* in an 18 year old man with Wegener's granulomatosis. The diagnosis was established by histopathological appearance, direct examination, culture and computerized tomography (CT) scan. This case was successfully treated by a combination of surgery and amphotericin B. The present that is of paranasal sinus mycosis due to *Cladosporium bantianum* is the first that is reported in Iran.

*MJIRI*, Vol. 16, No. 1, 55-58, 2001.

**Keywords:** Fungal infection, Paranasal sinus infection, *Cladosporium bantianum*, Phaeohyphomycosis.

## INTRODUCTION

Dematiaceous fungi also infect internal organs. In cerebral infections caused by *Cladosporium bantianum* (*Xylohypha bantiana*), the most commonly encountered agent in systemic phaeohyphomycosis, there is characteristically a mixed purulent and granulomatous inflammatory reaction with abscess formation.<sup>1,4</sup> The teleomorph is not known. Saccardo (1912) described *Torula bantiana*<sup>13</sup> which had been isolated by Banti (1911) as an etiological agent of a human case of cerebral phaeohyphomycosis.<sup>13</sup>

Phaeohyphomycosis is a cosmopolitan disease. The disease has been reported from most parts of the world. Aside from human cases, infections have also been diagnosed in fish, birds, cats, and horses. The clinical forms of phaeohyphomycosis fall into two basic types; subcutaneous and systemic. Infections generally occur in compromised or debilitated hosts. In subcutaneous phaeohyphomycosis, abscesses or verrucous lesions may develop on various parts of the body.

Most lesions caused by this fungus are found in the white matter of the frontal lobe of the cerebrum. The lungs and other organs are only rarely involved.<sup>5</sup> The brain abscesses may be single or multiple and may measure up to 5 cm in diameter; they are composed of a central zone of neutrophils and necrotic debris enveloped

by a thick wall of multinucleated giant cells, epitheloid cells, plasma cells, and lymphocytes. The abscesses may or may not be sharply circumscribed, and they usually stimulate varying degrees of peripheral gliosis. Single hyphae and clusters of dematiaceous, septate, moniliform hyphae are found extracellularly in the central purulent exudate and intracellularly within huge giant cells that form the wall of the abscess. In some instances, the necrotic and liquified center of an abscess contains few if any fungal elements, whereas the surrounding granulomatous tissue contains numerous dematiaceous hyphae that are easily detected. Granulomatous leptomeningitis due to *C. bantianum* without involvement of the brain parenchyma, occurs rarely.<sup>6</sup> Borges et al. reported a case of localized pulmonary phaeohyphomycosis caused by *Cladosporium bantianum* (as *Xylohypha bantiana*).<sup>14</sup>

## CASE REPORT

The patient was an 18-year-old male worker, resident in Garmsar whose underlying disease was histologically proven as Wegener's disease. He had a long history of nasal obstruction and chronic sinusitis, headache, lacrimation, nasal congestion, nasal discharge, high fever, cough, hemoptysis and a mass in the left side of the chest and a black necrotic lesion with perforation of the middle hard palate. He had a secondary palate defect 2.5-6.5

centimeters in diameter (Fig. 1). His problem began when he was 16-years-old with lacrimation, at which time he underwent D.C.R. (Dacryocystorhinostomy). CT scan of the paranasal sinuses showed inflammation in the maxillary sinus and erosion beginning from the medial wall of the sinus. Obstruction extended to the right nasal cavity and hard palate (Fig. 2). Biopsy specimens from the hard palate and mass of the left side of the chest were cultured on Sabourad's dextrose agar. Sabouraud's dextrose agar, with chloramphenicol (50 mg/mL), blood agar and brain heart infusion agar (BBL). Duplicate cultures on each medium were incubated at 35°C and 25°C. Culture of the specimens gave rise to *Cladosporium bantianum*. Microscopic features of the isolates were studied by slide

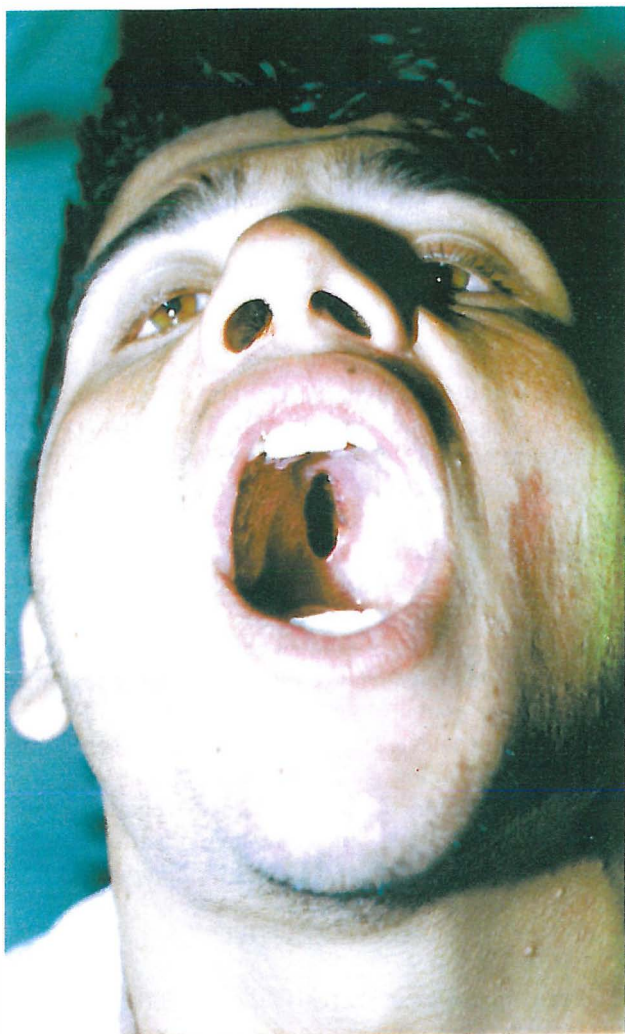


Fig. 1. Necrosis and perforation of the palate due to fungal infection.

culture preparation. *Cladosporium bantianum* colonies were identified as initially velvety, irregularly folded at the center and greyish-black in colour (Fig. 3).

Microscopic examination showed brown, septate, sparsely branched conidiophores producing a long, flexuous chain of conidia. Conidia are brown, elongate to elliptical, and 2-4  $\mu\text{m} \times 2-2.5 \mu\text{m}$  in size. The mycelial elements are bizarre in shape and size (Fig. 4). The subculture medium was incubated at 43°C, it's growth attained at this temperature.

Gelatin media was used for identification of *C. bantianum*. *Cladosporium bantianum* did not liquify gelatin. These characteristics separate it from *Cladosporium Spp*. However, McGinnis and Borelli<sup>17</sup> maintain that the morphology of *C. bantianum* is so distinct that it is not easily confused with other species.<sup>18</sup>

Histology of a portion of the hard palate lesion and chest mass revealed scattered giant cells containing fungal fragments and other inflammatory cells such as lymphocytes.

The patient underwent a 30-day course of intravenous amphotericin B (1mg/kg/day), and surgical debri-

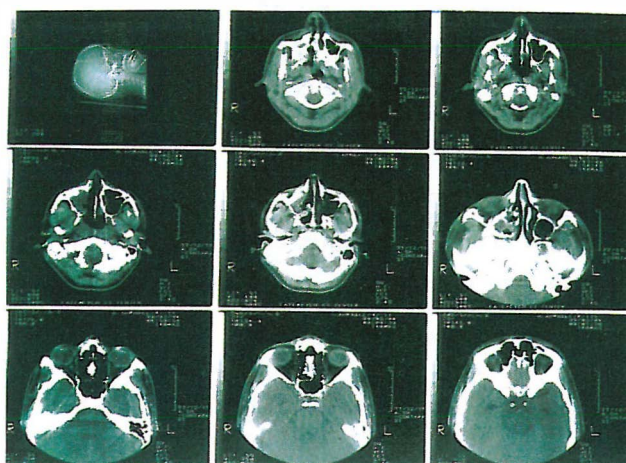


Fig. 2. Axial post-contrast CT demonstrating erosion of the hard palate, involving the nasal cavity and L. maxillary sinus.

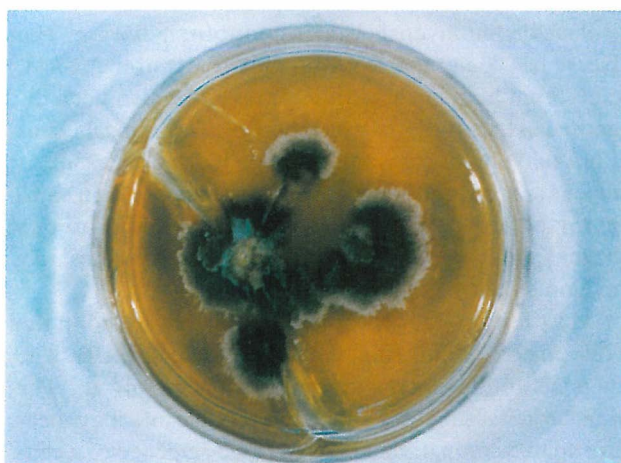

Fig. 3. Sabouraud's dextrose agar. 10 days.



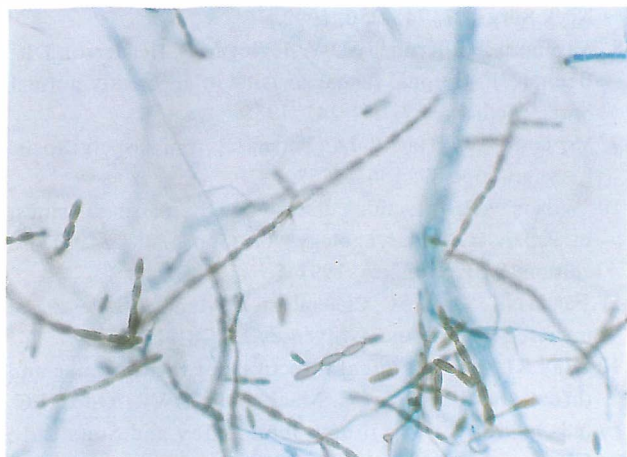


Fig. 4. Branching chains of conidia.

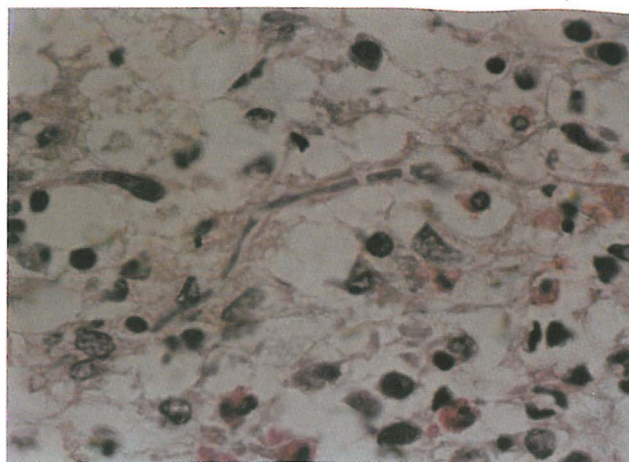


Fig. 6. Fungal elements in chest mass. Hematoxylin and Eosin.

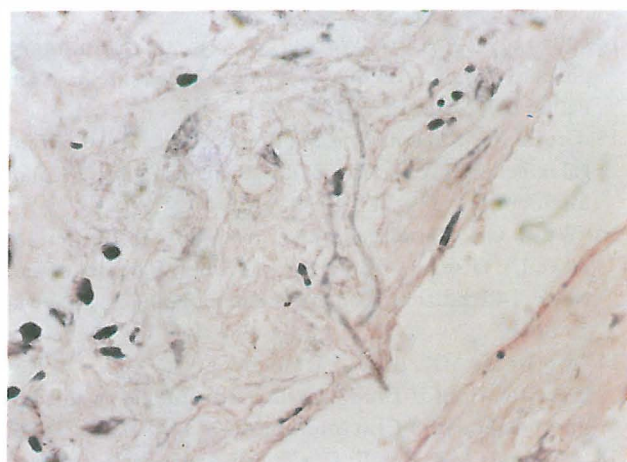


Fig. 5. Fungal elements in sinus tissue. Hematoxylin and Eosin.

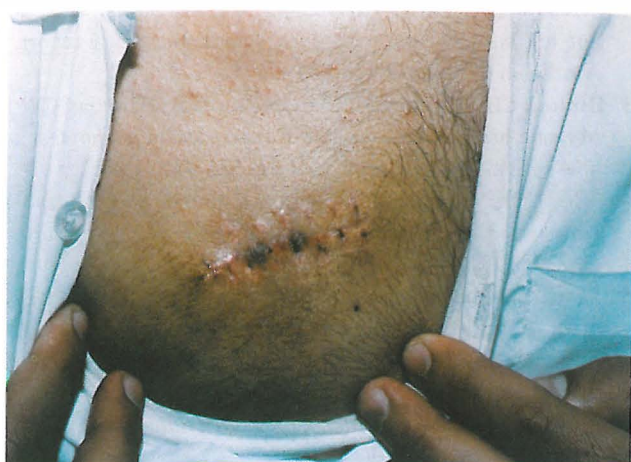

Fig. 7. Chest mass after surgery.

dement of the sinuses and chest were performed as effective management. The patient's condition improved clinically. Then the oronasal defect was repaired by reconstructive surgery. The method of reconstruction was bipedicle flap closure of the defect.

### DISCUSSION

Paranasal sinus mycosis is being recognized more frequently in different parts of the world because of increased awareness. A significantly higher incidence is reported in the restricted zones of North Sudan, the middle East and in the South-Western States of the U.S.A., which have a warm and dry climate.<sup>7,8,9,12</sup>

Infections of the paranasal sinuses caused by fungi are uncommon, although in 3-5% of cultured samples of sinus material obtained by lavage or at surgery, fungi are present.<sup>15</sup> Infections are of two very different orders

of magnitude based on whether they are noninvasive or invasive in character, that is, if fungal forms are found within tissue.<sup>10</sup> Fungal sinusitis in an immunocompromised individual is a medical emergency because death or severe complications such as blindness or permanent cranial nerve palsies can occur within 2 to 5 days.<sup>16</sup>

The main organisms are *Candida* and *Aspergillus* species, and less commonly *Zygomycete* or other mould fungi.<sup>10-12</sup> Possibly dust and frequent sand storms during the summer months contain large numbers of fungal conidia that can easily settle on the injured mucosa of the sinuses of young men working outdoors who are exposed to the warm dry climate.<sup>11</sup> The maxillary and ethmoid sinuses were more commonly involved because drainage depends on mucociliary propagation in these sites.<sup>12</sup>

The present report constitutes the first record of

paranasal and chest phaeohyphomycosis with *C. bantianum* in a patient with Wegener's disease in Iran. Wegener's granulomatosis is an unusual but not rare disease that is potentially fatal and is commonly seen at about 40 years of age. The disease is characterized by a focal necrotizing vasculitis that affects the upper and lower respiratory tracts, skin, joints, and kidneys. The cause is unknown, but it may represent an unusual form of autoimmune response.<sup>10</sup> Our patient survived with antifungal treatment (amphotericin B, 1mg/kg daily) and surgical debridement.

#### REFERENCES

1. Jong SS, Biberstein EL, Rinaldi MG, Henness AM, Boorman GA, Taylor RF: Feline abscess due to *Cladosporium trichoides*. *Sabouraudia* 15: 115-123, 1977.
2. Crichlow DK, Enrile FT, Memon MY: Cerebellar abscess due to *Cladosporium trichoides (bantianum)*: case report. *Am J Clin Pathol* 60: 416-421, 1973.
3. Binford CH, Thompson RK, Gorham ME, Emmons CW: Mycotic brain abscess due to *Cladosporium trichoides*, a new species. *Am J Clin Pathol* 22: 535-542, 1952.
4. Riley O Jr, Mann SH: Brain abscess caused by *Cladosporium trichoides*: review of 3 cases and report of a fourth case. *Am J Clin Pathol* 33: 525-531, 1960.
5. Limsila T, Stitumankaru T, Thasnakorn P: Pulmonary cladosporoma. Report of a case. *J Med Assoc Thailand* 53: 586-590, 1970.
6. Bennett JE, Bonnet H, Jennings AE, Lopez RI: Chronic meningitis caused by *Cladosporium trichoides*. *Am J Clin Pathol* 59: 398-407, 1973.
7. Chakrabarti A, Sharma SC, Chander J: Epidemiology and pathology of paranasal sinus mycoses. *Otolaryngol Head Neck Surg* 107: 745-750, 1992.
8. Washburn RG, Kennedy DW, Begley MG, Henderson DK, Bennett JE: Chronic fungal sinusitis in apparently normal hosts. *Medicine* 67: 231-247, 1988.
9. Mc Guirt WF, Harrill JA: Paranasal sinus aspergillosis. *Laryngoscope* 89: 1563-1568, 1979.
10. Wilson WR: Infectious diseases of the paranasal sinus. In: Paparella's otolaryngology, Vol. 3, pp. 1848-1849, Third edition, W.B. Saunders, 1991.
11. Panda NK, Sarma SC, Chakrabarti A, Mann SBS: Paranasal mycoses in north India. *Mycoses* 41: 281-286, 1998.
12. Hay RI, (eds.): Fungal infections of the ear, nose and throat. In: Kibbler CC, Mackenzie OWR, Odds FC, (eds.), *Clinical Mycology*. John Wiley and Sons Ltd., Chichester, pp. 131-142, 1996.
13. Matsumoto T, Ajello L: Agent of phaeohyphomycosis. In: Ajello L, Hay RJ, (eds.), *Medical Mycology*. Ninth edition. Volume 4, 503-524, 1998.
14. Borges MC Jr, Warren S, et al: Pulmonary phaeohyphomycosis due to *Xylohypha bantiana*. *Arch Pathol Lab Med* 115: 627, 9, 1991.
15. Greval RS, Khurana S, Aujla KS, et al: Incidence of fungal infections in chronic maxillary sinusitis. *Indian J Pathol Microbiol* 33: 339-343, 1990.
16. White GA: Paranasal sinus infections. In: Ballenger JJ, (ed.), *Diseases of the Nose, Throat, Ear, Head, and Neck*, 14th edition, London: Lea and Febiger, pp. 191-5, 1991.
17. McGinnis MR, Borelli D, Padhye AA, Ajello L: Re-classification of *Cladosporium bantianum* in the genus *Xylohypha*. *J Clin Microbiol* 23: 1148-1151, 1986.
18. McGinnis MR, Borelli D, *Cladosporium bantianum* and its synonym *Cladosporium trichoides*. *Mycotaxon* 13: 127-136, 1981.