



The Diagnostic Value of 3-dimensional Computerized Tomography (3D-CT) Scan Indicators of Mandible Bone in Sex Determination of Selected Individuals in Tehran

Zahra Ismaili Shahroudi Moqaddam¹, Mahsa Jamshidi², Foroozan Fares¹, Abbas Aghabiklooei¹, Mohsen Saberi Isfeedvajani^{3*}

Received: 24 Mar 2022

Published: 21 Dec 2022

Abstract

Background: Sex determination is one of the most important criteria in cadaver identification so if it determines accurately, half of the population can be statistically excluded. The aim of this study was to determine the sex according to diagnostic factors in a 3D CT scan of the mandible.

Methods: In this cross-sectional study, we selected 197 3D CT scans files of mandible available at PACS of hospitals affiliated with the Iran University of Medical Sciences (IUMS). In this study, we measured mandibular or gonial angle (G angle), ramus length, minimum ramus breadth, maximum ramus breadth, coronoid height, mandibular length, bigonial breadth, bicondylar breadth, symphyseal height, symphyseal height to mandibular length ratio, symphyseal height to ramus length ratio, symphyseal height to bicondylar breadth ratio, symphyseal height to bigonial breadth ratio, ramus length to bigonial breadth ratio, ramus length to bicondylar breadth ratio, bigonial breadth to bicondylar breadth ratio and ramus length to mandibular length ratio. The ROC curve was used to evaluate the diagnostic value of each indicator.

Results: There was a significant difference between males and females in all indicators except symphyseal height to mandibular length ratio, symphyseal height to bicondylar breadth ratio, symphyseal height to bigonial breadth ratio and bigonial breadth to bicondylar breadth ratio. The highest AUC, sensitivity, specificity and diagnostic accuracy were related to ramus length, symphyseal height to ramus length ratio, bicondylar breadth and ramus length respectively.

Conclusion: Mandible bone 3D CT scan indicators could be used alone to determine sex in the Iranian population.

Keywords: Sex Determination by Skeleton, Mandible, Sensitivity and Specificity, Imaging, Three-Dimensional, Forensic Medicine

Conflicts of Interest: None declared

Funding: This study was supported by the Faculty of Medicine of Iran University Med Science.

*This work has been published under CC BY-NC-SA 1.0 license.

Copyright© Iran University of Medical Sciences

Cite this article as: Ismaili Shahroudi Moqaddam Z, Jamshidi M, Fares F, Aghabiklooei A, Saberi Isfeedvajani M. The Diagnostic Value of 3-dimensional Computerized Tomography (3D-CT) Scan Indicators of Mandible Bone in Sex Determination of Selected Individuals in Tehran. *Med J Islam Repub Iran.* 2022 (21 Dec);36:160. <https://doi.org/10.47176/mjiri.36.160>

Introduction

Sex determination is one of the most important criteria in cadaver identification so if it determines accurately, half of the population can be statistically excluded. Although sex differences are not clear before puberty, specific pelvic measurements can determine a person's sex to some extent, even during pregnancy (1, 2).

The accuracy of sex determination can be difficult to estimate because there are several factors involved. Sex determination is based on the whole skeleton, pelvis, skull, skull and pelvis together, long bones, long bones, and pelvis together, and skull and mandible are mentioned with different accuracy from 80 to 100 percent. Generally, dif-

Corresponding author: Dr Mohsen Saberi Isfeedvajani, msaberi@bmsu.ac.ir

¹ Department of Forensic Medicine, Faculty of Medicine, Iran University of Medical Sciences, Tehran, Iran

² Oral and Maxillofacial Radiologist, Faculty of Dentistry, Isfahan University of Medical Sciences, Isfahan, Iran

³ Medicine, Quran and Hadith Research Center & Department of Community Medicine, Faculty of Medicine, Baqiyatallah University of Medical Sciences, Tehran, Iran

↑What is “already known” in this topic:

Several studies in different countries have used mandibular radiography and CT scan indicators of living people and cadavers to determine sex.

→What this article adds:

We provide important information for forensic medicine specialists to predict sex in the Iranian population by mandible bone 3D CT scan indicators.

ferent dimensions of bones in adult females are about 94% of the sizes obtained in males of the same race. Also, the mentioned items are practical and reliable for the ages of 20 to 55 years (1).

Knight's forensic pathology, as a reference book, introduced several indicators based on bone measurements, such as subpubic angle, ischiopubic index, base wing index, and trochanteric oblique length. All of these indicators are based on dry or fresh bone measurements (1).

Recent studies have been used to determine sex based on available indicators that can be calculated on radiographic images and CT scans in addition to bone measurements. Numerous indicators have been evaluated in radiographic images and CT scans of living people and corpses, including foramen magnum (3, 4), scapula (5-7), lumbar vertebrae (8), hyoid bone (9), whole skeleton (10), femur (11), skull (12-18), maxillary sinus (19), sternum (20, 21), pelvis (22) temporal bone (2) and orbital (23). Several studies in different countries such as South Korea (24), China (25, 26), Brazil (27, 28), India (17, 29), Japan (30), Malaysia (31, 32), Turkey (4, 33), Egypt (34) and France (35) have been used mandibular radiography and CT scan indicators of living people and cadaver to determine sex. Several indicators are studied in these studies, such as gonial or mandibular angle, mandibular length, ramus length of mandible, minimum ramus breadth, maximum ramus breadth, bigonial breadth, bicondylar breadth, symphyseal height and so on.

Based on the literature review, 3D CT scan indicators of mandible bone have not been already used in sex determination in recent studies conducted in Iran so far. Thus, it is necessary to study the mentioned indicators in the Iranian population in order to standardize and evaluate their diagnostic value. Also, in this study, we have tried to define several new indicators in the Iranian population using previous studies in order to achieve better diagnostic accuracy. Therefore, the aim of this study was to determine the sex of selected individuals in Tehran according to diagnostic factors in a 3D CT scan of the mandible.

Methods

This was a cross-sectional study. Sample size was calculated by Power Analysis & Sample Size (PASS) version 15. Based on an alpha error equal to 0.05, the beta error equal to 0.2, the null hypothesis equal to 80% (the area under the curve (AUC) equal to 80%) and the alternative hypothesis equal to 90% (AUC equal to 90%), the sample size had been estimated 162 (36). However, we selected non-randomly 197 3D CT scans files of mandible available at the Picture Archiving and Communication System (PACS) of hospitals affiliated to Iran University of Medical Sciences (IUMS) (Firoozgar Hospital and 7th Tir Martyrs Hospital) in 2021 to 2022. Inclusion criteria were age > 20 years and clarity of the gender status of the CT scan. Exclusion criteria were age <= 20 years and uncertainty of people's names and surnames. In this study, 17 indicators were evaluated. These indicators were mandibular or gonial angle (G angle), ramus length, minimum ramus breadth, maximum ramus breadth, coronoid height, mandibular length, bigonial breadth, bicondylar breadth,

symphyseal height, symphyseal height to mandibular length ratio, symphyseal height to ramus length ratio, symphyseal height to bicondylar breadth ratio, symphyseal height to bigonial breadth ratio, ramus length to bigonial breadth ratio, ramus length to bicondylar breadth ratio and ramus length to mandibular length ratio. Figures 1 to 3 show the measured parameters. Also, Table 1 shows the definition of the first 9 parameters. A checklist was prepared based on the mentioned indicators. These indicators were measured by an oral and maxillofacial radiologist using PACS software.

We used SPSS version 24 to analyze data. Frequency

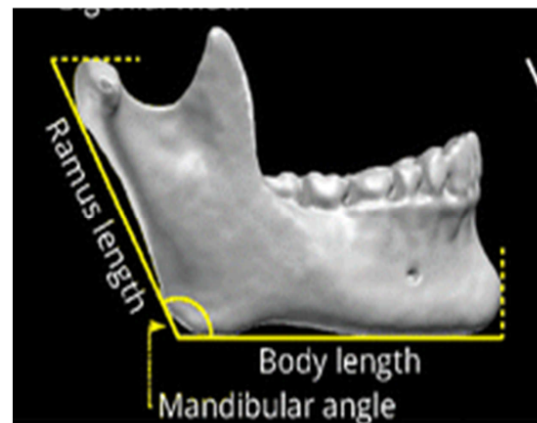


Fig. 1. Ramus length, Body length (Mandibular length), and Mandibular angle

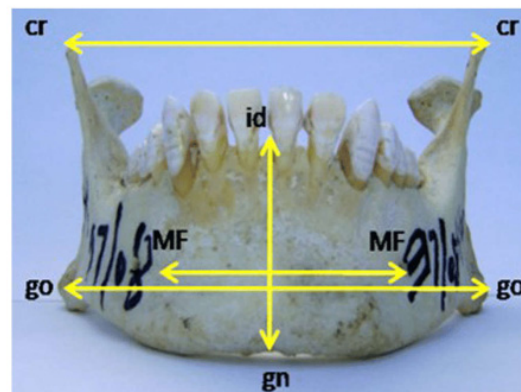


Fig. 2. Bigonial breadth, Bicondylar breadth, Symphyseal height

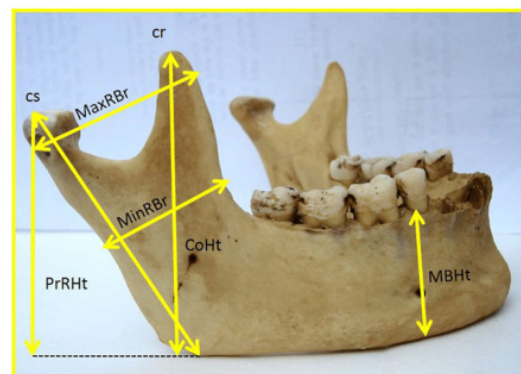


Fig. 3. Minimum ramus breadth, Maximum ramus breadth, Coronoid height

Table 1. Definition of 9 measured parameters

Parameter	Definition
Mandibular or gonial angle (G angle)	The angle formed by the posterior border of the ramus and the inferior border of the mandible body
Ramus length	The direct distance between condyilion and gonion
Minimum ramus breadth	The distance between the most posterior point on the anterior border of the ramus to the most anterior point on the posterior border of the ramus.
Maximum ramus breadth	The distance between the most anterior point on the mandibular ramus and a line connecting the most posterior point on the condyle.
Coronoid height	The distance between the coronion and the lower wall of the mandibular bone
Mandibular length	The direct distance between gonion and gnathion
Bigonial breadth	The direct distance between right and left gonion
Bicondylar breadth	The direct distance between the two condyilion
Symphyseal height	The distance between the infra-dental and gnathion

and percentage were reported for qualitative variables; and mean and standard deviation (SD) were reported for quantitative variables. Normal distribution was tested by Kolmogorov–Smirnov test. Independent t-test or its non-parametric equivalent Mann-Whitney U test, was used to compare quantitative variables between two groups. The ROC curve (receiver operating characteristic curve) was used to evaluate the diagnostic value of each indicator. Also, sensitivity and specificity based on the best cut-off were reported. The significance level was considered less than 0.05.

This article is the result of the first author's forensic medicine residency dissertation, which was approved by the Research Ethics Committee of the Faculty of Medicine of IUMS (Approval ID: IR.IUMS.FMD.REC.1399.182).

Results

A total of 197 3D mandibular bone CT scan files from the PACS were evaluated. One hundred files belonged to women, and the rest belonged to men (Table 2).

Table 3 presents the mandibular bone indicators by sex. There was a significant difference between males and fe-

Table 2. Sex status of 3D mandible bone CT scan file

Sex status	Frequency	Percentage
Male	97	49.2
Female	100	51.8
Total	197	100

Table 3. Mandibular bone indicators by sex

3	Sex	Mean	SD	P value
G angle °	Male	120.14	5.97	0.010
	Female	122.06	5.33	
Ramus length (mm)	Male	60.81	4.59	<0.001
	Female	54.69	4.14	
Minimum ramus breadth (mm)	Male	31.20	3.09	0.001
	Female	29.81	2.48	
Coronoid height (mm)	Male	66.89	4.35	<0.001
	Female	60.82	4.30	
Mandibular length (mm)	Male	75.41	4.29	<0.001
	Female	71.61	4.59	
Bicondylar breadth (mm)	Male	121.93	5.24	<0.001
	Female	115.35	5.13	
Bigonial breadth (mm)	Male	96.56	6.18	<0.001
	Female	89.76	4.73	
Maximum ramus breadth (mm)	Male	37.41	3.76	<0.001
	Female	35.03	2.89	
Symphyseal height (mm)	Male	31.53	4.05	0.001
	Female	30.35	2.43	
Symphyseal height to mandibular length ratio	Male	.42	.06	0.474
	Female	.43	.04	
Symphyseal height to ramus length ratio	Male	.52	.08	<0.001
	Female	.56	.05	
Symphyseal height to bicondylar breadth ratio	Male	.26	.04	0.282
	Female	.26	.02	
Symphyseal height to bigonial breadth ratio	Male	.33	.05	0.117
	Female	.34	.03	
Ramus length to bigonial breadth ratio	Male	.63	.06	0.008
	Female	.61	.05	
Ramus length to bicondylar breadth ratio	Male	.50	.04	<0.001
	Female	.47	.04	
Bigonial breadth to bicondylar breadth ratio	Male	.79	.06	0.062
	Female	.78	.04	
Ramus length to mandibular length ratio	Male	.81	.08	<0.001
	Female	.77	.07	

Table 4. The AUC and the best cut-off for each mandibular bone indicator

Indicator	AUC (95% CI)	Best cut-off	P value
G angle °	0.606 (0.526-0.685)	118.35	0.010
Ramus length (mm)	0.847 (0.791-0.903)	57.025	<0.001
Minimum ramus breadth (mm)	0.641 (0.563-0.719)	31.68	0.001
Coronoid height (mm)	0.846 (0.790-0.901)	63.585	<0.001
Mandibular length (mm)	0.734 (0.664-0.804)	72.755	<0.001
Bicondylar breadth (mm)	0.826 (0.767-0.886)	120.15	<0.001
Bigonial breadth (mm)	0.812 (0.753-0.872)	93.615	<0.001
Maximum ramus breadth (mm)	0.708 (0.635-0.781)	37.235	<0.001
Symphyseal height (mm)	0.631 (0.552-0.711)	31.225	0.001
Symphyseal height to mandibular length ratio	0.53 (0.448-0.611)	-----	0.474
Symphyseal height to ramus length ratio	0.638 (0.560-0.715)	0.4859	0.001
Symphyseal height to bicondylar breadth ratio	0.524 (0.442-0.606)	-----	0.562
Symphyseal height to bigonial breadth ratio	0.565 (0.483-0.646)	-----	0.117
Ramus length to bigonial breadth ratio	0.618 (0.539-0.697)	0.6124	0.004
Ramus length to bicondylar breadth ratio	0.678 (0.603-0.754)	0.4829	<0.001
Bigonial breadth to bicondylar breadth ratio	0.555 (0.474-0.637)	-----	0.18
Ramus length to mandibular length ratio	0.679 (0.604-0.754)	0.7808	<0.001

Table 5. The sensitivity, specificity, PLR, NLR, PPV, NPV, and diagnostic accuracy (DA) for each mandibular bone indicator

Indicator	Sensitivity (95% CI)	Specificity (95% CI)	PLR (95% CI)	NLR (95% CI)	PPV (95% CI)	NPV (95% CI)	DA (95% CI)
G angle °	78.00% (68.61- 85.67)	44.33% (34.24- 54.77)	1.40 (1.14- 1.72)	0.50 (0.32- 0.76)	59.13% (54.08- 63.99)	66.12% (55.91- 75.02)	61.43% (54.25- 68.27)
Ramus length (mm)	88.66% (80.61- 94.20)	73.00 (63.20- 81.39)	3.28 (2.36- 4.57)	0.16 (0.09- 0.27)	76.08% (69.57- 81.56)	86.92% (79.00%- 92.15)	80.70% (74.49- 85.97)
Minimum ramus breadth (mm)	50.52 (40.17- 60.83)	81.00 (71.93- 88.16)	2.66 (1.70- 4.17)	0.61 (0.49- 0.76)	72.03% (62.15- 80.15)	62.83% (57.50- 67.86)	66.00% (58.93- 72.58)
Coronoid height (mm)	85.57% (76.97- 91.88)	72.00% (62.13- 80.52)	3.06 (2.21- 4.23)	0.20 (0.12- 0.33)	74.75% (68.14- 80.37)	83.74% (75.76- 89.46)	78.67% (72.29- 84.18)
Mandibular length (mm)	76.29% (66.58- 84.34)	61.62 (51.30- 71.22)	1.99 (1.51- 2.61)	0.38 (0.26- 0.57)	65.81% (59.43- 71.67)	72.85% (64.51- 79.84)	68.84% (61.85- 75.24)
Bicondylar breadth (mm)	71.13% (61.05- 79.89)	84.85% (76.24- 91.26)	4.69 (2.90- 7.61)	0.34 (0.25- 0.47)	81.97% (73.72- 88.05)	75.22% (68.72- 80.74)	78.10% (71.65- 83.68)
Bigonial breadth (mm)	71.13% (61.05- 79.89)	80.81% (71.66- 88.03)	3.71 (2.43- 5.66)	0.36 (0.26- 0.50)	78.21% (70.15- 84.58)	74.30% (67.58- 80.03)	76.05% (69.45- 81.84)
Maximum ramus breadth (mm)	57.29% (46.78- 67.34)	81.00% (71.93- 88.16)	3.02 (1.94- 4.68)	0.53 (0.41- 0.68)	74.49% (65.29- 81.93)	66.20% (60.39- 71.55)	69.34% (62.37- 75.71)
Symphyseal height (mm)	58.76% (48.31- 68.67)	70.00% (60.02- 78.76)	1.96 (1.39- 2.76)	0.59 (0.45- 0.77)	65.48% (57.39- 72.77)	63.67% (57.23- 69.66)	64.47% (57.36- 71.14)
Symphyseal height to ramus length ratio	94.00% (87.40- 97.77)	34.02% (24.70- 44.34)	1.42 (1.22- 1.66)	0.18 (0.08- 0.40)	57.98% (54.26- 61.61)	85.41% (71.98- 93.03)	63.53% (56.39- 70.26)
Ramus length to bigonial breadth ratio	64.95% (54.59- 74.36)	58.59% (48.24- 68.40)	1.57 (1.19- 2.07)	0.60 (0.44- 0.82)	60.30% (53.54- 66.69)	63.31% (55.68- 70.33)	61.72% (54.52- 68.55)
Ramus length to bicondylar breadth ratio	70.10% (59.96- 78.98)	63.64% (53.36- 73.07)	1.93 (1.44- 2.58)	0.47 (0.33- 0.66)	65.12% (58.25- 71.41)	68.73% (61.02- 75.52)	66.82% (59.75- 73.36)
Ramus length to mandibular length ratio	64.95% (54.59- 74.36)	66.67% (56.48- 75.82)	1.95 (1.42- 2.67)	0.53 (0.39- 0.71)	65.36% (57.94- 72.10)	66.26% (59.15- 72.70)	65.82% (58.72- 72.43)

males in all indicators except 4 indicators. These 4 indicators were ratios. In all indicators, except G angle, symphyseal height to mandibular length ratio, symphyseal height to ramus length ratio, symphyseal height to bicondylar breadth ratio and symphyseal height to bigonial breadth ratio, the measured values were higher in men.

To evaluate the diagnostic value of each indicator, we used the ROC curve and calculated the area under the curve (AUC), sensitivity, specificity and best cut-off. Table 4 presents the area under the curve (AUC) and the best cut-off for each indicator. Also, Table 5 presents sensitivity, specificity, positive likelihood ratio (PLR), negative likelihood ratio (NLR), positive predictive value (PPV), negative predictive value (NPV) and diagnostic accuracy (DA) with a 95% confidence interval for each indicator.

The highest AUC, sensitivity, specificity, diagnostic accuracy, PLR, NLR, PPV, and NPV were related to ramus length, symphyseal height to ramus length ratio, bicondylar breadth, ramus length, bicondylar breadth, ramus

length, bicondylar breadth and ramus length respectively. Due to the insignificance of AUC, best cut-off, sensitivity, specificity, PLR, NLR, PPV, NPV and DA were not calculated for symphyseal height to mandibular length ratio, symphyseal height to bicondylar breadth ratio, symphyseal height to bigonial breadth ratio and bigonial breadth to bicondylar breadth ratio. Thus, these indicators did not have a good diagnostic value. In all indicators except G angle and symphyseal height to ramus length ratio, the higher the indicator value from the cut-off point, the more likely it is to be a male.

Discussion

Sex determination plays an important role in the identification of cadavers. The mandible bone indicators have been appropriately used to predict sex in various populations by using different methods. (4, 17, 24-35, 37)

The present study showed that mandibular indicators were significantly dimorphic between males and females.

All indicators except 4 indicators showed sex dimorphism. These indicators were symphyseal height to mandibular length ratio, symphyseal height to bicondylar breadth ratio, symphyseal height to bigonial breadth ratio and bigonial breadth to bicondylar breadth ratio. Also, except for these indicators and the G angle, all other indicators were higher in males. The highest AUC, sensitivity and specificity were related to ramus length, symphyseal height to ramus length ratio and bicondylar breadth respectively.

Mandibular angle could be used to predict sex in this study. This finding is consistent with other studies' findings in the Chinese population (25), Japanese population (30), Turkish population (33), and Egyptian population (34). However, our finding is inconsistent with İlgüy (4) and Gamba studies (28). İlgüy and his colleagues' study reported that there is no significant difference between males' and females' G angles. (4) Gamba and his colleagues' study showed that male G angle is significantly higher than female G angle. (28) These inconsistencies could be interpreted by racial differences.

Ramus length could be a perfect indicator to predict sex in this study due to the highest AUC and diagnostic accuracy. Fortunately, our finding is consistent with other studies performed in different populations. (4, 24, 25, 28, 31, 33)

Minimum ramus breadth could be used to predict sex in this study. This finding is consistent with studies performed by İlgüy (4), Alias (31), and Inci (33). However, our finding is inconsistent with the Gamba's study (28). Gamba and his colleagues' study reported that minimum ramus breadth did not significantly differ between males and females. This inconsistency may be interpreted by racial differences.

Coronoid height, as the second rank in AUC and diagnostic value, could be a perfect indicator to predict sex in this study. Our finding is consistent with the Alias's study. (31) In addition, Mandibular length could be used to predict sex in this study. Our finding is consistent with studies performed by İlgüy (4) and Hwang (24).

Bicondylar breadth as the third rank in AUC and diagnostic value with the highest specificity, could be another perfect indicator to predict sex in this study. Fortunately, our finding is consistent with other studies performed in different populations. (4, 24-26, 28, 30, 31, 34). Also, bigonial breadth as the fourth rank in AUC and diagnostic value could be another perfect indicator to predict sex in this study. Fortunately, our finding is consistent with other studies performed in different populations. (4, 24-26, 28, 30, 31, 34)

Maximum ramus breadth could be used to predict sex in this study. Our finding is consistent with studies performed by Dong (25), Alias (31), and Inci (33). Also, Symphyseal height can play a role in sex determination. This finding is consistent with studies performed by Hwang (24) and Alias (31).

Symphyseal height to mandibular length ratio is not a good indicator to predict sex. This finding is consistent with Hwang's study (24). However, the symphyseal height to ramus length ratio with the highest sensitivity could be used to predict sex in our study. This finding is incon-

sistent with Hwang's study maybe due to racial differences. Hwang and his colleagues' study reported that this indicator did not significantly differ between males and females. (24).

Symphyseal height to bicondylar breadth ratio and symphyseal height to bigonial breadth ratio are not good indicators for sex prediction. These findings are consistent with Hwang's study (24).

Ramus length to bigonial breadth ratio could be used to predict sex in this study. This finding is inconsistent with Hwang's study, maybe due to racial differences. Hwang and his colleagues' study reported that this indicator did not significantly differ between males and females. (24) Also, the ramus length to bicondylar breadth ratio could be used to predict sex in this study. This finding is consistent with Hwang's study (24).

Bigonial breadth to bicondylar breadth ratio is not a good indicator to predict sex. Although this finding is consistent with Deng's study (26); however, it is inconsistent with Hwang's study (24). Hwang and his colleagues' study reported that this indicator is significantly higher in males. This inconsistency may be interpreted by racial differences.

Finally, the ramus length to mandibular length ratio could be used to predict sex in this study. This finding is consistent with Hwang's study (24).

In our study, ramus length with the best diagnostic accuracy (80.85%) was the best and most important indicator. This finding is consistent with Hwang's study. In the Hwang's study, the best diagnostic accuracy belonged to ramus length (82.9%) (24).

Conclusion

Mandible bone 3D CT scan indicators could be used alone to determine sex. Moreover, our findings provide important information for forensic medicine specialists to predict sex in the Iranian population and could be considered a primary guideline for sex determination in this population.

Acknowledgments

This research is the result of a dissertation in forensic medicine that has been approved by the medical school of Iran University of Medical Sciences. The authors would like to thank all officials and people for all their support and guidance while carrying out this study especially the Shahid Shokri Dental Hospital president and Radiology Ward.

Ethical Approval

This research was approved by the Research Ethics Committee of the Faculty of Medicine of IUMS (Approval ID: IR.IUMS.FMD.REC.1399.182).

Conflict of Interests

The authors declare that they have no competing interests.

References

1. Saukko P, Knight B. Knight's forensic pathology fourth edition ed: CRC press; 2016.
2. Sharifian H, Qorbanisani M, Tefagh G, Mohammadi-Vajari E, Mohammadi-Vajari MA, Mohammadzadeh M. Assessment of Gender Differences in Temporal Bone Anatomy Using Computerized Tomography Scan Images in Iranian People. *Feyz*. 2019;23(1):83-8.
3. Mehta M, Saini V, Patel M, Menon S. Applicability and reliability of foramen magnum for sex determination in contemporary Western Indian population: A computed tomographic study. *J Forensic Radiol. Imaging* 2019;17:31-5.
4. İlgüy D, İlgüy M, Ersan N, Dölekoğlu S, Fişekçiöğlü E. Measurements of the foramen magnum and mandible in relation to sex using CBCT. *J Forensic Sci*. 2014;59(3):601-5.
5. Zhang K, Cui JH, Luo YZ, Fan F, Yang M, Li XH, et al. Estimation of stature and sex from scapular measurements by three-dimensional volume-rendering technique using in Chinese. *Leg Med*. 2016;21:58-63.
6. Wilson E. Estimation of sex from scapulae measurements in a Western Australian population: Murdoch University; 2019.
7. Omar N, Ali SHM, Shafie MS, Ismail NAN, Hadi H, Nor FM. A preliminary study of sexual dimorphism of scapula by computed tomography in the Malaysian population. *Asian J Pharm Clin Res*. 2019:391-5.
8. Decker SJ, Foley R, Hazelton JM, Ford JM. 3D analysis of computed tomography (CT)-derived lumbar spine models for the estimation of sex. *Int J Legal Med*. 2019:1-10.
9. Okasi A, Sadeghian MH, Behnoush B, Rad AS. Sex Identification by Morphometric Study of Hyoid Bone. *Int J Med Toxicol Forensic Med*. 2019;8(4 (Autumn)):145-50.
10. Franchi A, Valette S, Agier R, Prost R, Kéchichan R, Fanton L. The prospects for application of computational anatomy in forensic anthropology for sex determination. *Forensic Sci Int*. 2019;297:156-60.
11. Fliss B, Luethi M, Fuernstahl P, Christensen AM, Sibold K, Thali M, et al. CT-based sex estimation on human femora using statistical shape modeling. *Am J Phys Anthropol*. 2019;169(2):279-86.
12. Bewes J, Low A, Morphet A, Pate FD, Henneberg M. Artificial intelligence for sex determination of skeletal remains: Application of a deep learning artificial neural network to human skulls. *J Forensic Leg Med*. 2019;62:40-3.
13. Yang W, Liu X, Wang K, Hu J, Geng G, Feng J. Sex Determination of Three-Dimensional Skull Based on Improved Backpropagation Neural Network. *Comput Math Methods Med*. 2019;2019:9163547.
14. Luo L, Wang M, Tian Y, Duan F, Wu Z, Zhou M, et al. Automatic sex determination of skulls based on a statistical shape model. *Comput Math Methods Med*. 2013;2013:251628.
15. Yang W, Liu XN, Zhu F, Liu XL, Zhu LP. Sex Recognition of Skulls in Chinese Uygur. *Fa Yi Xue Za Zhi*. 2019;35(2):200-4.
16. Rooppakhun S, Piyasin S, Vatanapatimukul N, Kaewprom Y, Sitthiseriratip K. Craniometric study of Thai skull based on three-dimensional computed tomography (CT) data. *J Med Assoc Thai*. 2011;93(1):90.
17. Mehta M, Saini V, Nath S, Menon SK. CT scan images for sex discrimination—a preliminary study on Gujarati population. *J Forensic Radiol. Imaging* 2015;3(1):43-8.
18. Kimmerle EH, Ross A, Slice D. Sexual dimorphism in America: geometric morphometric analysis of the craniofacial region *J Forensic Sci*. 2008;53(1):54-7.
19. Abasi P, Ghodousi A, Ghafari R, Abbasi S. Comparison of accuracy of the maxillary sinus area and dimensions for sex estimation lateral cephalograms of Iranian samples. *J Forensic Radiol Imaging*. 2019;17:18-22.
20. Bedalov A, Basic Z, Marelja I, Dolic K, Bukarica K, Missoni S, et al. Sex estimation of the sternum by automatic image processing of multi-slice computed tomography images in a Croatian population sample: a retrospective study. *Croat Med J*. 2019;60(3):237-45.
21. Ekizoglu O, Hocaoglu E, Inci E, Bilgili MG, Solmaz D, Erdil I, et al. Sex estimation from sternal measurements using multidetector computed tomography. *Medicine*. 2014;93(27):e240.
22. Memarian A, Aghakhani K, Mehrpisheh S, Fares F. Gender determination from diagnostic factors on anteroposterior pelvic radiographs. *J Chin Med Assoc*. 2017;80(3):161-8.
23. Kaya A, Uygun S, Eraslan C, Akar GC, Kocak A, Aktas E, et al. Sex estimation: 3D CTA-scan based on orbital measurements in Turkish population. *Rom J Leg Med*. 2014;22(4):257-62.
24. Hwang E, Lin C, Jiao B, Chung N-E, Han SH, Kim J, et al. Discriminant function analysis for sex determination using landmark coordinate data from three-dimensional mandible models. *Aust J Forensic Sci*. 2015;47(3):332-44.
25. Dong H, Deng M, Wang W, Zhang J, Mu J, Zhu G. Sexual dimorphism of the mandible in a contemporary Chinese Han population. *Forensic Sci Int*. 2015;255:9-15.
26. Deng M, Bai R, Dong H, Mu J, Lin W, Zhou Y. Sexual determination of the mandible breadth in a central Chinese population sample: a three-dimensional analysis. *Aust. J Forensic Sci*. 2017;49(3):332-43.
27. de Oliveira Gamba T, Alves MC, Haiter-Neto F. Analysis of sexual dimorphism by locating the mandibular canal in images of cone-beam computed tomography. *J Forensic Radiol Imaging* 2014;2(2):72-6.
28. de Oliveira Gamba T, Alves MC, Haiter-Neto F. Mandibular sexual dimorphism analysis in CBCT scans. *J Forensic Leg Med*. 2016;38:106-10.
29. Uppal MK, Asha I, Seema P, Ramya M, Subash B, Kumar J. Radiomorphometric localization of mental foramen and mandibular canal using cone beam computed tomography as an aid to gender determination-A retrospective study. *Tricity J Health Res*. 2017;1(2):216.
30. Kano T, Oritani S, Michiue T, Ishikawa T, Hishmat AM, Sogawa N, et al. Postmortem CT morphometry with a proposal of novel parameters for sex discrimination of the mandible using Japanese adult data. *Leg Med*. 2015;17(3):167-71.
31. Alias A, Ibrahim A, Abu Bakar SN, Swarhib Shafie M, Das S, Abdullah N, et al. Anthropometric analysis of mandible: an important step for sex determination. *Clin Ter*. 2018;169(5):e217-e23.
32. Alias A, Ibrahim A, Bakar S, Rokhani F, Swarhib M, Nor FM. Morphometric analysis of coronoid process of mandible by CT in the Malaysian population: An important step for determination of sex. *J Dent Sci Res. Ther*. 2018;5:1-8.
33. Inci E, Ekizoglu O, Turkay R, Aksoy S, Can IO, Solmaz D, et al. Virtual assessment of sex: linear and angular traits of the mandibular ramus using three-dimensional computed tomography. *J Craniofac Surg*. 2016;27(7):e627-e32.
34. Abd Elsalam gs, El-Shal O, Shaaban A. Evaluation of Different Mandibular Measurements by Cone Beam Computed Tomography as A Forensic Age & Gender Determination Tools. *Al-Azhar Dent J Girls* 2019;6(4):445-52.
35. Tardivo D, Sastre J, Ruquet M, Thollon L, Adalian P, Leonetti G, et al. Three-dimensional modeling of the various volumes of canines to determine age and sex: a preliminary study. *J Forensic Sci*. 2011;56(3):766-70.
36. [updated at 2022/09/05]. Available from: <https://www.ncss.com/software/pass/procedures/>.
37. Babae A, Kalantari F, Mirza-Ali E, Shabanizadeh A, Dehghani-Soltani S, Taghavi MM. The Relationship between Mandibular Dimensions and Stature in a Kerman Population in 2020. *Jiroft Univ Med Sci*. 2021;8(3):699-708.