

Vagus nerve schwannoma presented with long-term cachexia: report of a case and review of literature

Ali Ghafouri¹, MD., Zhamak Khorgami², MD., Saadat Molanaei³, MD.

School of Medicine Tehran University of Medical Sciences .Tehran, Iran.

Abstract

Intraabdominal schwannomas are rare tumors that may arise from viscera or abdominal wall. The rarity accompanied by occurrence in odds places may make their diagnosis difficult and delayed. We present a case of distal paraesophageal schwannoma with long-term cachexia. A 34-year-old man presented with long-lasting vomiting, dysphagia, and progressive cachexia for four years. Multiple paraclinical assessments were normal; subsequently he was referred to psychiatric department and treated for anorexia nervosa for three year without any improvement. Further evaluations showed a mass in diaphragm hiatus in paraesophageal region. Explorative laparotomy revealed a cylindrical shaped encapsulated tumor parallel to distal esophagus arisen from vagus nerve, which was resected completely. Pathological and immunohistochemical examinations of the tumor revealed a benign plexiform schwannoma. After surgery, the patient was relieved from symptoms and gained weight significantly. It is important to consider physical causes in patients with cachexia who are treated for psychiatric problems and it is necessary to reevaluate these patients specially when there is no response to psychiatric treatments.

Keywords

schwannoma, vagus nerve, abdominal esophagus, cachexia

Introduction

Intraabdominal schwannomas are rare tumors that may arise from viscera or abdominal wall. The rarity accompanied by its generation in odds places may make their diagnosis hard and prolonged. There are some reports of vagus nerve schwannoma but mostly in cervical and thoracic part. We present a case of distal paraesophageal schwannoma presented with dysphagia and long-term cachexia who was treated after four years with abdominal surgical approach.

Case presentation

A 34-year-old man was referred to our surgery clinic in Milad Hospital because of nausea, vomiting, dysphagia, and progressive cachexia lasted for four years. Dysphagia was progressive mostly to solid foods and patient adopted to swallow food slowly. Bilious vomiting however would occur shortly after eating about five times a day. He lost 35 kg weight during this period and had no history of aspiration or regurgitation. He had been undergone multiple endoscopic examinations with no obvious abnormality. Contrast studies of esophagus, stomach, and proximal small bowel also revealed no ob-

1. **Corresponding author**, Professor of General and Thoracic Surgery, Dr Shariati Hospital, School of Medicine Tehran University of Medical Sciences.Tehran. Iran. Address: Dr Shariati Teaching Hospital, Kargar Shomali, Tehran, Islamic Republic of Iran. Tel: +9821 84902450, Email: aghafouri@sina.tums.ac.ir

2. Assistant Professor of General Surgery Dr Shariati Hospital, School of Medicine Tehran University of Medical Sciences .Tehran .Islamic Republic of Iran.

3. Pathologist, Department of pathology, Milad Hospital, Tehran, Islamic Republic of Iran

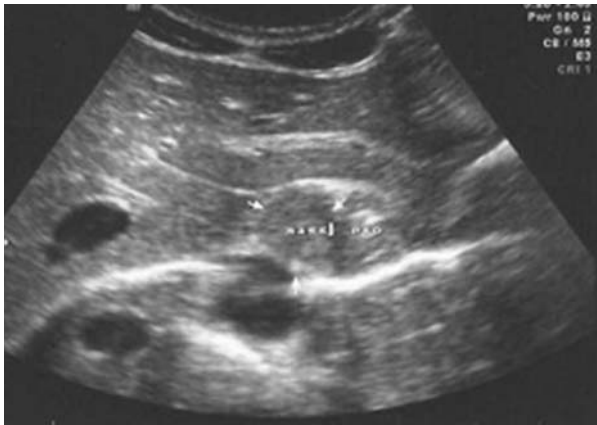

Fig 1. Sonographic finding showing a hypoechoic mass adjacent to abdominal esophagus.

structive lesion. After repeated assessment of gastrointestinal tract, he was then referred to psychiatric department for more evaluations. The patient was inaccurately diagnosed for anorexia nervosa and treated with multiple psychiatric drugs for three years with no improvement in site. The patient lost his work because of generalized weakness.

The most important findings in physical exam were severe cachexia, muscle waste, and weakness. There was no cutaneous lesions. He was admitted in surgery ward for further investigations. Sonographic evaluation and computed tomography imaging revealed a mass in di-

aphragm hiatus in right paroesophageal region (Figs. 1&2). Eventually an explorative laparotomy was planned. Due to severe malnutrition and in accordance with anesthesiology consultation, total parenteral nutrition was started for him. Thereafter an exploration laparotomy was done that revealed a cylindrical shaped encapsulated tumor parallel to distal esophagus with approximately 7cm in length and 2 cm in diameter (Fig. 3). The mass located adjacent to right diaphragmatic crus along the right vagus nerve. The mass was resected completely with right vagus nerve. Pathologic study showed a neoplasm with plexiform appearance entrapped within nerve bundles. The tumor structurally composed of spindle cells with bland nuclei in palisading arrangement and had no mitotic index or necrosis (Fig. 4). Immunohistochemically, the tumor was diffuse and strongly positive for S-100 protein and negative for C-kit and smooth muscle actin (Fig. 5).

The patient's symptoms recovered after surgery; there was no sign of delayed gastric emptying. Three months after surgery, patient gained 16 kg weight with feeling of wellbeing and returned to his normal social activities. One year after surgery the patient had normal status with 25 kg weight gain.

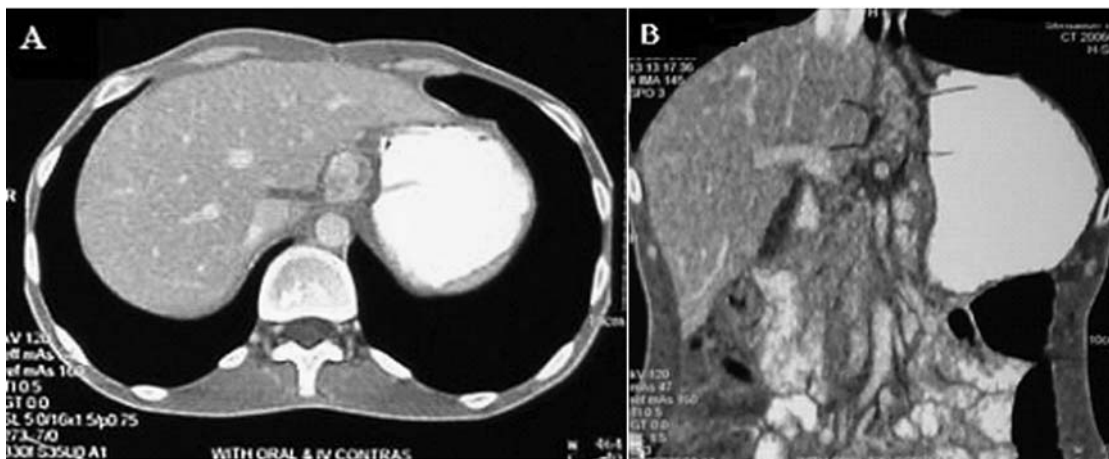


Fig. 2. Enhanced computed tomographic (A) axial scan and (B) coronal scan reveal a mass parallel to esophagus.

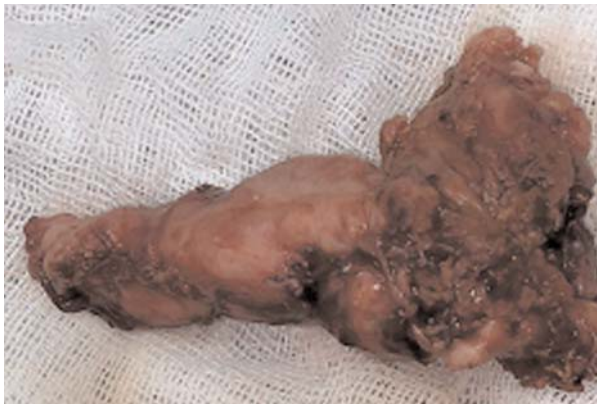

Fig. 3. Grossly, the mass was in cylindrical shape (7×2×2 cm) in position of right vagus nerve.

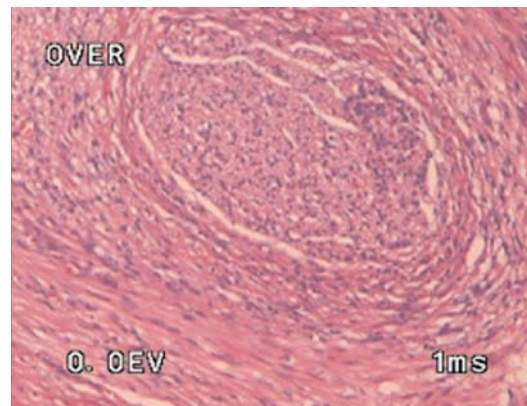


Fig. 4. Pathologic appearance of tumor by hematoxylin-eosin staining.

Discussion

Intraabdominal schwannomas occur most frequently in the alimentary tract with extremely rare occurrence in gastrointestinal tract [1]. Gastrointestinal involvement occurs in about 10% to 25% of patients with neurofibromatosis-1 and includes solitary or multiple neurofibromas, leiomyomas, and rarely, plexiform neurofibromas [2]. Furthermore, the schwannoma originating from the vagus nerve is much rare and only few reports are cited in the literature [2-4]. To our best knowledge, there is no report of vagus nerve schwannoma in abdominal paraesophageal region in the literature. Yoo et al [2] reported a vagus nerve schwannoma in similar region of vagus nerve but the tumor was in retroperitoneal space presenting as abdominal mass and it had been arisen from high body of stomach. Most other reports [3-4] are about schwannoma in cervical and thoracic regions of

vagus nerve. In these reports, the patients had presentations like neck mass, abnormal chest x-ray, dysphagia, and respiratory symptoms. In our patient, dysphagia was the main symptom which was not approached correctly. In the previous management, nutritional disturbance and cachexia was interpreted as psychiatric disorder and the patient was treated incorrectly for several years. Nonetheless, dysphagia, a rare symptom in benign lesions of esophagus is another unique aspect of this case.

The diagnosis of schwannoma depends on the pathological findings, especially on immunohistochemical test. Histologically schwannoma contains Schwann cells and nerve fibers that grow in a disorganized fashion and appear as interlacing bundles of elongated cells with intracellular collagen strands and palisading cell nuclei. Prior to immunohistochemical staining, there was high likelihood for misdiag-

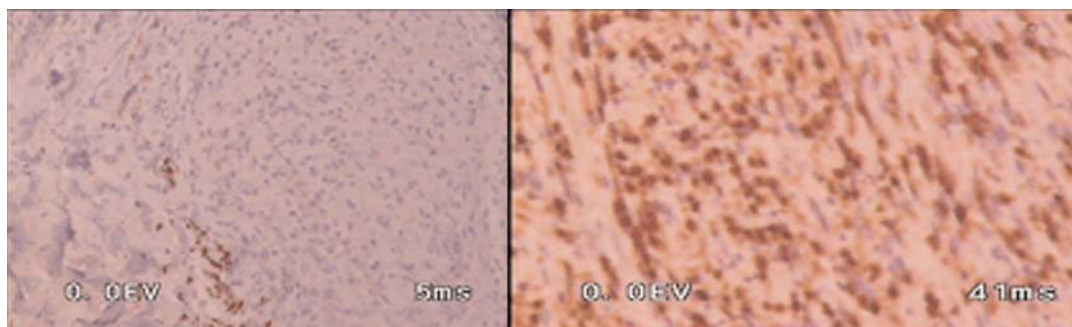


Fig. 5. Immunohistopathologic assessment showed cells positive for S100 (right) and negative for Smooth muscle actin (left).

nosing schwannoma as spindle cell tumor [5]. Schwannomas had positive bundled S-100 protein spindle cells in a fibrous, and negative S-100 protein background and negative for smooth muscle markers such as actin, desmin, CD117, and CD34 [6].

Surgery considered to be the main treatment for large lesions producing symptoms or any evidence of growing mass which can be done either via thoracotomy or endoscopically in small lesions. If the lesion is noted as high grade on biopsy or more than 10 cm in size, the appropriate therapy is en bloc esophagectomy with tumor-free resection margin [7]. The prognosis with benign schwannoma of the gastrointestinal tract is usually excellent. In our case with lower esophagus lesion intraabdominal approach was done with successful result which has not been reported yet.

Conclusion

Extraluminal mass parallel to esophagus can induce dysphagia without any obvious finding in endoscopic evaluations in early course of disease. It is important to consider physical causes in patients with cachexia who are treated for psychiatric problems, and is necessary to reevaluate these patients specially when there is no response to psychiatric treatments. Schwannomas can be arisen from vagus nerves in any parts of gastrointestinal tract. Distal paraesophageal schwannomas can be resected by laparotomy.

Competing interests

The authors declare that they have no competing interests.

Consent

Written informed consent was obtained from the patient for publication of this case report and accompanying images. A copy of the written consent is available for review by the Editor-in-Chief of this journal.

References

1. Hrehorovich PA, Franke HR, Maximin S, Caracta P. Malignant peripheral nerve sheath tumor. *Radiographics* 2003; 23(3):790-4.
2. Yoo BK, Yoo KS, Park CS, Lee JW, Yoo JY, Moon JH, Jung JO, Kim JP, Kim KO, Park CH, Hahn TH, Park SH, Kim JH, Min SK, Yang DH, Park CK. A case of retroperitoneal schwannoma of the vagus nerve. *Korean J Gastroenterol* 2005; 46(4): 302-5.
3. Takagi M, Akiba T. Schwannoma originating from a mediastinal vagal nerve resected by video-assisted thoracic surgery: a case report. *Nihon Kokyuki Gakkai Zasshi* 2007; 45(6): 499-502.
4. Yoon HU, Kim CB, Lee YH. An Obstructing Large Schwannoma in the Esophagus. *J Gastrointest Surg* 2008; 12:761-763.
5. Daimaru Y, Kido H, Hashimoto H, Enjoji M; Benign schwannoma of the gastrointestinal tract: a clinicopathologic and immunohistochemical study. *Hum Pathol* 1988; 19: 257-264.
6. Kobayashi N, Kikuchi S, Shimao H, Hiki Y, Kakita A, Mitomi H, Ohbu M; Benign esophageal schwannoma, report of a case. *Surg Today* 2000; 30:526-529.
7. Manger T, Pross M, Haeckel C, Lippert H; Malignant peripheral nerve sheath tumor of the esophagus. *Dig Surg* 2000; 17:627-631.