



Wooden Disposable Tongue Depressor: Can Facilitate Appropriate Reinforced Laryngeal Mask Insertion? A Randomized Controlled Trial

Jasim M Salman^{1*} , Jasim N Al-Asadi²

Received: 23 Apr 2022

Published: 17 Oct 2022

Abstract

Background: The reinforced laryngeal mask airway (RLMA) is difficult to insert due to the flexibility of its inner armored shaft. Many authors agreed that the available techniques have some disadvantages. They use materials that are reusable and require resterilization but may not guarantee infection control particularly during pandemics. The standard method can cause contamination and prone the operator to unanticipated trauma to their finger during placement. So this study aimed to evaluate the usefulness of disposable tongue depressors to aid insertion of the reinforced laryngeal mask airway.

Methods: A randomized controlled trial included one hundred ninety-four adult patients of either gender American Society of Anesthesiologists (ASA) I and II attended for elective day case surgery under general anesthesia. Patients were randomly categorized into two groups; each group consisted of ninety-seven. In the first group, insertion of the reinforced laryngeal mask airway was done using the standard technique of digital manipulation whereas the second one is the study group where disposable wooden tongue depressor guided insertion was used. The data were analyzed using SPSS version 23. Data were presented as frequencies or means and standard deviations. Chi-Square, Fisher Exact, and t-test were used. P value < 0.05 was considered significant.

Results: No significant difference in basic patients' demographic, anthropometric, and clinical characteristics were noticed between the two groups. The insertion time as well as the total time for RLMA placement, was significantly shorter in the new method group. Trauma was significantly less than 2.1% in the new method group compared to the standard group 10.3%, $p=0.003$.

Conclusion: The disposable wood tongue depressor insertion technique helps facilitate the correct placement of the reinforced laryngeal mask airway.

Keywords: Armored, Reinforced Laryngeal Mask Airway, Tongue Depressor, RLMA

Conflicts of Interest: None declared

Funding: None

*This work has been published under CC BY-NC-SA 1.0 license.

Copyright © Iran University of Medical Sciences

Cite this article as: Salman JM, Al-Asadi JN. Wooden Disposable Tongue Depressor: Can Facilitate Appropriate Reinforced Laryngeal Mask Insertion? A Randomized Controlled Trial. *Med J Islam Repub Iran.* 2022 (17 Oct);36:120. <https://doi.org/10.47176/mjiri.36.120>

Introduction

The reinforced laryngeal mask airway (RLMA) contains an inner armored metallic structure rendering it malleable and non-kinkabl (1). It is considered a good alternative to an endotracheal tube (2). However, its insertion is somewhat difficult because of the flexibility of the long shaft and requires some effort.

Because of the RLMA's broad range of applications (3-6), several approaches and tools have been proposed to enhance its insertion (7). Ninety-degree rotation was used by some authors (8). Video-laryngoscope-guided, stylet introducer, a small tracheal tube combined with a stylet, modified Magill forceps, and a modified tongue depressor was

Corresponding author: Dr Jasim M Salman, jasim.salman@uobasrah.edu.iq

¹ Department of Surgery, College of Medicine, University of Basrah, Basrah, Iraq

² Family & Community Medicine Department, College of Medicine, University of Basrah, Basrah, Iraq

↑What is “already known” in this topic:

The standard method for insertion of the reinforced laryngeal mask airway (RLMA) is digital manipulation. However, because of the flexibility of the lengthy shaft, its insertion is relatively difficult.

→What this article adds:

The new technique using a wooden disposable tongue depressor can facilitate correct placement of RLMA with encouraging results rendering its applicable use for easy insertion.

used by some authors with varying degrees of success (8-10). Other options described by some authors are the use of a spatula, Bosworth introducers and Flexiguide introducer to facilitate insertion (11). Kulkarni et al. designed an acrylic sheath (12) while Kim et al. (13) used light wand-guided insertion of the device. All the methods are useful for placement but they are either time-consuming or require preparation and adjustment (14). The standard method with digital manipulation prone the operator to unanticipated trauma to the finger during placement and is a source of infection. However, stylet and similar guides may rotate the device and impede insertion. Contamination and unwarranted disinfection are other disadvantages of non-disposable materials, as the moisture of these tools is unavoidable when inserted into the oral cavity. Furthermore, the options used by many authors need time and additional resources for enhancement.

In view of the aforementioned, this study was done in an attempt to examine a new method to insert RLMA utilizing a disposable wooden tongue depressor, which can be used in any age group and does not require finger use or other aids that need sterilization, and to identify if it can facilitate a proper RLMA placement within appropriate insertion time and minimum adverse effects.

Methods

This randomized controlled trial was done from December 2021 to April 2022 at the Basrah University Medical Centre, including 200 patients referred to the center for elective day case surgery during that period. This study was conducted in line with the Consolidated Standards of Reporting Trials (CONSORT) checklist (15).

The Scientific Committee of the College of Medicine, University of Basrah, approved the study [Project ID: 030409-050-2022]. Written informed consent was obtained

from all participants before enrolment in the study.

The sample size was determined to be 100 patients in each group using the following sample size formulae (16):

$$\text{Standardized Difference} = \frac{\text{Target Difference}}{\text{Standard Deviation}} \quad 1$$

Where the target difference is the difference between the mean of the total time for successful placement in the standard method and that of the new method. The standard deviation is that of the standard method.

$$n = \frac{2}{d^2} \times C_{p,power} \quad 2$$

Where n is the number of subjects required in each group, d is the standardized difference (equation 1), and $C_{p,power}$ is a constant defined by the values chosen for the P value and power.

For comparison between the two groups at a significance level of 0.05 with a test power of 90% based on means and standard deviations from the results of the pilot study on 50 patients (25 patients in each group) were the means \pm SD of the standard (digital) method and the new (wooden tongue depressor) method were 32.9 ± 8.3 and 29.1 ± 6.3 seconds respectively. The ultimate sample size was anticipated to be 200 (100 patients in each group).

The inclusion criteria were American Society of Anesthesiologists (ASA) I & II patients who were candidates for different day case surgeries under general anesthesia. Patients were excluded if their body mass index (BMI) was $>35 \text{ Kg/m}^2$, at increased risk of aspiration, preceding 10 days history of upper respiratory tract infection symptoms, mouth opening less than 2.5 cm, a restricted extension of the neck, abnormal prominent incisors and any receding mandible and oral surgeries, and gastro-oesophageal reflux disease. Six patients were excluded as they didn't meet the criteria thus a total number of 194 patients were analyzed (Fig. 1).

The patients were randomly allocated into two equal

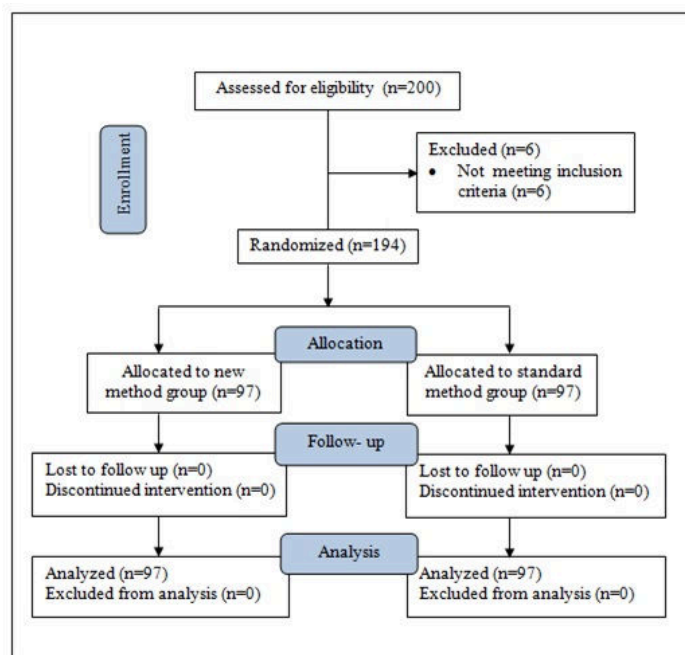


Fig. 1. The CONSORT diagram

groups with odd and even numbers. Each group consists of ninety-seven patients. Patients in the first group using the standard digital insertion method were odd-numbered, while those in the second group using disposable wooden tongue depressor guided insertion were even numbered.

All the participants underwent a thorough routine pre-anesthetic examination, including measurement of thyromental distance, mouth opening, and assessment of Mallampati scoring. The Mallampati classification has been used to identify people at risk of difficult laryngoscopy. The categorization assigns a score of 1-4 depending on the anatomic characteristics of the patient's airway visible when the patient opens his or her mouth and protrudes the tongue. Class I: Faucial pillars, Uvula, Soft palate, Hard palate visible, Class II: Uvula, Soft palate, Hard palate visible, Class III: Soft palate, Hard palate visible, and Class IV: Only hard palate visible (17).

Demographics and anthropometric data, including the age, gender, weight, height, and BMI of all the patients, were recorded. The pulse rate and mean arterial blood pressure were measured prior to anesthesia induction (baseline), 5 minutes, and 10 minutes after LMA insertion. A size 3 or 4 LMA depending on the weight of the patients, was used.

All patients had the same anesthetic protocol, which included intravenous induction with propofol 2-2.5 mg/kg body weight. After the patient had fallen asleep, 1 mg/kg of Suxamethonium chloride was administered to help the jaw muscles relaxation. Oxygen and isoflurane were used to maintain anesthesia. The patients were spontaneously ventilated thereafter throughout the operation.

Regarding the technique, in the standard group, the laryngeal mask was introduced with the cuff fully deflated and

directed by the index finger until resistance was encountered. Then the cuff is inflated to the recommended volume and upward movement of the device on cuff inflation suggests successful insertion.

In the study group, the reinforced device was placed in the mouth and picked by the left-hand front to front with its cuff fully inflated, then pushed by a wooden tongue depressor by navigation along with RLMA until passed the pharynx when resistance was encountered and upward movement of the larynx observe (Fig. 2). At this step, insertion was considered successful. Slipping of the guide or failure of insertion within 60 seconds was considered a failure and the device is removed and retrieval done and considered as an attempt until three trials.

After insertion, the device was connected to the breathing system to assess appropriate placement. Three manual ventilations were started for clinical assessment. Absent leak, observing the movement of the chest wall, bilateral air entry, $SPO_2 \geq 95\%$, normal wave $etCO_2$, and absent signs of obstruction reflect successful placement. Device alignment or changing head position was done to achieve positive clinical signs as required.

Proper anatomical position is determined by the optimum fiberoptic view using a Reister fiberoptic bronchoscope. Views were scored from 1 to 4. Score 1 vocal cords not seen; score 2 vocal cords plus anterior epiglottis seen. Score 3 vocal cords plus posterior epiglottis seen, and score 4 only the vocal cords seen (18).

When ensuring proper anatomical placement, the device was fixed by tape to prevent mobility. After the complete placement of the device, the oropharyngeal pressure was measured by observing the aneroid manometer dial and noting which pressure caused the dial stability. At the time

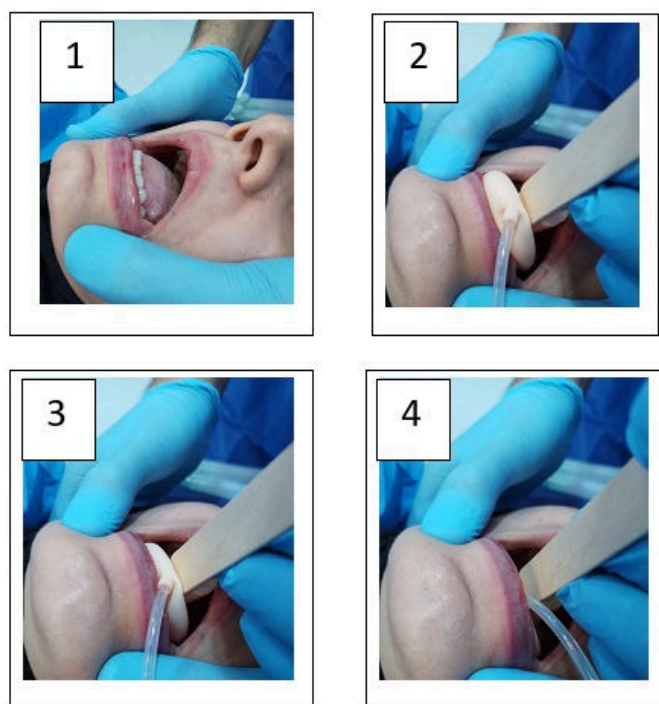


Fig. 2. Steps of insertion of RLMA using a wooden tongue depressor

of recovery, the mask was observed by an observer who was unaware of the procedure utilized and documented any bloody marks on the cuff after removal.

The primary outcome is the insertion time, which is defined as the time from placement of the device in the mouth until the connection to the breathing system.

The secondary outcome variables were the total time for successful placement, absent leak, fiberoptic view, oropharyngeal pressure, and blood-stained saliva on the cuff after recovery. The time to final placement was calculated from the start of ventilation until proper placement judged by the clinical evidence mentioned above.

Statistical analysis was performed using SPSS (Statistical Package for Social Sciences) version 23 (IBM, Chicago, Illinois, USA). Numbers and percentages were used to describe categorical variables, whereas continuous variables were expressed as means \pm standard deviations. Continuous data were compared using an independent sample t-test while categorical data were analyzed using Chi-square and Fisher exact tests. The Spearman rank correlation test was used to analyze the correlations between the fiberoptic examination and the leakage test. A P value < 0.05 was considered to indicate statistical significance.

Results

A total of 194 patients were enrolled in the study (97 patients in each group). The mean age of the study population was 34.6 ± 13.8 years. No significant difference in basic patients' demographic, anthropometric, and clinical characteristics was noticed between the two groups (Table 1).

As shown in Table 2, the insertion time was significantly shorter in group 2 (new method) than in group 1 (standard method). Similarly, a highly significant difference in total time for device placement in its anatomical position was seen between the two groups. Initial leaks were detected

more often in the control group than in the study otherwise this finding was not statistically significant.

The oropharyngeal pressure was comparable in the two groups ($p=0.674$).

The baseline pulse rate was comparable ($p=0.490$) in both groups, but after 5 and 10 minutes post insertion was significantly lower in the new method group. Similarly, the mean blood pressure was comparable ($p=0.561$) at baseline, but it was significantly lower among group 2 after 5 and 10 minutes post insertion.

Blood-stained saliva on the cuff was significantly ($p=0.033$) lower among patients in the new method group compared to those in the standard group.

At the initial assessment, about half (49.5%) of the new method group showed a fiberoptic score of 4 compared to 21.6% among the standard group with a highly significant difference ($p<0.001$) (Table 3).

In both methods, the mean oropharyngeal pressure increased slightly with increasing fiberoptic scores but without significant differences. Too, in both groups (standard and tongue depressor), the Spearman coefficient of rank correlation between the fiberoptic scores and oropharyngeal pressure showed no statistically significant correlation (correlation coefficient=0.051, $p=0.621$ and correlation coefficient=0.035, $p=0.732$ respectively) (Table 4).

Discussion

In clinical practice, the use of disposable materials reduces the risk of disease transmission, particularly during oral cavity instrumentation, as well as the amount of time necessary for preparation. Furthermore, operators are more satisfied with using disposable materials during pandemics. This will provide safety for patients and medical staff. Disposable wooden tongue depressors are among those materials that are used widely in medicine to examine the oral

Table 1. Basic patients' demographic and clinical characteristics

Character	Standard method No. (97)	New method No. (97)	P -value
Age (y); Mean \pm SD	34.3 \pm 14.8	34.80 \pm 12.8	0.820
Males, No. (%)	64 (66.0%)	57 (58.8%)	0.300
BMI (Kg/m ²); Mean \pm SD	22.1 \pm 1.7	22.3 \pm 1.5	0.314
Interincisor gap, Mean \pm SD	5.5 \pm 0.5	5.45 \pm 0.5	0.791
Mallampati class, No. (%)			
Class I	89 (91.8)	86 (88.7)	0.730
Class II	7 (7.2)	9 (9.3)	
Class III	1 (1.0)	2 (2.1)	

Table 2. Distribution of intraoperative and hemodynamic variables

Variables	Standard method No. (97)	New method No. (97)	P -value
Insertion time (sec.)	11.7 \pm 3.1	5.3 \pm 1.4	<0.001
Total time for successful placement (sec)	34.9.2 \pm 8.3	28.3 \pm 6.3	<0.001
Leak around the cuff	16 (16.5)	10 (10.3)	0.292
Oropharyngeal pressure (cmH ₂ O)	18.3 \pm 2.7	18.1 \pm 2.7	0.674
Pulse rate (Beats/minute)			
Baseline	87.1 \pm 3.8	86.7 \pm 4.1	0.490
After 5 minutes	91.5 \pm 6.4	85.7 \pm 6.0	<0.001
After 10 minutes	88.4 \pm 8.2	82.8 \pm 8.4	<0.001
Mean blood pressure (mmHg)			
Baseline	91.3 \pm 6.6	91.9 \pm 8.4	0.561
After 5 minutes	104.4 \pm 6.6	98.8 \pm 7.3	<0.001
After 10 minutes	99.6 \pm 9.1	92.9 \pm 9.4	<0.001
Blood stained saliva	10 (10.3)	2 (2.1)	0.033

Table 3. The fiberoptic laryngeal view among the two groups

Variables	Standard method No. (%)	New method No. (%)	P-value
Fiberoptic laryngeal view			<0.001
1	1 (1.0)	0 (0.0)	
2	31 (32.0)	11 (11.3)	
3	44 (45.4)	38 (39.2)	
4	21 (21.6)	48 (49.5)	

Table 4. Mean Oropharyngeal pressure according to fiberoptic scores

Fiberoptic scores	OPP (Mean \pm SD)	
	Standard method	Tongue depressor
1	15.0 \pm 0.0	0
2	18.2 \pm 2.7	17.9 \pm 2.4
3	18.2 \pm 2.8	18.1 \pm 2.9
4	18.4 \pm 2.8	18.2 \pm 2.7
P-value	0.698	0.960
Spearman's correlation Coefficient	0.051	0.035
P-value	0.621	0.732

cavity and throat inspection by many specializations and for any age group. As disposable, a tongue depressor is cheap, non-traumatic and simple to use. In this study, this tool was used with good results; RLMA was successfully inserted during the first attempt, and the overall time required for insertion was significantly shorter in the tongue depressor group than in the standard one. Others who used different techniques versus standard methods also reported varying insertion times (10, 19).

The initial leak around the cuff was minimum and only felt as a tactile sensation of airflow in 16 (16.5%) and 10 (10.3%) of the control and study groups respectively. Otherwise, this result is not statistically significant ($p=0.292$) and disappears after changing head position or device movement to achieve proper anatomic placement with significant results in fiberoptic view. The result is similar to that revealed by Ozgul et al (10). It seems that insertion technique is more important to facilitate proper anatomic placement. Absent leak corresponds to adequate seal and oropharyngeal pressure. Device stability was observed by high oropharyngeal pressure (20).

A higher Oropharyngeal leak pressure (OLP) is considered a good marker for providing positive ventilation effectively and protecting the airway from supra-cuff soiling (19). In the current study, the OLP was comparable in the two groups with no significant difference ($p=0.674$). The result is consistent with that of Kim et al (13). Our findings showed an ideal RLMA placement (Fiberoptic score of 3&4) in 88.7% of the tongue depressor group vs. 67% in the standard group. This is due to initial cuff inflation that ensures proper settlement without mobility, while cuff inflation after insertion results in movement and displacement, which is corrected by device manipulation or head repositioning. When the RLMA is not in an optimal position, it permits air to be vented during positive pressure ventilation (10).

To further explore the effect of the anatomic placement of the LMA on the ventilatory state, we relate the OLP to the fiberoptic laryngeal score (1, 2, 3, and 4). Our study showed no correlation between the fiberoptic score and OLP in both groups ($p=0.621$ and 0.732 , respectively). Though non-significant, the fiberoptic laryngeal score of 4

seemed to maintain the OLP high. The result is consistent with that of Kim et al. (13) and Choo et al (21). An observer who was blind to the technique evaluated trauma as blood-stained saliva or blood on the cuff following removal of the device in the recovery. It was seen in 10 (10.3%) and 2 (2.1%) of control and study groups, respectively, with a p -value of 0.033. This complication was previously reported in literature and with considerable incidence (8, 22, 23). The low incidence of trauma could be attributed to the quick and easy insertion as indicated by the short insertion time (24).

In the present study, the hemodynamic parameters were comparable in both groups at baseline, but there was a statistically significant difference at 5 and 10 minutes after insertion. The result is in agreement with that of Dhulkhed et al (25).

The current study has certain limitations. First, because the majority of patients had Mallampati class I or II, application to individuals with potentially troublesome airways needs to be evaluated. Second, before inserting the RLMA, a neuromuscular blocker was used. Thus, the insertion conditions may have been modified.

Conclusion

For laryngeal mask airway insertion, the wooden tongue depressor-aided method outperformed the standard digital insertion method. It is quick, easy, and inexpensive and can help accurate insertion of the reinforced laryngeal mask airway in a shorter time with minimum adverse effects.

Acknowledgment

We would like to thank the management of Basra University Medical Consultation Center, the anesthesiology staff, and our kind patients who contributed to the completion of this study.

Conflict of Interests

The authors declare that they have no competing interests.

References

- Hernandez MR, Klock PAJ, Ovassapian A. Evolution of the <http://mjiri.iums.ac.ir> Med J Islam Repub Iran. 2022 (17 Oct); 36.120.

- Extraglottic Airway: A Review of Its History, Applications, and Practical Tips for Success. *Anesth Analg*. 2012;114(2):349-68.
2. Gong Y, Wang J, Xu X, Li J, Song R, Yi J. Performance of Air Seal of Flexible Reinforced Laryngeal Mask Airway in Thyroid Surgery Compared With Endotracheal Tube: A Randomized Controlled Trial. *Anesth Analg*. 2020;130(1):217-23.
 3. Ozmete O, Sener M, Caliskan E, Kipri M, Aribogan A. The use of flexible laryngeal mask airway for Adenoidectomies: An experience of 814 Paediatric patients. *Pak J Med Sci*. 2017;33(4):823-8.
 4. Ramesh S, Jayanthi R. Supraglottic airway devices in children. *Indian J Anaesth*. 2011;55(5):476-82.
 5. Ryu JH, Yom CK, Park DJ, Kim KH, Do SH, Yoo SH, et al. Prospective Randomized Controlled Trial on the Use of Flexible Reinforced Laryngeal Mask Airway (LMA) During Total Thyroidectomy: Effects on Postoperative Laryngopharyngeal Symptoms. *World J Surg*. 2014;38(2):378-84.
 6. Naguib TM, Ahmed SA. Evaluation of Flexible Laryngeal Mask Airway® in Tongue Trauma Repair: A Randomized Trial. *Anesth Pain Med*. 2019;9(4):e92929.
 7. Sorbello M, Petrini F. Supraglottic airway devices: the search for the best insertion technique or the time to change our point of view? *Turk J Anaesthesiol Reanim*. 2017;45(2):76.
 8. Koo BW, Oh AY, Hwang JW, Na HS, Min SW. Comparison of standard versus 90° rotation technique for LMA Flexible™ insertion: a randomized controlled trial. *BMC Anesthesiol*. 2019;19(1):95.
 9. Sanuki T, Son H, Sugioka S, Komi N, Hirokane M. Comparison of metal stylet, small tracheal tube and combined introducer-aided insertions of the flexible reinforced laryngeal mask airway with the conventional method: a manikin study. *J Anesth Clin Res*. 2011;2:147.
 10. Ozgul U, Erdil FA, Erdogan MA, Begec Z, Colak C, Yucel A, et al. Comparison of videolaryngoscope-guided versus standard digital insertion techniques of the ProSeal™ laryngeal mask airway: a prospective randomized study. *BMC Anesthesiol*. 2019;19(1):244.
 11. Sanuki T, Nakatani G, Sugioka S, Daigo E, Kotani J. Comparison of the Ambu AuraFlex with the laryngeal mask airway Flexible: a manikin study. *J Oral Maxillofac Surg*. 2011;69(7):e269-e72.
 12. Kulkarni A, Simon B, Jose J. A new flexible laryngeal mask airway introducer. *Indian J Anaesth*. 2012;56(1):94.
 13. Kim DH, Chae YJ, Min SK, Ha EJ, Yoo JY. Lightwand-Guided Insertion of Flexible Reinforced Laryngeal Mask Airway: Comparison with Standard Digital Manipulation Insertion. *Med Sci Monit*. 2021;27:e928538.
 14. Jannu A, Shekar A, Balakrishna R, Sudarshan H, Veena G, Bhuvaneshwari S. Advantages, disadvantages, indications, contraindications and surgical technique of laryngeal airway mask. *Arch Craniofac Surg*. 2017;18(4):223.
 15. Miller JB, Schoenberg MR, Bilder RM. Consolidated Standards of Reporting Trials (CONSORT): Considerations for Neuropsychological Research. *Clin Neuropsychol*. 2014;28(4):575-99.
 16. Whitley E, Ball J. Statistics review 4: sample size calculations. *Crit Care*. 2002;6(4):335-41.
 17. Singh M, Anand L, Singh J, Kapoor D. "PUSH" as a mnemonic for Modified Mallampati classification. *J Anaesthesiol Clin Pharmacol*. 2020;36(4):568-9.
 18. Eglen M, Kuvaki B, Günenç F, Ozbilgin S, Küçükgüçlü S, Polat E, et al. [Comparison of three different insertion techniques with LMA-Unique™ in adults: results of a randomized trial]. *Rev Bras Anesthesiol*. 2017;67(5):521-6.
 19. Zhang L, Seet E, Mehta V, Subramanyam R, Ankichetty SP, Wong DT, et al. Oropharyngeal leak pressure with the laryngeal mask airway Supreme™ at different intracuff pressures: a randomized controlled trial. *Can J Anaesth*. 2011;58(7):624-9.
 20. Kim GW, Kim JY, Kim SJ, Moon YR, Park EJ, Park SY. Conditions for laryngeal mask airway placement in terms of oropharyngeal leak pressure: a comparison between blind insertion and laryngoscope-guided insertion. *BMC Anesthesiol*. 2019;19(1):4.
 21. Choo CY, Koay CK, Yoong CS. A randomised controlled trial comparing two insertion techniques for the Laryngeal Mask Airway Flexible™ in patients undergoing dental surgery. *Anaesthesia*. 2012;67(9):986-90.
 22. Michalek P, Donaldson W, Vobrubova E, Hakl M. Complications Associated with the Use of Supraglottic Airway Devices in Perioperative Medicine. *Biomed Res Int*. 2015;2015:746560-.
 23. Liu Y-C, Cherng C-H. A modified tongue depressor facilitates the insertion of ProSeal laryngeal mask airway: Comparison with digital and introducer techniques. *J Chin Med Assoc*. 2017;80(9):582-6.
 24. Xu R, Lian Y, Li WX. Airway Complications during and after General Anesthesia: A Comparison, Systematic Review and Meta-Analysis of Using Flexible Laryngeal Mask Airways and Endotracheal Tubes. *PLoS One*. 2016;11(7):e0158137.
 25. Dhulkhed PV, Khyadi SV, Jamale PB, Dhulkhed VK. A Prospective Randomised Clinical Trial for the Comparison of Two Techniques for the Insertion of Proseal Laryngeal Mask Airway in Adults-Index Finger Insertion Technique versus 90° Rotation Technique. *Turk J Anaesthesiol Reanim*. 2017;45(2):98-102.