

HISTOPATHOLOGICAL STUDY OF TCDD BY ISOLATED RAT LIVER PERFUSION SYSTEM

M. KARAMI, M. GHAZI-KHANSARI,* M. REZAYAT,* B. MINAEI,**
M. ABDOLLAHI AND O. SABZEVARI

*From the Department of Toxicology, School of Pharmacy,
Tehran University of Medical Sciences, and the Departments of *Pharmacology
and **Histology, School of Medicine,
Tehran University of Medical Sciences, Tehran, I.R. Iran.*

ABSTRACT

2,3,7,8-tetrachlorodibenzo-p-dioxin (TCDD) is a by-product of the trichlorophenol (herbicide) production and is also produced through a variety of combustion processes. It appears that TCDD is a ubiquitous chemical, particularly in industrialised countries, and the liver is the target organ of its toxicity. The prominent hepatotoxic effect of TCDD is progressive centrilobular necrosis. The isolated rat liver perfusion system approaches the normal physiology of the liver and is ideal for studying biochemical alterations of the liver since hepatocytes are easily exposed to various concentrations of chemicals with minimum neural-hormonal effects. In this study, the liver was perfused with Krebs-Henseleit buffer containing different concentrations of TCDD (0.3, 3, 20 and 30 µg/L). During the perfusion many factors including gross liver appearance, bile formation, and aminotransferase activities were assessed as indicators of liver viability. Consequently, sections of liver tissue were examined for any histopathological changes. The results showed that histopathological changes in liver tissues were related in a dose-dependent manner to TCDD concentrations. In this instance doses of 20 and 30 µg/L caused a significant ($p<0.05$) histopathological change in liver sections. Liver necrosis and hemorrhage were also increased significantly in a dose-dependent manner.

MJIRI, Vol. 15, No. 1, 55-60, 2001.

Keywords: TCDD, Liver perfusion, Krebs-Henseleit buffer, Histopathological, necrosis.

INTRODUCTION

The environmental pollutant 2,3,7,8-tetrachlorodibenzo-p-dioxin (TCDD) has received much attention over the past few decades.¹ It is a highly toxic compound which is found as a contaminant in phenoxy acid, herbicides, chlorophenol, and also as a by-product during synthesis of industrial halogenated compounds. It has also been produced by various combustion pro-

cesses.^{2,3} The amount of TCDD increases as the temperature and pH (alkalinity) of the reaction increases since they make the compound more stable to breakdown by acids, bases, heat and hydrolysis.^{3,4} Therefore, these are important factors which contribute to the widespread environmental problems of TCDD.³ Moreover, because of the lipophilicity of TCDD, it bioaccumulates in the food chain (fish, wild life, and human adipose tissue, milk, and serum)³ and has been found in deep soil (highly resistant) which will be destroyed when exposed to sunlight.⁵ Due to the ubiquitous nature of TCDD, it is found in most industrialized countries.⁴

*Correspondence: M. Ghazi-Khansari, Ph.D., Department of Pharmacology, School of Medicine, Tehran University of Medical Sciences, P.O.Box: 13145-784, Tehran, Iran. E-mail: ircongpp@nrcgeb.ac.ir

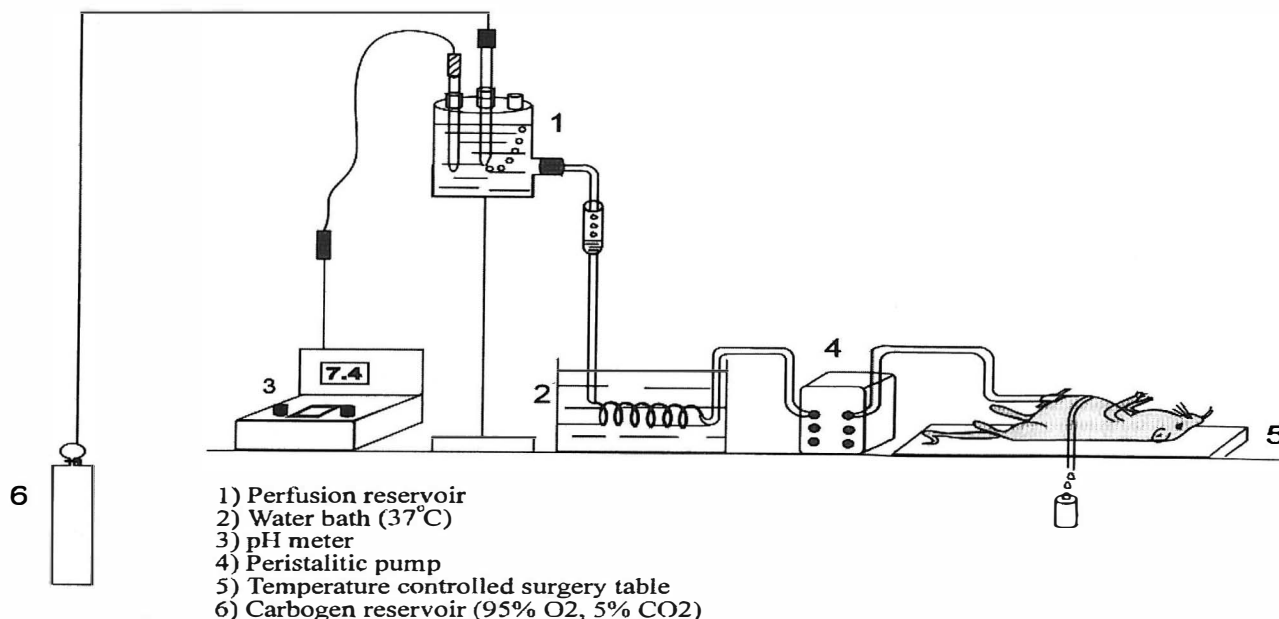


Fig. 1. Schematic diagram of a rat liver perfusion system. Catheters are inserted into the portal vein and inferior vena cava. Perfusion is pumped from a central reservoir by an oscillating pump through an 80 μ m nylon filter. Before entering the liver oxygenation takes place through an oxygenator containing 95% O₂ and 5% CO₂.

Toxic effects of TCDD include wasting syndromes (which can lead to death), porphyria, fibrosis, fatty metamorphosis and liver degeneration. Liver degeneration and immunobiological effects are the most important recorded symptoms.^{2,6} The immunodepressant effect of TCDD appears to be selective and in any case differs from the non-specific immunodepression induced by classic cytotoxic agents.⁷ Accumulation of TCDD in the liver may produce a variety of effects such as hyperplastic nodules and hepatocellular carcinoma.⁸ In this study isolated rat liver perfusion was employed to study TCDD hepatotoxicity and its correlation to histopathological changes.

MATERIAL AND METHODS

Animals

Male albino Wistar rats (6-8 weeks) weighing 200-250g were used in this experiment. They were housed individually in standard rat cages in a room on a 12h light-dark cycle at 22°C and 50 \pm 5% relative humidity, with free access to standard diet and tap water until use. The animals were adapted to the conditions for 7 days

before starting of the experiments.⁹⁻¹⁰

TCDD

2,3,7,8-tetrachlorodibenzo-p-dioxin was purchased from Sigma Co. The substance was dissolved in distilled water/DMSO (10:1) and kept in the dark.⁹

Experimental design

Rats were divided into four treatment groups and one control group. Each group contained four male rats and their livers were perfused by a single dose of 0.3, 3, 20 and 30 μ g/L of TCDD, respectively. Control livers were perfused with the perfusion buffer. Following the preliminary study, the dose of 20 μ g/L was chosen for the rest of the study in order to evaluate the toxicity of TCDD.⁹

Buffer

Perfusion fluid was made of Krebs-Henseleit buffer. The perfusion medium consisted of 118.9 mM NaCl, 4.76 mM KCl, 1.19 mM KH₂PO₄, 2.55 mM CaCl₂ and 24.8 mM NaHCO₃ at 37°C. Glucose (1% w/v) is usually added to provide an energy source.¹¹ The perfusion medium was

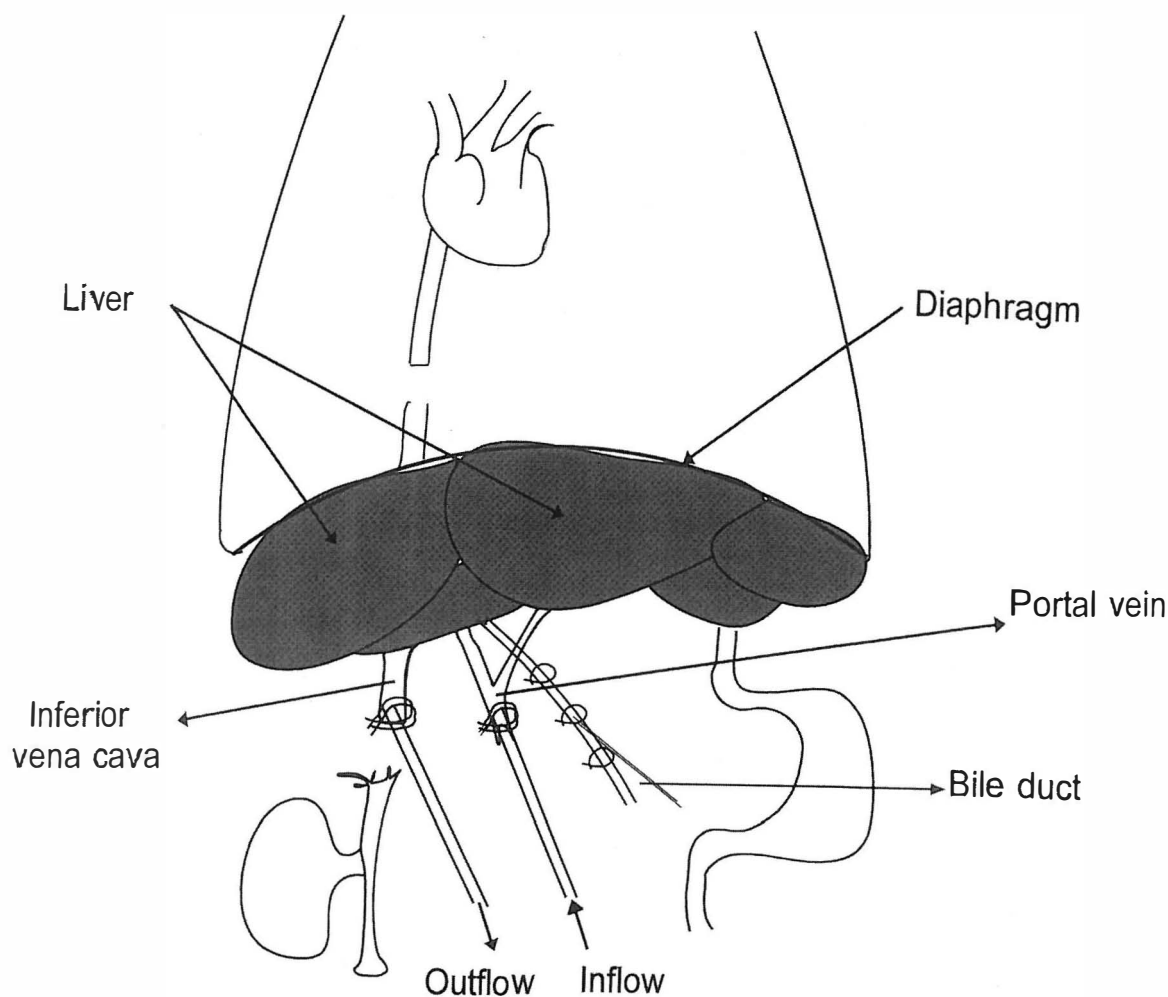


Fig. 2. The surgical removal of the liver for isolated perfusion.

gassed continuously with carbogen (95%O₂, 5%CO₂) (Fig. 1).

Perfusion conditions and parameters of liver viability

Temperature, perfusion pressure, flow rate and perfusion fluid pH were closely monitored during the perfusion, particularly during the first 30 min of equilibration.¹¹ These parameters were initially checked every 10 to 15 min and the experiment was not begun until they had reached constant and acceptable values. The temperature in the perfusion system was also set and maintained at 37°C. Perfusion pressure was not raised above 10-15 cm of water with a flow rate of approximately 2 mL/min/g liver weight to provide adequate oxygenation.

The perfusion fluid pH was always set between 7.2 and 7.4 by adjusting the CO₂ gases. As soon as perfusion was begun, the liver developed an even, light-brown color, was soft and was kept moistened. Blotches or discoloration meant that the liver was not well perfused. Serum aminotransferase activities (SGPT and SGOT) serve as indicators of liver viability during perfusion which were determined in samples of perfusion medium (Fig. 3).

Surgery

The rats were anesthetised with ether. Heparin (500 units; I.P.) was used to prevent blood clotting prior to anesthesia.^{11,12} An incision was made along the length of the abdomen to expose the liver. The bile was collected,

sutures were placed loosely around the common bile duct, which then was cannulated with PE-10 tubing and secured. Sutures were then placed loosely around the inferior vena cava, above and below the renal veins. The distal suture around the vena cava was tightened and an 18g polyethylene catheter was inserted, placed above the renal vein and secured with the proximal suture. The portal vein was immediately cannulated with an 18g catheter which was secured. The diaphragm was incised and the inferior vena cava ligated suprahepatically. Following attachment of the perfusion tubing to the cannulate, the liver was perfused in situ through the portal vein.¹¹ Following 30-45 min, 20 µg/L of TCDD was perfused for 2hr and samples of perfused fluid were collected for assessment of any liver injury (Fig. 2).

Histological studies

The liver was completely excised and freed of any extraneous tissue. Multiple samples were then taken from each liver (mean 3 mm) and placed in 10% neutral buffered formalin. The liver was cut into small pieces, sections prepared and stained by Eosin-Hematoxylin and examined for histopathological changes. Sections were analysed blind and the extent of hemorrhage and necrosis graded separately (0 to +3).¹² 1) Hemorrhage was evaluated according to the extent of hemorrhage as follows: If one lobule of liver showed hemorrhage, this was graded as +, two lobules of liver were graded as ++ and if all of the lobules showed hemorrhage this was graded as +++. 2) Necrosis was evaluated both macroscopically and microscopically in different samples of liver tissue according to the extent of necrosis and degeneration as follows: If one lobule of the liver showed necrosis, this was graded as +, two lobules of the liver would be graded as ++, and if necrosis was present in all the lobules of the liver, this was graded as +++. 3) Kupffer cells were scored according to the following: If primary injury occurred this was scored as +, mild injury was scored as ++ and if severe injury had occurred, it was scored as +++.

Statistical analysis

All values were expressed as mean±SEM of 4 rats. Fisher's exact test was used to evaluate the significance of the obtained results. All computations were made by a computer using statistical analysis system (SAS) software.

RESULTS

Histopathological changes in the liver due to TCDD

In comparison with control (Table I), perfusion of rat liver with Krebs-Henseleit buffer containing various concentrations of TCDD (0.3, 3, 20 and 30 µg/L) showed

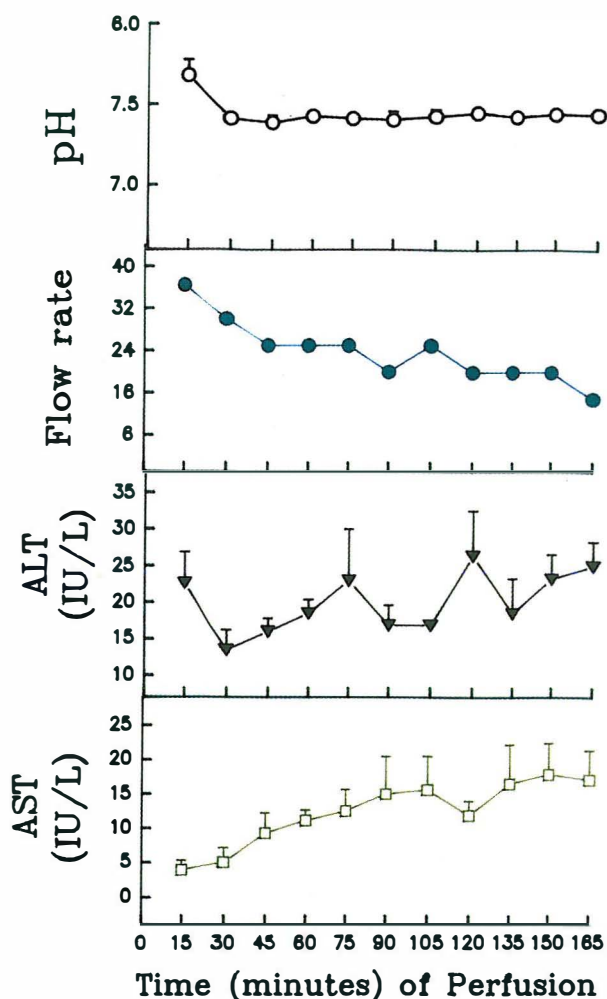


Fig. 3. Evaluation of viability of the perfused rat liver by different parameters.

a concentration-dependent increase in histopathological changes of liver tissue sections. Perfusion of 0.3 and 3 µg/L TCDD had no significant effect on the liver tissue. However perfusion of 20 and 30 µg/L of TCDD caused significant histopathological damage of liver tissue when compared to control ($p<0.05$, $p<0.01$, respectively). Maximum damage was observed with the dose of 30 µg/L TCDD (Table I).

Light microscope observation

Histopathological studies using a light microscope showed significant hepatocellular damage including necrosis and infiltration due to TCDD (Fig. 4b) when compared to control (Fig. 4a). In addition, other histopathological parameters including the number of Kupffer and mononuclear cells, edematous cells and cell degeneration had changed significantly with TCDD concentrations of 0.3, 3, 20 and 30 µg/L (Table I).

Table I. Histopathological effects of TCDD using rat liver perfusion.

Histopathological parameters	Control	TCDD ($\mu\text{g/L}$)			
		0.3	3	20	30
Kupffer cells	+	+	++*	+++**	+++**
Edematous cells	+	-	+	++*	+++**
Mononuclear cells	+	+	+	+++*	+++**
Degeneration	-	-	+	++*	+++**
Necrosis	-	-	-	+	+++**

- No effect, +Minor effect, ++Medium effect, +++Major effect.

* $p < 0.05$, ** $p < 0.01$, significantly different from control using Fisher's exact test. Data are means of three replicates.

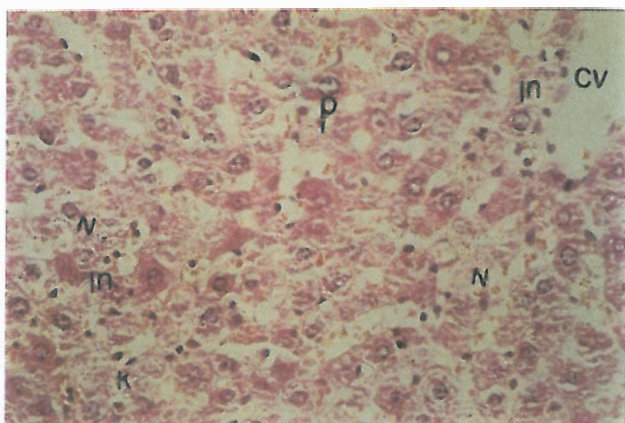
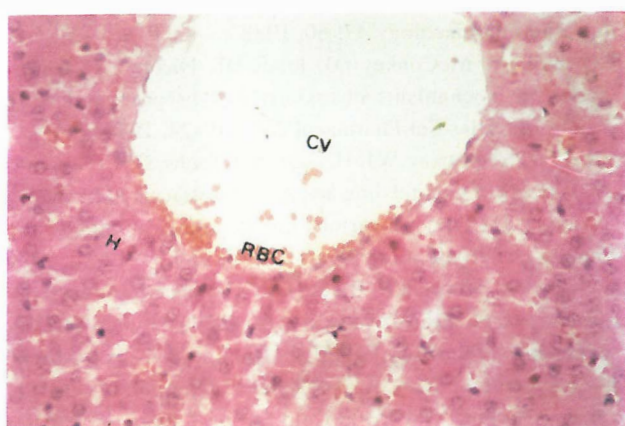


Fig. 4. Photomicrograph of the lobules from control and TCDD-treated liver. Control shows red blood cells (RBC), hepatocytes (H) and central veins (CV). Staining shows the cytoplasm was acidophilic and surrounded by a bright basophilic nucleus (a). TCDD perfused liver (20 $\mu\text{g/L}$) shows limited changes in lobules of liver and hepatocellular necrosis (N) with infiltration (IN) of mononuclear cells and accumulation of necrotic Kupffer cells (K) with pyknotic (P) nuclei (b).

DISCUSSION

The liver has been identified as the primary and most important tissue target for 2,3,7,8-TCDD in rats.¹³ Our data showed that administration of TCDD causes edema which can be assessed by histopathological examination (Table I). This finding is in agreement with the fact that an oncotic agent can cause increase in pressure.¹⁴ In addition, isolated organs have a time-dependent tendency to absorb water, as with a relatively protein-free medium water gradually escapes from the vascular space and therefore interstitial edema develops.^{12,15} Histopathological examinations revealed significant hemolysis as assessed by the hemolytic index (Fig. 4b). This can be due to altered calcium hemostasis concomitant with a significant increase in cytosolic calcium as has been previously reported for TCDD in the liver.⁶ Moreover, the disturbances of intracellular calcium homeostasis have been shown to be associated with a variety of toxicological and pathological processes.^{17,18} Accumulation of TCDD in the liver as the target organ has been shown to cause degeneration.² In a similar manner the results of this study also showed liver degeneration (Table I). This, in fact, could be as a result of TCDD receptor binding which is sufficient to affect different cells.¹⁹

In this study significant necrosis was also observed in the liver at TCDD doses of 20 and 30 $\mu\text{g/L}$. TCDD induces formation of reactive oxygen species and an oxidative stress, resulting in lipid peroxidation,^{20,21} which may explain the observed necrosis (Fig. 4b). We have also observed cell death followed by cell proliferation with hyperplasia and hyperplastic nodules in Kupffer cells by TCDD. Similar findings were reported for chlorinated hydrocarbon pesticides by Essigman and Newberne.²² Therefore, the results of our study, in agreement with others,^{13-16,20,22} demonstrate that liver perfusion is a suitable model to study the hepatotoxicity of chemi-

Histopathological Effect of TCDD on Rat Liver

cals (i.e. TCDD). More studies, however, are needed to further elucidate the exact mechanism by which TCDD induces hepatotoxicity.

REFERENCES

1. Funseth E, Ilback NG: Coxsackie virus B3 infection alters the uptake of 2,3,7,8-tetrachlorodibenzo-p-dioxin into various tissues of the mouse. *Toxicology* 90: 29-38, 1994.
2. Leung HW, Wendling JM, Orth R, Hilman F, Paustenbach DJ: Relative distribution of 2,3,7,8-tetrachlorodibenzo-p-dioxin in human hepatic and adipose tissues. *Toxicology Letters* 50: 275-282, 1990.
3. Stephen DP: Polychlorinated biophenyls, dibenzo-p-dioxins, dibenzofurans, and related compounds. *Toxicology* 21: 51-87, 1990.
4. Tschirley FH: Dioxin. *Scientific American* 2: 29-35, 1986.
5. McConnell EE, Lucier GW, Rumbaugh RC, Harvan DJ, Hass JR, Harris MW: Dioxin in soil: bioavailability after ingestion by rats and guinea pigs. *Science* 223: 1077-1079, 1984.
6. Brown MM, McCready TL: Factors affecting the toxicity of dioxin-like toxicants: molecular approach to risk assessment of dioxins. *Toxicology Letters* 61: 141-147, 1992.
7. Garantini S: TCDD toxicology with particular reference to seveso: introductory remarks. *Drug Metabolism Reviews* 13 (3): 345-353, 1982.
8. Pitot HC, Goldswothy T, Campbell HA: Quantitative evaluation of the promotion by 2,3,7,8-tetrachlorodibenzo-p-dioxin of hepatocarcinogenesis from diethylnitrosamine. *Cancer Research* 40: 3616-3620, 1980.
9. Chahoud I, Hartmann J, Rune GM, Nubert D: Reproductive toxicity and toxicokinetics of 2,3,7,8-tetrachlorodibenzo-p-dioxin. *Archives of Toxicology* 66: 567-572, 1992.
10. Dehpour AR, Essalat M, Ala S, et al: Increase by NO synthase inhibitor of lead-induced of N-acetyl- β -D-glucosaminidase from perfused rat kidney. *Toxicology* 132: 119-125, 1999.
11. Wolkoff AW: The isolated perfused rat liver: preparation and application. *Analytical Biochemistry* 167: 1-14, 1987.
12. Cheung K, Hickman PE, Potter JM, Potter JM, Walker NI, Jericho M, Haslam R, Roberts M: An optimized model for rat perfusion studies. *Journal of Surgical Research* 66: 81-89, 1996.
13. Keenan RE, Paustenbach DJ, Wenning RJ: Pathology re-evaluation of Kociba et al's bioassay of 2,3,7,8-TCDD: implications for risk assessment. *Journal of Toxicology and Environmental Health* 34: 279-296, 1991.
14. Rosini S, Benetti D, Kvetina J: The functional capacity of the isolated perfused rat liver in relation to the colloidal osmotic composition of the perfusion medium. *Farm Pract* 31: 625, 1976.
15. Mischinger HJ, Walsh TR, Liu TR: An improved technique for isolated perfusion of rat liver and an evaluation of perfusates. *Journal of Surgical Research* 53: 158, 1992.
16. Al-Bayati ZA, Murray WJ, Pankaskie NC: 2,3,7,8-tetrachlorodibenzo-p-dioxin (TCDD) induced calcium distribution in rats. *Research Communicant Chemical Pathology and Pharmacology* 47: 60, 1988.
17. Orrenius S, McConkey DJ, Jones DP, Nicotera P: Ca^{2+} -activated mechanisms in toxicity and programmed cell death. *ISI Atlas Sci Pharmacol* 2/4: 319-24, 1988.
18. Wahba ZZ, Murray WJ, Hassan MQ, Stohs SJ: Comparative effects of pair-feeding and 2,3,7,8-tetrachlorodibenzo-p-dioxin (TCDD) on various biochemical parameters in female rats. *Toxicology* 59: 311-323, 1989.
19. Malby TA, Moore RW, Bjerke DL: The male reproductive system is highly sensitive to in utero and lactational TCDD exposure. In: Banbury Report 35: Biological Basis for Risk Assessment of Dioxin and Related Compounds. Cold Spring Harbor, New York: Cold Spring Laboratory Press, pp. 69-78, 1991.
20. Shibayama Y: Role of lipid peroxidation in enhancement of endotoxin hepatotoxicity. *Exp Toxic Pathol* 44: 205-208, 1992.
21. Wahaba ZZ, Murray WL, Stohs SL: Altered hepatic iron distribution and release in rats after exposure to 2,3,7,8-tetrachlorodibenzo-p-dioxin. *Bull Environ Contam Toxicol* 45: 436-445, 1990.
22. Essigman EM, Newberne PM: Enzymatic alteration in mouse hepatic nodules induced by a chlorinated hydrocarbon pesticide. *Cancer Research* 41: 2823-2831, 1991.