

THE PROTECTIVE EFFECT OF INDOMETHACINE ON SULFUR MUSTARD-INDUCED OCULAR DAMAGE IN THE RABBIT EYE

S. N. OSTAD, Pharm.D, Ph.D., A. KEBRIAEE-ZADEH, Pharm.D., Ph.D.,
R. ZAREKAMALI, Pharm.D., M. ABDOLLAHI,* Pharm.D., Ph.D., H.
MARZBAN,* Ph.D., AND M. AKHGARI, Pharm.D.

*From the Department of Toxicology and Pharmacology,
Faculty of Pharmacy, and the *Department of Anatomy and Embryology,
Faculty of Medicine, Tehran University of Medical Sciences, Tehran, I.R. Iran.*

ABSTRACT

Sulfur mustard, a bifunctional alkylating agent, causes severe eye injury. The injury is a result of late inflammation, which is mediated by prostaglandins. Theoretically, inhibition of prostaglandins by reagents such as indomethacine could result in alleviation of clinical adverse effects. In this study, the protective effect of topically applied indomethacine against sulfur mustard toxicity was assessed on the rabbit eye. Ocular toxicity was studied by using light microscopy, electron microscopy and visual inspection methods. Methods used in this assay showed that 100 μ L of indomethacine solution (0.5% W/V) two hours before exposure and throughout the experiment could markedly decrease the toxic effects of mustard.

MJIRI, Vol. 14, No. 4, 385-391, 2001.

Keywords: Mustard, Inflammation, Cornea, Indomethacine, Eye, Ocular

INTRODUCTION

Sulfur mustard [bis (2-chloroethyl) sulfide, HD], a bi-functional alkylating agent, can cause severe eye injury. This is one of the chemical weapons that has been widely used during World War I and the Iraq-Iran war. Lacrimation, conjunctival inflammation, hyperemia and ocular pain are early toxic effects of mustard gas on the eye.⁸ Many chemical mediators including substance P (SP) and prostaglandins (PGs) participate in the occurrence of these effects.¹⁸ It has been shown that administration of neurotoxic agents such as capsaicin produce a depletion of neuropeptides from primary afferent neurons and a suppression of neurogenic inflammation.^{7,9} The cornea is innervated by A-delta and C sensory fibers that terminate as unmyelinated nerve endings within the corneal epithelium¹⁴ and act like polymodal

nociceptors functionally.¹ Some of these sensory afferent fibers contain SP and calcitonin-gene related peptide (CGRP).^{15,17} SP is one of the nervous chemical mediators which causes the same effect as HD when it is injected intraocularly. SP also stimulates the synthesis of PGs that cause a gradual increase in intraocular pressure. PGs play an important role in the occurrence of intraocular inflammation. Increased levels of PGs or PG-like activity are found in the aqueous humor of patients with untreated acute anterior uveitis. In experimental animals, PGs were reported to mediate, at least in part, the breakdown of the blood-aqueous barrier induced by intra-vitreous injection of bovine serum albumin⁶ or bacterial endotoxin² and mechanical stimulation of the iris.⁵ In contrast to the previously cited evidence of PG involvement in ocular inflammatory responses, pretreatment with an inhibitor of PG synthesis does not inhibit the rise in aqueous humor protein concentration produced by typical nitrogen mustard application.¹³ On the basis of these and similar observations after formaldehyde administration or trigeminal nerve stimulation, it was concluded that PGs play an important role in some, but not all,

Corresponding address: S.N. Ostad, Department of Toxicology, Faculty of Pharmacy, Tehran University of Medical Sciences, P.O.Box: 14155/6451, Tehran, I.R. Iran. E Mail: snostad@yahoo.com.

Indomethacine Prevents Ocular Damage

forms of ocular inflammation.⁶ Because indomethacine is the most powerful compound that inhibits PG synthesis, it was chosen for this study.

MATERIAL AND METHODS

Animals

Albino white rabbits (1.5-2 kg) were bred on house and acclimated before the experiment. Animals were housed in single cages, with constant temperature (25°C) and moisture. They had free access to food and water.

Solutions

Sulfur mustard 0.5%: 5 μ L sulfur mustard was added to 1 mL propylene glycol and was kept at -20°C in a freezer. The solution was thawed just before the experiment.

Indomethacine 0.5%: 0.5 g indomethacine was added to 100 mL phosphate buffer (pH=7.4) and was isotoned with a proper amount of NaCl solution.

Experimental groups

Animals were randomly divided to eight groups. In each group seven animals were examined:

Group one: 100 μ L indomethacine solution was applied topically in the examined eye two hours before administration of 50 μ L sulfur mustard.

Group two: 100 μ L indomethacine solution was applied topically in the examined eye two hours before administration of 50 μ L sulfur mustard and then the animals received 100 μ L of indomethacine solution in the eye every day for one week.

Group three: 100 μ L indomethacine solution was applied topically in the examined eye two hours before administration of 50 μ L sulfur mustard and then the animals received 100 μ L of indomethacine solution in the eye every day for one month.

Group four to six: similar to groups one to three, they received sulfur mustard for the same time as positive controls and group seven received only solvent as blank. Another group of animals were used as independent controls. After visual inspection at the end of the experiment, animals were sacrificed by cervical dislocation, then the eyes of 4 animals in each group were removed and the cornea was detached aseptically for further study. The rest of the corneas were prepared by histological technique for light and electronic microscopic study.

Determination of mitochondrial dehydrogenase activity

100 μ L/mL of 3-[4,5-dimethyl thiazol-2yl]-2,5 diphenyl tetrazolium bromide (MTT, 2 mg/mL) was added to corneas. Mitochondrial dehydrogenase of viable cells cleaves the tetrazolium ring of the yellow MTT to yield purple formazan crystals, which are insoluble in aqueous solution. The crystals were dissolved in acidified propan-2-ol and the

UV absorbance of the resulting purple solution was determined at 570 nm against 690 nm for blank solution according to Mossman's method (1983). The amount of produced formazan is proportional to the number of viable cells.

Scanning electron microscopy study

Animals were sacrificed and whole eyes were immediately dissected. Corneas were fixed in 3.6% (w/v) glutaraldehyde in phosphate buffer. The tissue was then post fixed in 2% osmium tetroxide. Dehydration was performed using a graded ethanol series, ending with absolute ethanol. Tissues were then immersed in ter-butanol and dried with freeze point dehydration method. Dried specimens were carefully mounted on graphite stubs and sputter-coated with gold in an argon atmosphere at 0.15 Torr for a total of 4 minutes. Samples were examined in a Steroscan 360^R scanning electron microscope.

Light microscopy study

Corneas were fixed in 10% formaldehyde and dehydrated in ascending grades of ethanol and then in xylene. Tissues were embedded in paraplast plus paraffin wax following a routine procedure. Sections of 5 μ m thickness were cut and mounted on glass slides. For routine morphological examination, tissue sections were stained with Harris Haematoxylin and Eosin (H & E).

Intraocular pressure (IOP) and hyperemia measurement

The normal IOP of conscious animals was measured with a pneumatic floating tip tonometer.³ IOP values were corrected to calibration curves obtained on conulated rabbit eyes. The degree of hyperemia in the eye was classified as + to ++++ on the basis of color of the tissue and engorgement of blood vessels.⁴ Results obtained from this experiment were compared by using paired t-student test.

RESULTS

In the control group treated by sulfur mustard (HD) alone, IOP was increased after 30 minutes. This elevation remained for 240 minutes after administration of HD and then decreased to normal (Fig. 1). On the second day, IOP increased to 40 mmHg and after 7 days decreased to normal. 14 days after the experiment, IOP decreased to amounts below that of the beginning of the experiment and remained so for one month (Fig. 2). In the test group that was treated by sulfur mustard and indomethacine, IOP decreased after 20 minutes and this level was maintained for the whole time of the experiment, however after 600 minutes the level of IOP returned to normal. Furthermore, the effect of HD was totally inhibited by administration of indomethacine. (Fig. 3). Figure 4 shows that indomethacine could prevent primary ocular pressure increase induced by sulfur mustard. In Figure 5 indomethacine could prevent the reduction of ocular pres-

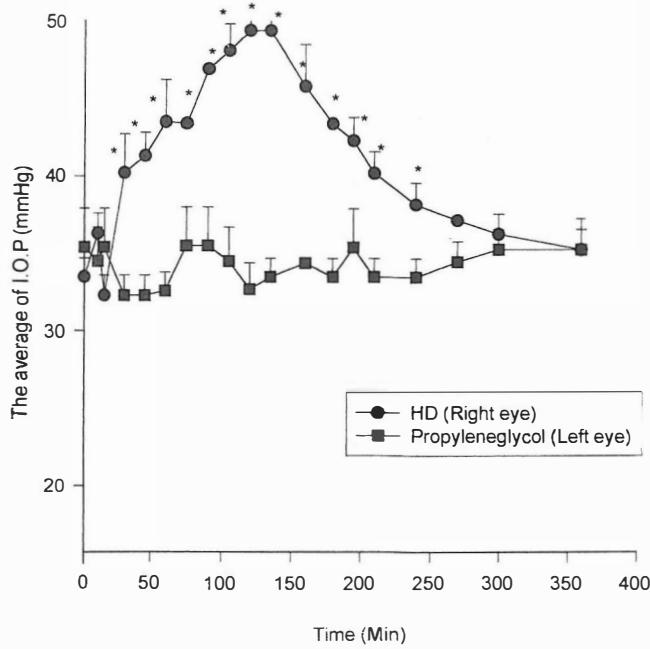


Fig. 1. Comparison of the effect of HD and Vehicle (n=3, \pm SD; * p <0.05).

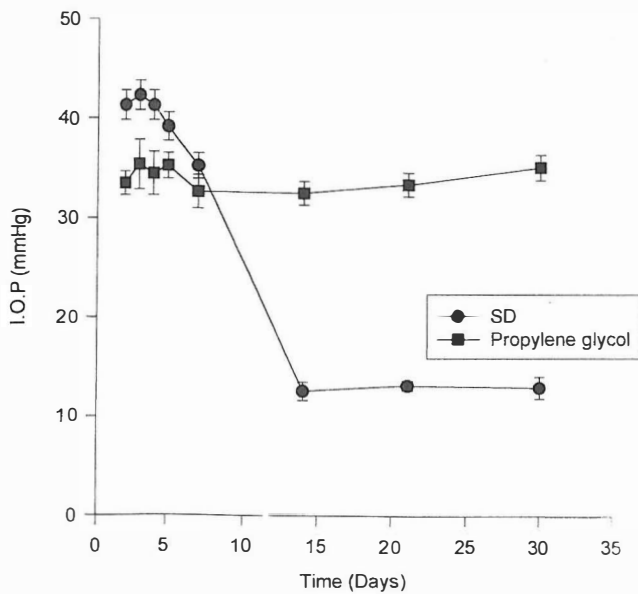


Fig. 2. The effect of HD compared to vehicle after 30 days (n= 3, Mean \pm SEM, (p <0.05).

sure dueto ocular damage. Hyperemia gradually developed shortly after applying sulfur mustard and increased to a maximum in about 4 hours. This hyperemia was maintained for one week. During this period inflammation gradually decreased. Late inflammation started from the 21st day. In the group that received indomethacine alone, the intensity of hyperemia was less than the control group one month after the experiment. Primary inflammation was not observed in this group. Table I shows the measurement of hyperemia at different times of observation. As it is shown in this table,

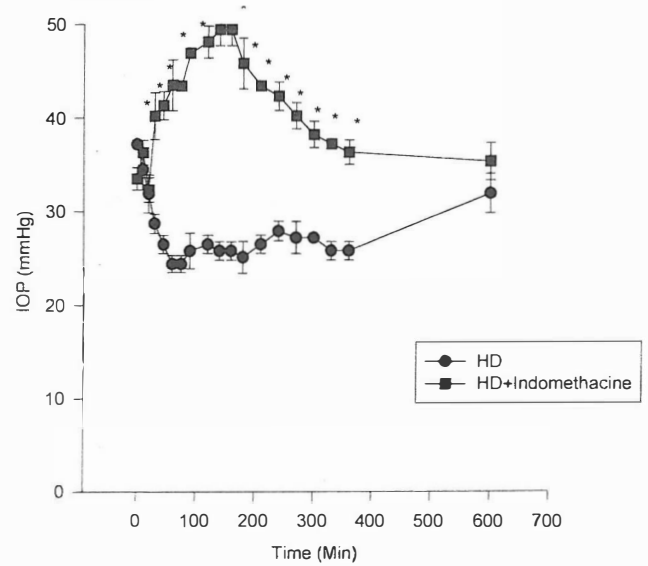


Fig. 3. The effect of indomethacine on IOP when used by HD concurrently (n= 3, Mean \pm SEM, p <0.05).

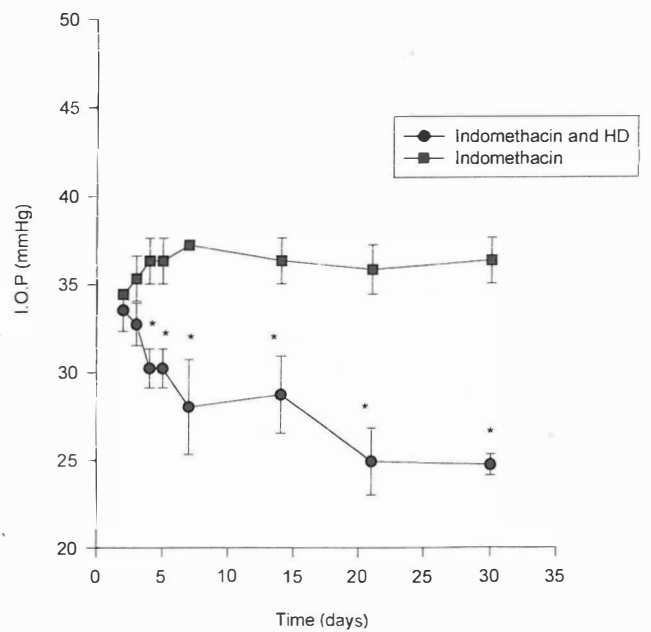


Fig. 4. The effect of indomethacin in the rabbit eye when it is administered concurrently with HD after one month (n= 3, \pm SD; * p <0.05)

the intensity of hyperemia decreases in the experimental group when compared with controls.

In the control group, late inflammation resulted in complete destruction of the cornea. In one case, tumors or hyperplasia of internal tissue such as substantia propria were observed. Pictures 1 to 3 show the control group and 4 to 6 the animals which were treated by indomethacine 1, 7 and 30 days after applying sulfur mustard respectively. The degree of inflammation and hyperemia was reduced in the latter groups indicating the protective effect of indomethacine,

Indomethacine Prevents Ocular Damage

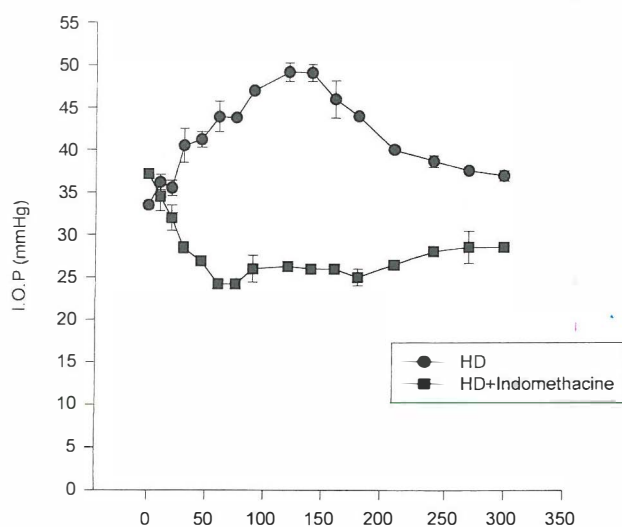
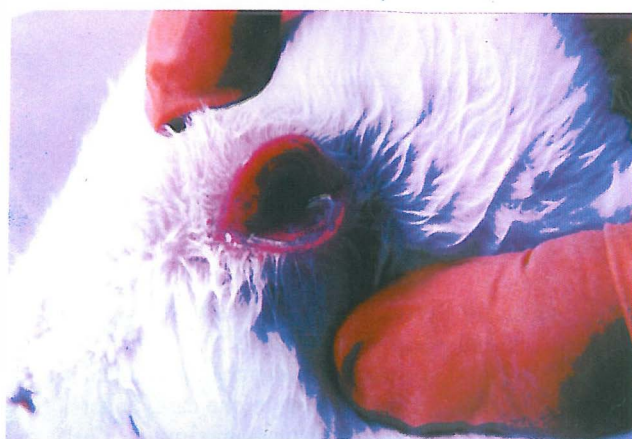

Fig. 5. Rabbit eye (right) one week after administration of HD+Ind. Note primary hyperemia which was not prevented by indomethacine.

Table I. The effect of 50 μ L sulfur mustard (HD) 0.5% on hyperemia in comparison with adding a single dose of indomethacine hours before sulfur mustard (Ind+HD)

Time	Sulfur Mustard (HD)	HD + Indomethacine
0	0	0
35'	+	0
135'	++	0
3hr	++	+
4hr	+++	++
24 hr	+++	++
48 hr	+++	++
72 hr	+++	++

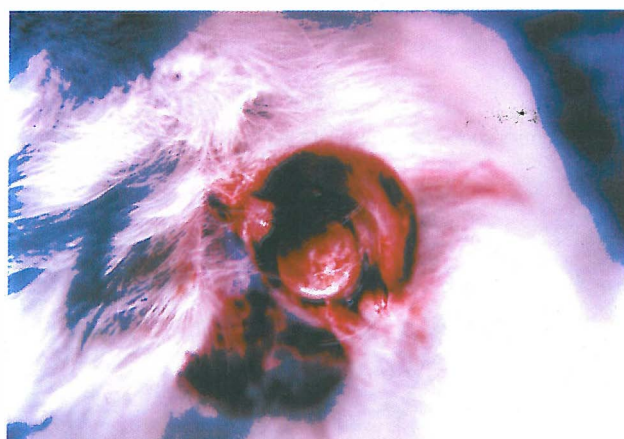


Picture no. 1. Rabbit eye (right) one day after adding HD solution. Note primary hyperemia and lacrimation

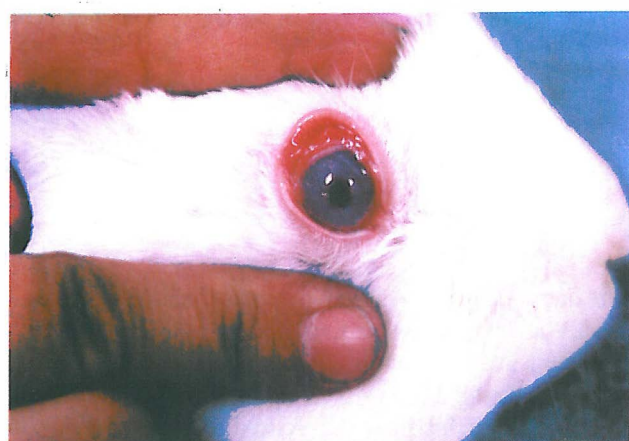however indomethacine could not prevent the primary inflammation. Furthermore, in some animals late in the ex-



Picture no. 2. Rabbit eye (right) one day after administration of HD solution. Note elimination of primary hyperemia and inflammation.

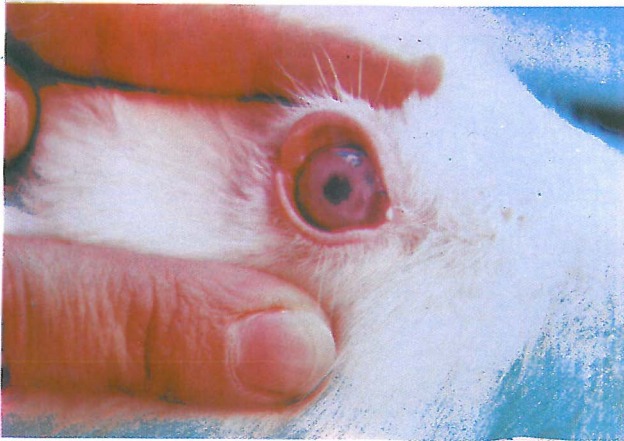

Picture no. 3 Rabbit eye (right) one month after administration of HD solution. Note total degeneration of epithelial cells in cornea and in this case hyperplasia of the substantia propria.

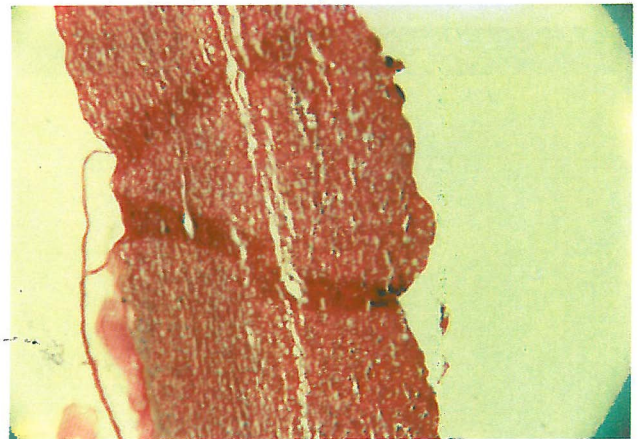


Picture no. 4. Rabbit eye (right) one day after administration of HD+Ind.

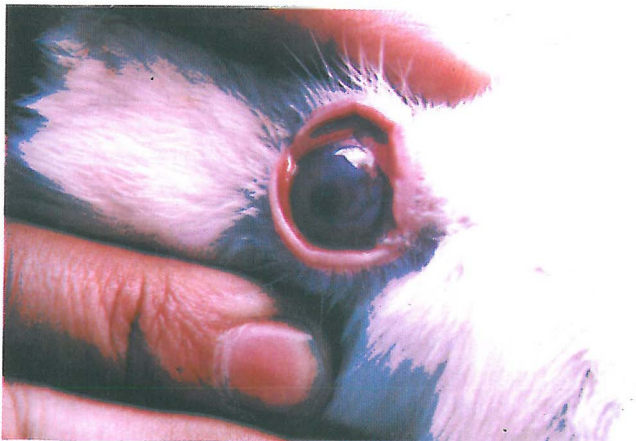periment, a fibrotic area was observed.



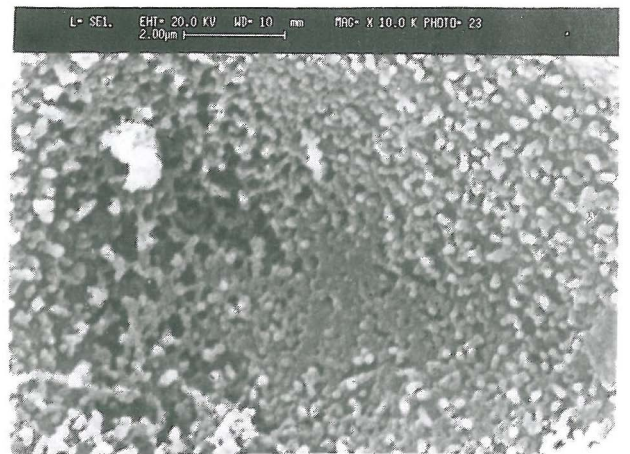
Picture no. 5. Rabbit eye (right) one week after administration of HD+Ind. Note primary hyperemia which was not prevented by indomethacine.



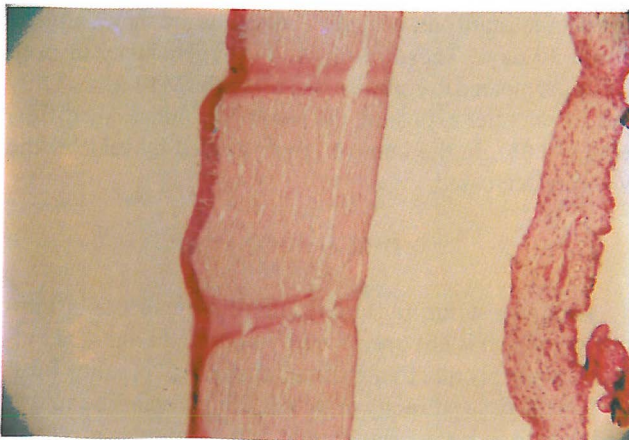
Picture no. 8. Corneal section from rabbit eye 30 days after treated by HD. Note loss of epithelium and total degeneration(H & E, 400×).



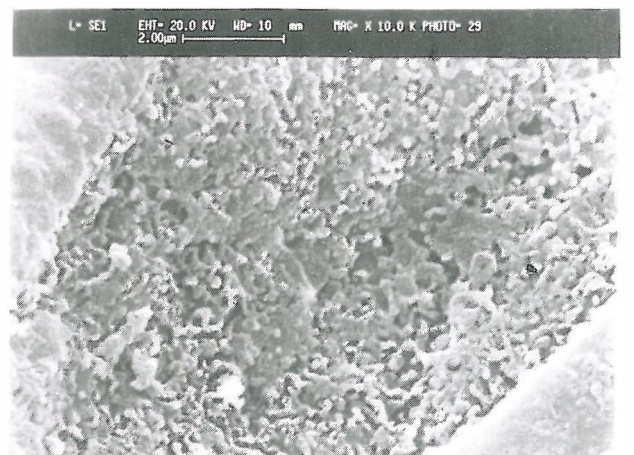
Picture no. 6. Rabbit eye (right) one month after administration of HD+Ind. Note no damage in corneal epithelium. Only some fibroid can be seen.



Picture no. 9. SEM picture from corneal epithelium one day after administration of HD. Note early micropelica & microvillous degeneration.

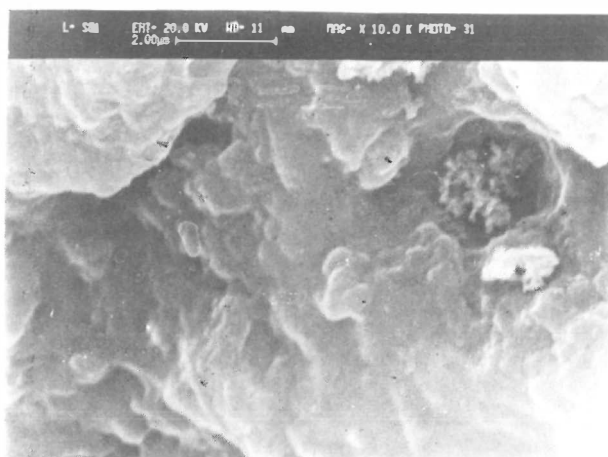


Picture no. 7. Corneal section from rabbit eye after 30 days which was protected by indomethacine. Note normal anatomy and shape (H & E, 400×).

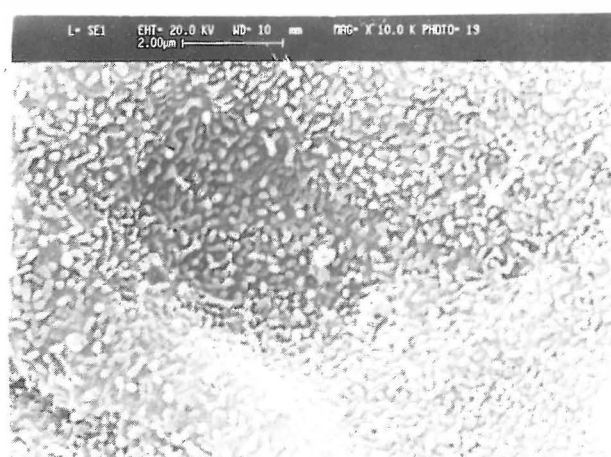


Picture no. 10. SEM picture from corneal epithelium one week after administration of HD. Note total degeneration of micropelica & microvilli and adhesion of epithelium.

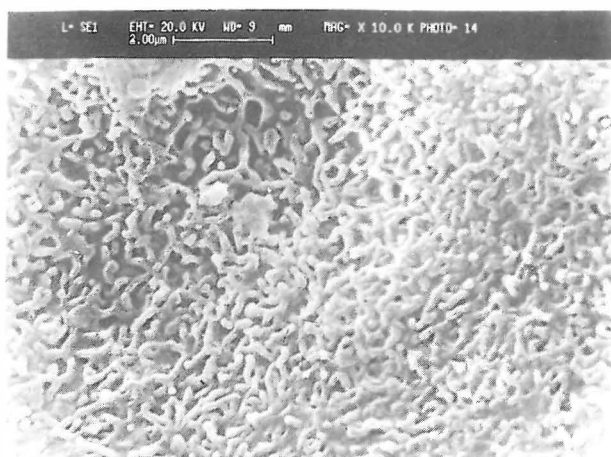
Indomethacine Prevents Ocular Damage



Picture no. 11. SEM picture from corneal epithelium one month after administration of HD. Note total degeneration of epithelium and appearance of substantia propria.



Picture no. 13. SEM picture from corneal epithelium one month after administration of HD + Ind. Note normal micropelica & microvilli.



Picture no. 12. SEM picture from corneal epithelium one week after administration of HD + Ind. Note normal micropelica & microvilli.

Light microscopy

Picture 7 shows a transverse section of the cornea in animals which were pretreated by indomethacine 30 days before the experiment. This picture shows a normal view of cornea from squamous epithelium to the descemet membrane. Picture 8 shows the eye that was treated by mustard after 30 days. These pictures show complete loss of epithelium and necrosis in the substantia propria and infiltration of neutrophils.

Electron microscopy

Pictures 9, 10 and 11 show eyes 1, 7 and 30 days after exposure to mustard respectively. As it is shown in these pictures microvilli are damaged and degenerated. In some

Table II. Viability test using MTT assay (% of control + SFM)

Duration	HD	HD + Ind
One Day	106.75 ± 0.11	112.28 ± 0.1
One Week	128.6 ± 0.12	125.15 ± 0.1
One Month	120.5 ± 2.78	93.82 ± 0.14

areas, microvilli and microplates were cohesive and sinuses were not observed. Pictures 12 and 13 show eyes which were pretreated by indomethacine for 7 and 30 days. No damage in epithelial cells can be seen. Micropleica and microvilli were normal one month after treatment.

MTT assay

Table II shows the results of MTT assay in the three groups which were exposed to indomethacine prior to posure to sulfur mustard and vehicle. The results are shown after 1, 7 and 30 days. These results show hyperactivity in both groups compared to control when using the MTT assay. Only one month after exposure, the result was noticeably different ($p < 0.05$). In the control group treated by vehicle, the viability decreased.

DISCUSSION

Applying sulfur mustard resulted in immediate inflammation, which is not prevented by indomethacine. This effect is probably due to the stimulating effect of sulfur mustard on the tissue directly or by releasing histamine causing an increase in extravascular fluid and a typical hypersensitivity picture. It has been shown that during the first 24 hours exfollowing topical mustard application there are two distinct phases of ocular hypertension.⁴ The first hypertensive

phase is clearly mediated by SP which promotes the ocular response to mustard and the initial breakdown of the blood-aqueous barrier caused by mustard.¹⁰ SP antagonists such as capsaicin but not indomethacine can inhibit this effect.¹¹ This observation suggests that release of SP from sensory nerve terminals following mustard application (nitrogen or sulfur mustard), mediates the first ocular hypertensive response, which appears clinically by inflammation and hyperemia in the eyes. SP induces the production of prostaglandins which in turn produces the second phase of inflammation.¹¹ Unger et al. (1989) reported that prostaglandins have a modulatory role in the irritation response. Theoretically, inhibition of PGs in this stage reduces the late inflammation response that is confirmed by this study. Indomethacine inhibits rise of I.O.P. after mustard exposure. Furthermore, indomethacine reduces basal I.O.P. The reason of this effect is unknown but PGs are probably involved in the maintenance of intraocular pressure. Both light and electron microscopy analysis showed preservation and/or regeneration of corneal epithelium when indomethacine was used before mustard. In the MTT assay, hyperactivity in the control group is the result of mustard's destructive effect on the epithelium, which in this case caused the measurement of the activity in the substantia propria instead of activity of the cornea in normal eyes. In the group treated by indomethacine, the epithelial layer was almost regenerated and so the viability was decreased to about the level of normal eyes. Another pathological change after preservation of the epithelium by indomethacine is existence of a vascular area in the epithelium. It is not clear whether this area is in favor of regeneration of epithelium or is just a pathological aspect of indomethacine therapy. Another question that has remained unanswered is the function of eyes after exposure to mustard following treatment by indomethacine.

ACKNOWLEDGEMENT

The authors would like to acknowledge Tehran University of Medical Sciences for their financial assistance.

REFERENCES

- 1- Belmonte C, Giraldez F: Responses of cat corneal sensory receptors to mechanical and thermal stimulation. *J Physiol Lond* 321: 355-368, 1981.
- 2- Bhatta-Cherjee P: Prostaglandins and inflammatory reactions in the eye. *Meth Find Exp Clin Pharmacol* 2: 17-31, 1980.
- 3- Bito LZ: The effect of experimental uveitis on anterior uveal prostaglandin transport and aqueous humor composition. *Invest Ophthalmol* 13: 59-66, 1974.
- 4- Camras CB, Bito LZ: Nitrogen mustard-induced ocular inflammation in the rabbit eye: the biphasic I.O.P. response and the role of prostaglandins. *ARVO Suppl Invest Ophthalmol Vis Sci* 19 (4): 423-28, 1980.
- 5- Cole DF, Unger WG: Prostaglandins as mediators for the responses of eye to trauma. *Exp Eye Research* 25; 17 (4): 357-68, 1973.
- 6- Eakins KE: Prostaglandin and non-prostaglandin mediated breakdown of the blood-aqueous barrier. *Exp Eye Research* 25: 483-498, 1977.
- 7- Hua XY, Saria A, Gamse R, Theodorsson Norheim E, Brodin E, Lundenberg JM: Capsaicin induced release of multiple tachykinins (substance P, neurokinin A and eledosin-like material) from guinea pig spinal cord and ureter. *Neuroscience* 19: 313-319, 1986.
- 8- Inoue H, Asaka T, Nagata N, Koshihara Y: Mechanism of mustard oil-induced skin inflammation in mice. *Eur J Pharmacol* 333 (2-3): 231-40, 1997.
- 9- Jancso N: Desensitization with capsaicin and related acrylamides as a tool for studying the function of pain receptors. In: Ilim RKL, (ed.), *Pharmacology of Pain, Proceedings of the 3rd International Pharmacological Meeting*. Oxford, New York: Pergamon Press, Vol. 9, pp. 33-35, 1968.
- 10- Jampol LM, Neufeld AH, Sears ML: Pathways for the response of the eye to injury. *Invest Ophthalmol* 14: 184-189, 1975.
- 11- Kebriaee-zadeh A, Mazaheri F, Keshavars M, Akhgari M: The involvement of chemical mediators, substance P and prostaglandins in ophthalmic effects of mustards. *Toxicol Lett Suppl* 1: 150, 1998.
- 12- Mossman T: Rapid colorimetric assay for cellular growth and survival, application to proliferation and cytotoxicity assays. *J Immunol Methods* 65: 55-63, 1983.
- 13- Neufeld AH, Jampol LM, Sears ML: Aspirin prevents the disruption of the blood-aqueous barrier in the rabbit eye. *Nature* 21; 238 (5360) : 158-9, 1972.
- 14- Rozsa AJ, Beuerman RW: Density and organization of free nerve endings in the corneal epithelium of the rabbit. *Pain* 14: 105-120, 1982.
- 15- Tervo K, Tervo T, Ernk L, Ernk O, Cuello AC: Immunoreactivity for substance P in the gasserian ganglion, ophthalmic nerve and anterior segment of the rabbit eye. *Histochem J* 13: 435-443, 1981.
- 16- Unger WG: Mediation of the ocular response to injury and irritation: peptides versus prostaglandins. *Prog Clin Biol Res* 312: 293-328, 1989.
- 17- Uunsitalo H, Krootila K, Palkama A: Calcitonin-gene related peptide (CGRP) immunoreactive sensory nerves in the human and guinea pig uvea and cornea. *Exp Eye Res* 48: 467-475, 1989.
- 18- Yano H, Wershil BK, Arizono N, Galli SJ: Substance P-induced augmentation of cutaneous vascular permeability and granulocyte infiltration in mice is mast cell dependent. *J Clin Invest* 84 (4): 1276-86, 1989.

