

## Case Reports

# PARAGANGLIOMA OF THE FILUM TERMINALE EXTERNUM AND CONCURRENT ARTERIAL HYPERTENSION: A CASE REPORT

H. SABERI, M.D., I. JAHANZAD,\* M.D., Z. HUSSAIN KHAN,\*\* M.D., AND  
N. SAFFARIAN,\*\*\* M.D.

*From the Departments of Neurosurgery, \*Pathology, and \*\*Anesthesiology,  
Imam Khomeini Medical Center, Tehran University of Medical Sciences,  
Tehran, and the \*\*\*Dept. of Cardiology, Baghiyatollah Hospital, Baghiyatollah  
University of Medical Sciences, Tehran, I.R. Iran.*

### ABSTRACT

Paragangliomas are extra-adrenal counterparts of pheochromocytomas and are found at various anatomical sites such as the retroperitoneum, mediastinum, jugular foramen and carotid bifurcation, the latter two forms being coined as chemodectomas.

The vertebral column, especially the lumbar zone, is one of the rarest sites to be involved by paragangliomas. These lesions may have secretory functions and produce symptoms and signs mimicking catecholamine oversecretion as was noticed in our case.

A 60-year-old woman with a sacral mass, backache, and cauda equina syndrome along with arterial hypertension is being presented who had been managed with anti-hypertensive medications. Magnetic resonance imaging revealed involvement of sacral canal and L5 and S1 bodies producing a soft tissue bulge near the right buttock and computed tomography showed a destructive sacral lesion.

Surgery was performed to resect the tumor mass and surprisingly the postoperative blood pressure reached the normal range and henceforth antihypertensive therapy was withheld. Tissue diagnosis of paraganglioma was made on the basis of histopathological examination and ascertained by immunohistochemical study for chromogranin, neuron specific enolase, synaptophysin and S100 protein. One month later the tumor site was subjected to radiation for any remnants following surgery. After two years, the patient was found to be doing well and had been normotensive without medications.

Spinal paragangliomas are treated with total excision and irradiation for residual tumor, if present. The role of immunohistochemistry could not be overemphasized for diagnostic confirmation.

*MJIRI, Vol. 14, No. 4, 393-396, 2001.*

**Keywords:** Paraganglioma, Systemic hypertension, Immunohistochemistry.

### INTRODUCTION

Paraganglia are anatomically dispersed tissue, charac-

**Correspondence:** H. Saberi, M.D., Dept. of Neurosurgery, Imam Khomeini Hospital, Tehran, 14197, I.R. Iran.

## Paranglioma of Filum Terminale Externum

terized by morphological and cytochemically similar neuroendocrine cells, probably derived from the neural crest. Historically the chromaffin reaction had been used to distinguish the chromaffin (mainly sympathetic) and non-chromaffin paraganglia (mainly parasympathetic).

Parasympathetic paragangliomas, also known as chemodectomas, because of their sensory function, usually do not have secretory function (such as carotid body and glomus jugulare tumors).<sup>5</sup>

The most common extra-adrenal sympathetic paraganglia are seen in the retroperitoneum and are frequently associated with organs of Zuckerkandl, the largest collection of paraganglia overlying the aorta at the level of the inferior mesenteric artery.<sup>2,9</sup>

A diversity of clinical spectrum could be produced by paragangliomas within the spine from a well-circumscribed painful lytic process<sup>13</sup> to an indistinct margin malignant lesion compressing the spinal cord.<sup>6,11</sup> Primary spinal paragangliomas involve either the bony elements of the spinal column with variable biological behaviour or the cauda equina and filum terminale.<sup>1,3,4,7,14,15,16</sup> In this study a case of lumbosacral paraganglioma is being presented manifesting as cauda equina syndrome with systemic symptoms of catecholamine oversecretion.

### CASE REPORT

A 60-year-old woman was admitted on March 1996 for low back pain, a sacral mass and sciatica of the right leg. The pain started 3 months prior to admission with a progressive crescendo tempo. The patient had recent weight loss and her blood pressure was 170/110 mmHg while receiving antihypertensive medication.

Neurological examination revealed apprehension, right extensor hallucis longus weakness, great toe hypesthesia and saddle anesthesia. She could recall some episodes of urinary retention and constipation. She underwent computed tomography and magnetic resonance imaging of the lumbosacral area. The sacrum and L5 were involved by a tumor in the sacral canal extending up to L5 and S1 bodies, destroying the laminae and engulfing the thecal sac (Fig. 1,2).

The sustained elevation in the arterial blood pressure was assumed to be essential because no stigma of kidney dysfunction or hormonal problem could be found. Thus with a suspicion of primary malignant spinal tumor, surgery was planned to decompress the cauda equina and resect the lesion. Intravenous sodium nitroprusside 1 µg/kg/min was required to normalize blood pressure before anesthetic induction besides routine premedication. Laminectomy was performed through a right paramedian incision over the lesion. An ill defined, suctionable cherry red tumor was encountered which was resected subtotally because of improperly demarcated margins. Hemorrhage was excessive with an approximate loss of 3000 mL. Postoperatively the pain abated

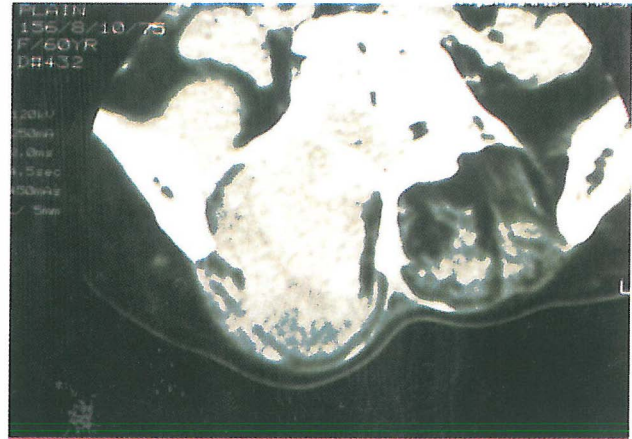

Fig. 1. Axial computed tomogram at L5 level revealing destructive bone lesions, thecal sac compression and a paravertebral mass on the right side with sparse punctate calcification.

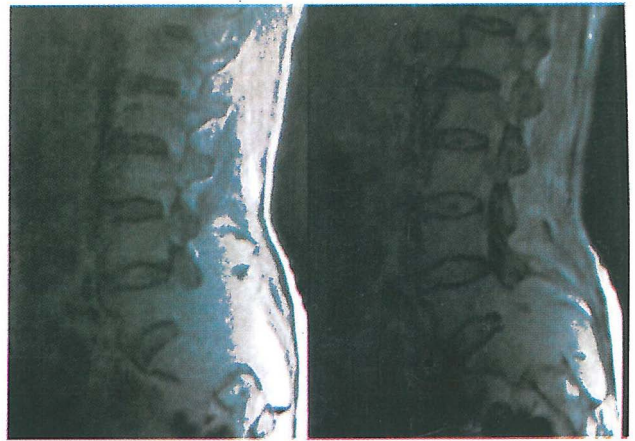


Fig. 2. Sagittal T2-weighted MRI of lumbar spine, depicting an extensive hyperintense lesion involving L5 and S1 posterior elements and caudal extension of its epidural portion.

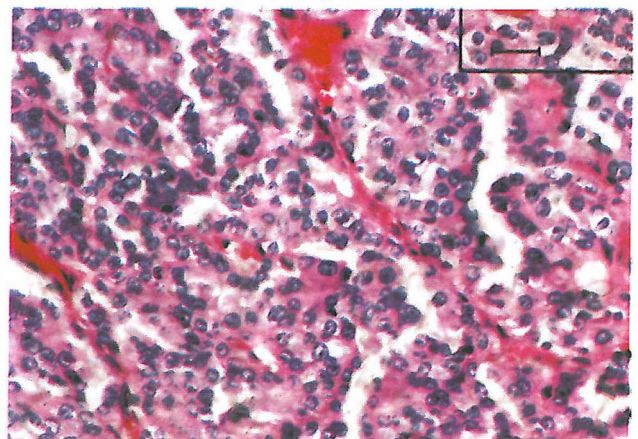
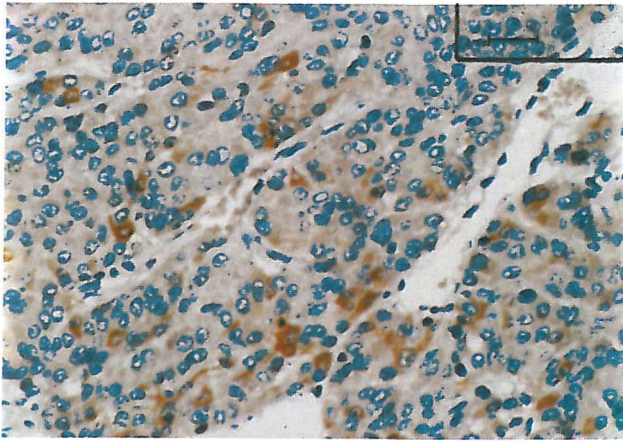
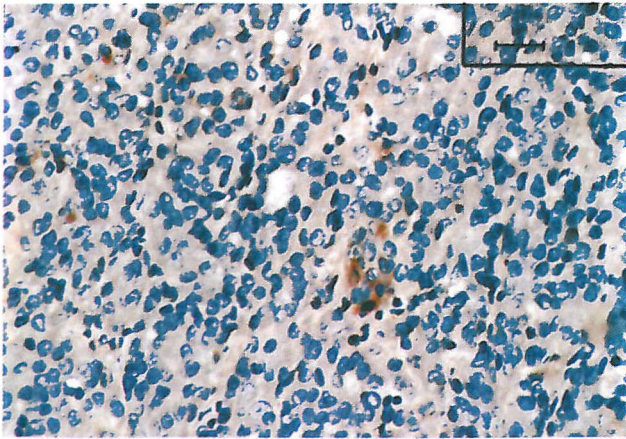


Fig. 3. Hematoxylin & Eosin stain, relative organoid pattern associated with scarce Zellballen-like structures.

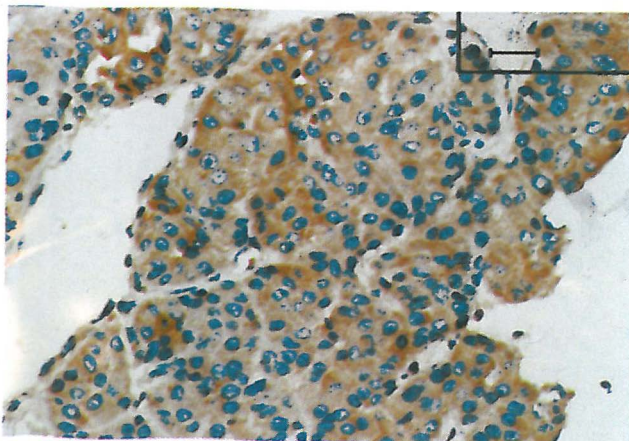
and neurological recovery was evident. Surprisingly blood pressure declined to normal levels. Histopathologically the



**Fig. 4.** Positive immunoreactivity of neoplastic cells for chromogranin.



**Fig. 5.** Diffuse weak and scattered cells moderately positive for synaptophysin.



**Fig. 6.** S-100 protein staining, positive for sustentacular cells.

tumor was reported to be a paraganglioma (Fig. 3) and subsequent immunohistochemical analysis revealed positive immunoreactivity for chromogranin (Fig. 4), synaptophysin

(Fig. 5), neuron specific enolase and S100 protein for sustentacular cells (Fig. 6). which established the diagnosis. Radiation was delivered to the lumbosacral area to eradicate the tumor remnant. Thereafter she did well and 2 years later no evidence of pain or neurological deficit was present.

## DISCUSSION

Paragangliomas are tumors originating from paraganglia distributed in the body as part of the amine precursor uptake and decarboxylation system.<sup>5</sup> Cauda equina involvement has been reported particularly in the filum terminale.<sup>10</sup> Males around 50 years of age are more commonly affected. The tumor is usually intradural extramedullary, but occasionally may occur in the epidural space as was found in our case.<sup>5</sup> Here one can postulate an origination from the extradural portion of the filum terminale (filum terminale externum).

Histological investigations in our case did not reveal any evidence of malignant behavior. It is reported that the biological behavior in extra-adrenal paragangliomas is more aggressive and up to 20%-40% of them are malignant with distant metastases,<sup>6</sup> and lesions in the cauda equina are usually well circumscribed and total resection is possible.<sup>1,5,14</sup>

Preoperative diagnosis can be made with [<sup>131</sup>I] Metaiodobenzyl guanidine ([<sup>131</sup>I] MIBG) uptake by the tumor granules.<sup>12</sup> Histopathologically the tumor has immunoreactivity for S100 protein, chromogranin, neuron specific enolase and synaptophysin.<sup>5</sup> This phenomenon could be reproduced in our case.

Sustained hypertension in our case could be attributed to norepinephrine production. Pheochromocytomas produce either norepinephrine, epinephrine or both which can produce sustained or episodic hypertension respectively, but extra-adrenal paragangliomas produce only norepinephrine;<sup>5</sup> sustained hypertension in our case could be attributed to norepinephrine production.

Malignancy in paragangliomas is not common but recurrence after incomplete excision occurs frequently.<sup>6,8,12</sup> The histologic indicators that may suggest malignancy include extremely large Zellballen<sup>5</sup> made up of pleomorphic cells with mitotic figures and focal necrosis, usually at the epicenter of the Zellballen; these indicators were singularly absent in our case.

Although our case responded to subtotal resection and irradiation, total resection is the optimal therapeutic goal for paragangliomas, but the role of adjuvant therapy still remains controversial. Chemotherapy, radiation and MIBG have been used with variable outcomes, nevertheless in malignant or partially resected tumors their impact is unequivocal.<sup>4,6,11,12</sup> We believe that, although the two entities of essential hypertension and primary spinal paraganglioma could frequently go together, nevertheless a thorough preoperative screening is necessary to elucidate any possibility

## Paranglioma of Filum Terminale Externum

of a secretory paraganglioma. Since the blood pressure returned to its normal range following tumor resection, this secretory paraganglioma was probably the cause of hypertension.

### REFERENCES

1. Ashkenazi E, Onesti ST, Kader A, Liens JF: Paranglioma of the filum terminale: case report and literature review. *J Spinal Disorders* 11 (6): 540-2, 1998.
2. Blasius S, Brinkschmidt C, Poremba C, Terpa HJ, Halm H, Schleef J, Ritter J, Wortler K, Dockhorn-Dworniczak B: Metastatic retroperitoneal paraganglioma in a 16-year-old girl. Case report, molecular, pathological and cytogenetic findings. *Pathol Res Pract* 194 (6): 439-44, 1998.
3. Boker DK, Wassmann H, Solymosi L: Paranglioma of the spinal canal. *Surg Neurol* 19 (5): 41-8, 1983.
4. Bouraoui S, Kchir N, Haouet S, Zammal L, Chatti S, Khaldi M, Zittona MM: Paranglioma of the cauda equina, a propose of a case with review of the literature. *Arch Anat Cytol Pathol* 45 (1): 37-42, 1997.
5. Brodeur GM, Shimada H: Pheochromocytomas and paragangliomas, In: Bigner DD, Mc Lendon RE, Bruner JM, (eds.), *Russel & Rubinstein's Pathology of Tumors of the Nervous System*. 6<sup>th</sup> ed, London: Arnold Press, pp. 535-60, 1998.
6. Broodkey JA, Broodkey JS, Watridge CB: Metastatic paraganglioma causing spinal cord compression. *Spine* 1; 20 (3): 367-72, 1995.
7. Cybulski GR, Nijenson E, Brody BA, Meyer PR Jr, Cohen B: Spinal cord compression from a thoracic paraganglioma. *Neurosurgery* 28 (2): 306-9, 1991.
8. Fitzgerald LF, Cech DA, Goodman JC: Paranglioma of the thoracic spinal cord. *Clin Neurol Neurosurg* 98 (2): 183-5, 1996.
9. Hayes WS, Davidson AJ, Grimley PM, Hartman DS: Extraadrenal retroperitoneal paraganglioma: clinical pathological and CT findings. *American Journal of Roentgenology* 155: 1247-50, 1990.
10. Kamalian N, Abbassioun K, Amirjamshidi A, Shams Shahrabadi M: Paranglioma of the filum terminale internum: report of a case and review of the literature. *Journal of Neurology* 235: 56-9, 1987.
11. Mertens WC, Grignon DJ, Romano W: Malignant paraganglioma with skeletal metastases and spinal cord compression: response and palliation with chemotherapy. *Clin Oncol (R Coll Radiol)* 5 (2): 126-8, 1993.
12. Noorda RJ, Wuisman PI, Kummer AJ, Winters HA, Rauwerda JA, Egeler-Peerdeman SM: Nonfunctioning malignant paraganglioma of the posterior mediastinum with spinal cord compression, a case report. *Spine* 15; 21 (14): 1703-9, 1996.
13. Robinson JC, Kilpatrick SE, Kelly DR Jr: Intraosseous glomus tumor of the spine: case report and review of the literature. *J Neurosurg* 85 (2): 344-7, 1996.
14. Singh RV, Yeh JS, Broome JC: Paranglioma of the cauda equina: a case report and review of the literature. *Clin Neurol Neurosurg* 95 (2): 109-13,
15. Steel TR, Botteril P, Sheely JP: Paranglioma of the cauda equina with associated syringomyelia: case report. *Surg Neurol* 42 (6): 489-93, 1994.
16. Solymosi L, Ferbert A: A case of spinal paraganglioma. *Neuroradiology* 27 (3): 217-9, 1985.