

THE INCIDENCE OF PROSTATIC INTRA-EPITHELIAL NEOPLASIA IN PROSTATIC HYPERPLASIA AND PROSTATIC CARCINOMA

S. TORABI-NEZHAD AND S. MAFTOUN

From the Department of Pathology, Shiraz University of Medical Sciences, Shiraz, I.R. Iran.

ABSTRACT

Prostatic intra-epithelial neoplasia (PIN) is considered a precursor of invasive carcinoma, characterized by proliferation and anaplasia of cells lining prostatic ducts and acini. In this study, we applied the PIN grading system on one-hundred cases of prostatic carcinoma and one-hundred cases of benign prostatic hyperplasia, then compared the results. 74% of prostatic carcinoma and 51% of prostatic hyperplasia cases showed PIN foci. Most of the prostatic carcinomas (61%) showed foci of high-grade PIN including grade II (46%) and grade III (15%). In benign prostatic hyperplasia cases, only PIN grade I (26%) and grade II (25%) were seen.

It is concluded that PIN and invasive adenocarcinoma of prostate are closely associated and the likelihood for coexistence is higher in patients with high grade PIN and especially if other factors such as prostate specific antigen and positive findings on sonography are also considered.

MJIRI, Vol. 14, No. 1, 9-13, 2000

Keywords: Prostate, Prostatic intra-epithelial neoplasia, Prostatic carcinoma, Benign prostatic hyperplasia.

INTRODUCTION

Pre-malignant lesions have been demonstrated to be of great value for many purposes in many organ systems.¹⁶ Pre-malignant changes in the prostate have been recognized for many years. Several investigators have described the histological, biochemical and histochemical similarities between these lesions and prostatic carcinoma.¹ Several descriptive names have been used, including atypical epithelial hyperplasia, atypical glandular hyperplasia, intraductal dysplasia and intra-epithelial neoplasia.¹ To resolve this confusion, a conference was held in 1989 and the term prostatic intra-epithelial neoplasia (PIN) was chosen as the most appropriate term.¹ PIN is classified into two grades, low grade (grade I) and high grade (grade II & III).⁶

In the current study, we have examined the frequency of PIN foci in both prostatic carcinoma and benign prostatic hyperplasia specimens. Our results suggest that PIN is a precursor lesion of prostatic carcinoma, due to the strong association of increasing grades of PIN with invasive carcinoma.

MATERIALS AND METHODS

We retrospectively analyzed two-hundred cases of prostatectomies (open or TUR) between 1990-1997 from the files of surgical pathology laboratories of Shiraz Medical University, including Shahid Faghihi, Nemazi & Shahid Beheshti hospitals.

All tissue had been fixed in 10% neutral buffered formalin for 12-24 hours, serially cut at 3-5 mm intervals, embedded in paraffin & sectioned at 4-5 microns and H&E staining was done.

Half of the cases were diagnosed previously as benign

Correspondence: S. Torabi-Nezhad, M.D., Dept. of Pathology, Shiraz Medical School, Shiraz Univ. of Med. Sciences, Shiraz, I.R. Iran.

prostatic hyperplasia and the other half as prostatic carcinoma. We reviewed all the cases again, Gleason's grading^{11,18} was done on the cases of prostatic carcinoma and then the PIN grading system was applied on all of the cases based on the criteria proposed by Bostwick & Brawer in 1986.⁶ The criteria are based on several characteristics such as architectural features, cytologic features and associated features.

Prostatic intra-epithelial neoplasia is believed to be a pre-malignant lesion and is divided into two main grades: low grade (PIN I) and high grade (PIN II&III).⁶ Low grade prostatic intra-epithelial neoplasia is characterized by irregular focal crowding and multilayering of the epithelium lining the ducts and acini, marked variation in nuclear size, elongated hyper-chromatic nuclei and occasional small nucleoli.^{4,6,9,14,15}

High grade PIN (grade II&III) is considered to be the precursor of most cases of prostatic carcinoma.⁴ The microscopic findings consist of a proliferation of epithelial cells with cytological changes mimicking carcinoma including multiple large nucleoli, more pronounced epithelial cell crowding and stratification plus uniformly enlarged nuclei.^{4,6,9,15}

PIN grade III is similar to grade II except they also have focal basal cell layer discontinuity, cribriform pattern and more frequent large nucleoli.⁴ We also evaluated the association of PIN grades with different Gleason grades.

RESULTS

Foci of intra-epithelial neoplasia (PIN) were identified in 74% of prostatic carcinoma and 51% of benign prostatic hyperplasia specimens (Table I). The distribution of PIN between the two main groups (benign and malignant) are associated with each other ($p < 0.0001$) based on Cross tabulation method, Chi-square test and Mann-Whitney statistical tests. The distribution has statistical significance and is not a random phenomenon.

Most of the prostatic carcinoma specimens (61%) showed foci of high grade PIN (grade II&III). The distribution of PIN foci in prostatic carcinoma was as follows:

Grade I: 13%, Grade II: 46%, Grade III: 15% (Table I, Figs.1,2,3). We couldn't apply PIN grading on 26% of prostatic carcinoma cases due to total replacement of prostatic tissue by carcinoma.

In the benign prostatic hyperplasia specimens, the distribution of PIN grades were as follows:

Grade I: 26%, Grade II: 25%, Grade III: 0% (Table I). The distribution of PIN grades in prostatic carcinoma with relation to different Gleason grades is only a random phenomenon and there is no association between PIN grades and different Gleason grades. This could be due to two main factors:

First, severe inflammation can produce histologic

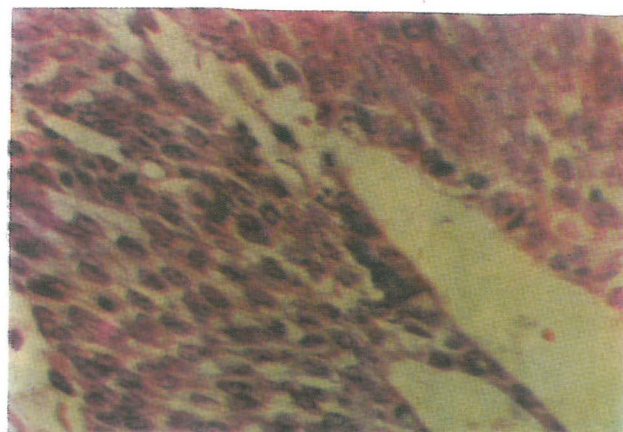


Fig. 1. PIN grade I, mild enlargement of the nuclei, no nucleoli (H&E stain, 400x).

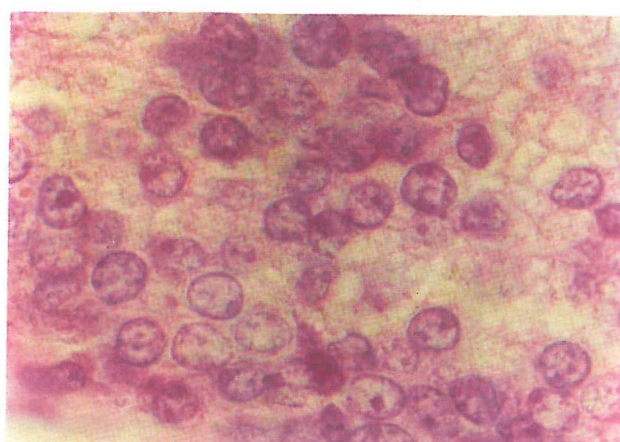


Fig. 2. PIN grade II, more cell crowding, enlarged nuclei, prominent nucleoli (H&E stain, 900x).

Table I. Distribution of PIN grades between benign hyperplasia and prostatic carcinoma.

	Grade 1	Grade 2	Grade 3	No PIN
BPH	26%	25%	0%	49%
PC	13%	46%	15%	26%

BPH: Benign prostatic hyperplasia
PC: Prostatic carcinoma

changes similar to high grade PIN, and inflammation and necrosis are commonly seen in high grades of prostatic carcinoma. Therefore we excluded such cases and didn't apply grading on them.

Second, high grade prostatic carcinoma may totally obliterate the precursor lesions and our study showed that in

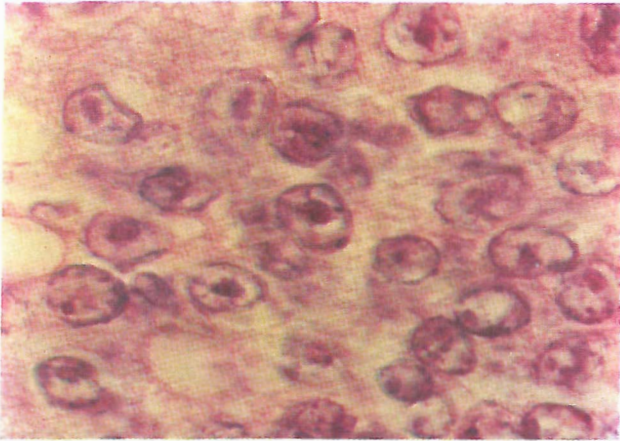


Fig. 3. PIN grade III, markedly enlarged nuclei, frequent large nucleoli (H&E stain, 900x).

Table II. The correlation between PIN grades and Gleason grading in prostatic carcinoma.

	1	2	3	No PIN
I	15.4%	16.5%	7.7%	15.4%
II	7.1%	50%	14.3%	28.6%
III	14.3%	50%	28.6%	14.3%
IV	22.2%	48.1%	14.8%	14.8%
V	8%	32%	16%	44%
Total	13%	46%	15%	26%

most cases of high grade prostatic carcinoma (Gleason grade IV&V) near-total replacement of prostatic tissue with cancer was noted and so no PIN foci were seen.

DISCUSSION

The human prostate gland is a composite organ made up of several glandular and non-glandular components that are tightly fused together within a common capsule.¹³ There are morphological pre-neoplastic candidates within the prostate, neither one excluding a role for the others.¹⁵ Atypical adenomatous hyperplasia (AAH) is predominantly an abnormality of glandular microarchitecture occurring in the transition zone,⁸ whereas in prostatic intra-epithelial neoplasia (PIN) the emphasis is on cytological atypia with a peripheral zone distribution.¹⁵

Prostatic intra-epithelial neoplasia (PIN) is defined as abnormal proliferation of the normal luminal cell layer lining the prostatic ducts and acini with dysplastic changes.^{9,15}

These changes were reported under different names and all indicated atypia or dysplasia in luminal epithelial cells of prostatic ducts and/or acini. Different names were used such as atypical glandular hyperplasia and intraductal dysplasia. The term PIN was introduced in 1987 by McNeal and Bostwick and supported by a workshop in 1989 conducted by the American National Prostatic Cancer Detection Project.¹

The significance of PIN grading was that several researches done in this field revealed a strong correlation between high grade PIN and prostatic carcinoma.^{2,4,7,10,17}

Prostatic intra-epithelial neoplasia was first divided into three different grades by criteria proposed Bostwick in 1987.⁹ In 1989 Bostwick and Brawer divided PIN into two grades, low grade (grade I) versus high grade (grade II&III).⁶ In low grade PIN (grade I), the epithelium lining ducts and acini are heaped up, crowded and irregularly spaced with marked variation in nuclear size. Elongated hyperchromatic nuclei and small nucleoli are also present, but are not prominent. In high grade PIN (grade II&III), the microscopic findings consist of proliferation of epithelial cells with cytologic changes mimicking carcinoma, including nuclear and nucleolar enlargement.

High grade PIN resembles low grade PIN, but nucleomegaly, cell crowding and stratification are more pronounced and nuclear size is less variable because the majority of nuclei are enlarged. The presence of prominent nucleoli, often multiple, is typical of high grade PIN and is of great diagnostic importance.

In less severe high grade PIN (grade II), greater variability in nuclear size is observed. Nucleoli may be single or multiple and are often eccentric and in contact with the chromatin rim.⁵

In PIN grade III all of the cells have large prominent nucleoli similar to invasive carcinoma. They also show a cribriform pattern, chromatin margination and focal basal cell disruption. PIN is spread throughout the prostatic ducts in three different patterns.⁵ In the first pattern it replaces the normal luminal secretory epithelium with preservation of the basal cell layer and basement membrane. In the second pattern, there is direct invasion through the ductal and acinar wall with disruption of the basal layer. In the third pattern, the neoplastic cells invaginate between the basal layer and columnar secretory cell layer.⁵ The association between high grade PIN and prostatic carcinoma are identified by the following observation:¹¹

1- Both high grade PIN and prostatic carcinoma occur more frequently in the peripheral zone of the prostate.

2- Multiple studies have shown that high grade PIN occurs more frequently with carcinoma than benign lesions of the prostate.

3- Increase in size and number of PIN foci are seen in glands with carcinoma compared to glands without it.

4- In the area of PIN foci, there is often the appearance

of adjacent microinvasive carcinoma.

5- Histochemical and immunohistochemical studies show comparable expression of antigens in both lesions.¹

Some of the lesions in the prostate may mimic histologic features of PIN and may be mistaken for it.¹⁵ These include:

1- Primary duct prostatic carcinoma which may resemble the micropapillary form of PIN. In contrast to the dominant peripheral zone location of PIN, it commonly distends the sub-urethral duct. It may retain a microcystic papillary structure but frequently merges with the more typical acinar pattern.

2- Cribriform hyperplasia which is similar to PIN only under low power magnification.

3- Basal cell hyperplasia in which the cells have elongated regular nuclei and small nucleoli.

4- Reactive changes induced by trauma or inflammation which may appear hyperchromatic at low power but lack other nuclear features of PIN.

In the current study, we observed that the frequency of PIN foci were much higher in prostatic carcinoma (74%) than benign prostatic hyperplasia (51%) and our results were similar to others.^{3,9,15} In 1980, research done by Kastendieck on 180 cases showed foci of PIN in 58.9% of prostatic carcinoma in contrast to 30% of benign prostatic hyperplasia specimens.¹² McNeal and Bostwick in 1986 obtained the following results: 82% of prostatic carcinoma and 43% of benign prostatic hyperplasia specimens showed PIN foci.³ In 1989, Helpap demonstrated foci of PIN in 54.7% of prostatic carcinoma in contrast to 25% of such foci in benign prostate specimens.¹²

In 1992, Brawer studied 200 cases and demonstrated PIN foci in 73% of prostatic carcinoma and 32% of benign hyperplasia cases.⁹

All studies to date have shown a correlation between high grade PIN and prostatic carcinoma. In our study also most of the prostatic carcinoma specimens (61%) showed high grade PIN. The distribution was as follows:

Grade I: 13%, Grade II: 46%, Grade III: 15%.

All of the PIN foci in benign prostatic hyperplasia specimens were grade I (26%) and grade II (25%).

In conclusion, the significance of recognizing PIN is based on its strong association with prostatic carcinoma and the higher likelihood for coexistence of high grade PIN with carcinoma.

We recommend that all patients who show high grade PIN on prostatic biopsy be followed very closely with multiple prostate specific antigen (PSA) measurements, sonography and repeat biopsies from both the areas of PIN and other areas of the prostate, because they are more prone to development of prostatic carcinoma in the future than patients without PIN foci.

If foci of high grade PIN are identified in a TURP specimen, additional sectioning is mandatory to rule out the possible coexistence of adjacent microinvasive carcinoma.

It is not clear whether low grade PIN will progress to high grade PIN and whether these changes are truly pre-neoplastic or if there is no relationship to subsequent prostatic carcinoma. Further investigation is needed to optimize treatment of patients with low grade prostatic intra-epithelial neoplasia.

REFERENCES

1. Aboseif S, Shinohara K, Weidner N, et al: The significance of prostatic intra-epithelial neoplasia. *Brit J Urology* 76: 355-359, 1995.
2. Arakawa A, Song S, Scardino PT, et al: High grade prostatic intraepithelial neoplasia in prostate removed following irradiation; failure in the treatment of prostatic adenocarcinoma. *Pathol Res Pract* 191(9): 868-72, 1995.
3. Bostwick DG: Prostatic intraepithelial neoplasia. *Supp to Urology* 34(6): 16-22, 1989.
4. Bostwick DG: Prospective origin of prostatic carcinoma. *Cancer* 78: 33-36, 1996.
5. Bostwick DG, Amin MB, Dundorf P, et al: Architectural pattern of high grade prostatic intraepithelial neoplasia. *Hum Pathol* 24(3): 298-310, 1993.
6. Bostwick DG, Brawer MK: Prostatic intraepithelial neoplasia and early invasion in prostate cancer. *Cancer* 59: 788-794, 1987.
7. Bostwick DG, Pacelli A, Lopez-Beltran A: Molecular biology of prostatic intraepithelial neoplasia. *Prost* 29(2): 117-134, 1996.
8. Bostwick DG, Qian J: Atypical adenomatous hyperplasia of the prostate. *Am J Surg Pathol* 19(5): 506-518, 1995.
9. Brawer MK: Prostatic intraepithelial neoplasia, a premalignant lesion. *Hum Pathol* 23: 242-248, 1992.
10. Crissman JD, Sakr WA, Hussein ME, et al: DNA quantitation of intraepithelial neoplasia and invasive carcinoma of the prostate. *Prostate* 22(2): 155-162, 1993.
11. Epstein J: Pathology of prostatic intraepithelial neoplasia and adenocarcinoma of the prostate: prognostic influence of stage, tumor volume, grade and margin of resection. *Semin Oncology* 21(5): 527-541, 1994.
12. Kasten H, Helpap B: Prostatic dysplasia/atypical hyperplasia. *Supp to Urology* 34(6): 28-42, 1989.
13. McNeal JE: Normal histology of prostate. *Am J Surg Pathol* 12(8): 619-633, 1988.
14. Nagler RB, Petein M, Brawer MK, et al: New relationship between prostatic intraepithelial neoplasia and prostatic carcinoma. *J Cell Biochem Supp* 16H: 26-29, 1992.
15. Parkinson MC: Preneoplastic lesion of the prostate. *Histopathology* 27: 301-311, 1995.
16. Pretlow TG, Nagabhushan M, Pretlow P: Prostatic intraepithelial neoplasia and other changes during promotion and progression of prostatic carcinoma. *Pathol Res Pract* 191(9): 842-849,

- 1995.
17. Raviv G, Janssen T, Zolotta AR, et al: Prostatic intraepithelial neoplasia: influences of clinical and pathological data on detection of prostatic carcinoma. *J Urology* 156: 1050-55, 1995.
- 1996.
18. Rosai J: *Surgical Pathology of Ackerman*, 8th ed., St. Louis: Mosby Co., pp. 1221-1250, 1995.

