

INTRACRANIAL SUPPURATION FOLLOWING NEUROSURGICAL PROCEDURES DUE TO BRUCELLA SPECIES

SEYED ALI F. TABATABAI,* M.D., HOOSHANG SABERI,** M.D.,
AND MASOUD MEHRAZIN, M.D.

*From the Dept. of Neurosurgery, Imam Khomeini Hospital, Tehran University of Medical Sciences,
Tehran, I.R. Iran.*

ABSTRACT

Reported here are two cases of delayed postsurgical brucella abscess within the cranium, treated successfully by reoperation and appropriate medical therapy. Both patients had an occupational exposure to the pathogenic organism. Systemic symptoms of brucellosis became manifest postoperatively in case I and were present in case II long before operation. The diagnosis was confirmed by serology and positive culture. Later an intracranial abscess developed in both cases at the previous operative sites.

Hematogenous spread of bacteria to the locally low resistance host tissue was speculated as the possible mechanism. Successful management was accomplished by reoperation, comprised of local drainage and debridement followed by a combined antibrucella drug regimen for a period of 6 months.

MJIRI, Vol. 14, No. 1, 97-100, 2000

Keywords: Brucellosis, Brain abscess, Local host resistance, Postoperative infection.

INTRODUCTION

Brucellosis, primarily a disease of domesticated animals caused by brucella species,⁷ is frequently transmitted to man in areas where the disease is enzootic, by direct contact, ingestion of contaminated meat and dairy products or inhalation of infectious aerosols.^{3,25,27}

Brucellae are facultative intracellular bacilli capable of evading a number of host defense mechanisms and are able to survive inside phagocytic cells for long periods of time.⁵ Regardless of the entry route, the organisms, not killed by

polymorphonuclears, migrate to regional lymph nodes and then into the bloodstream where they tend to localize in the reticuloendothelial system.

Human brucellosis is a multisystem disease that may present with a host of clinical manifestations.²² Neurobrucellosis most commonly occurs in association with a chronic course of the disease, with a versatile outlook comprising of meningitis, encephalitis, central nervous system (CNS) demyelination, vascular involvement, psychoneuroses, myeloradiculopathy and peripheral neuropathy,^{2,10,15,18} but infrequently as intracranial suppurative complications.^{1,8,11,12,20}

Presented here are two patients with delayed postoperative intracranial abscess formation due to *Brucella melitensis* and *abortus*, both harboring remote replicas of systemic brucellosis.

Although IgG and IgM serum agglutinin titers were not

Corresponding author:

S.A.F. Tabatabai, MD, Dept of Neurosurgery, Imam Khomeini Hospital, Tehran Univ. of Med. Sciences, Tehran 14197, I.R.Iran.

* Associate Professor of Neurosurgery

** Assistant Professor of Neurosurgery.

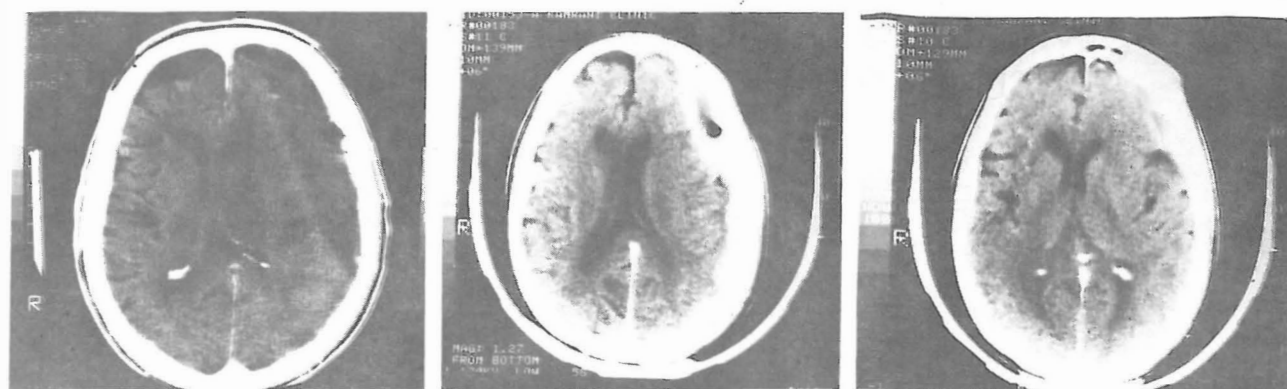

Fig. 1. Preoperative computed tomography of case I revealed left frontoparietal subdural collection (A). Postoperative CT scan the following day (B) and six months later (C).

available separately in our cases to rule out reinfection, isolation of the same organism from the secondary infection site emphasizes a recrudescence pattern, due to curtailed cellular and humoral immunity and the ability of the organism to coexist with the host for a long period.

Case I

A 72 year old villager was admitted to our hospital in December 1992 with complaints of headache for a month and progressive weakness of the right side of the body of a few days' duration. The patient had been operated for chronic subdural hematoma located at the left frontoparietal region in 1990. The postoperative course had been uneventful. Six months later, he developed severe low back pain along with walking inability. A clinical diagnosis of brucellosis, based on a rising serum Wright titer (up to 1/1280) and positive bone marrow culture for *Brucella abortus* was made and the patient treated with sulfamethoxazole/trimethoprim (800/160) mg q8h and tetracycline 500 mg q6h for a period of 6 weeks. On physical examination the patient was emaciated with normal vital signs, bilateral papilledema and moderate right-sided hemiparesis. CT scan revealed a low-density subdural collection at the left frontoparietal area causing midline shift (Fig. 1A). With an impression of chronic subdural hematoma or possibly subdural abscess, a burr hole was applied over the lesion and pus welled out, necessitating a formal frontoparietal craniotomy, evacuating 60 mL of subdural pus.

The pus culture was positive for *Brucella abortus* and the serum agglutination titer was 1/1280. The postoperative course was uneventful and the patient was kept on streptomycin 1 g, sulfamethoxazole/trimethoprim (800/160) mg q8h and rifampin 900 mg daily.

Postoperative CT scan revealed a small subdural collection (Fig. 1B). The patient was discharged on the 10th postoperative day with diminished hemiparesis and a decrement of the agglutination titer to 1/640. Treatment was

maintained for another 6 months on the latter two drugs. The patient has been doing well years after the last operation.

Case II

A 44 year old shepherd was admitted for headache and lethargy in May 1998. One year before admission, he had undergone subtemporal craniotomy for tic douloureux caused by an epidermoid tumor of the petrous apex.

The patient had been treated medically for brucellosis in December 1994 with a positive blood culture for *Brucella melitensis*. He had received three cycles of treatment with sulfamethoxazole/trimethoprim, rifampin and doxycycline, the latter two cycles for treatment of the recurrent episodes.

On physical examination, the patient was drowsy and had right-sided hemiparesis with papilledema. CT scan revealed a low density area with a mild peripheral enhancing lesion at the left temporal lobe adjacent to the previous operative site (Fig. 2A). Blood culture was negative while the serum agglutinin titer rose to 1/640.

The brain abscess was evaluated through a left temporal craniotomy and *Brucella melitensis* was isolated in the pus culture. The patient was discharged three weeks later with a good general condition and no paresis. Medical therapy with a combination of three drugs was maintained for six months. Postoperative serial CT scans revealed gradual diminution of the lesion size and its enhancement (Fig. 2B, C). The patient did well thereafter.

DISCUSSION

Infection following neurosurgical procedures occurs most commonly due to Gram negative enteric rods. Although brucella has been implicated as a rare cause of postoperative pyrexia elsewhere in the literature,^{2,26,28} nevertheless our review provided only one case of postneurosurgical infection (colonization of a VA shunt).¹⁹ CNS involvement, one of

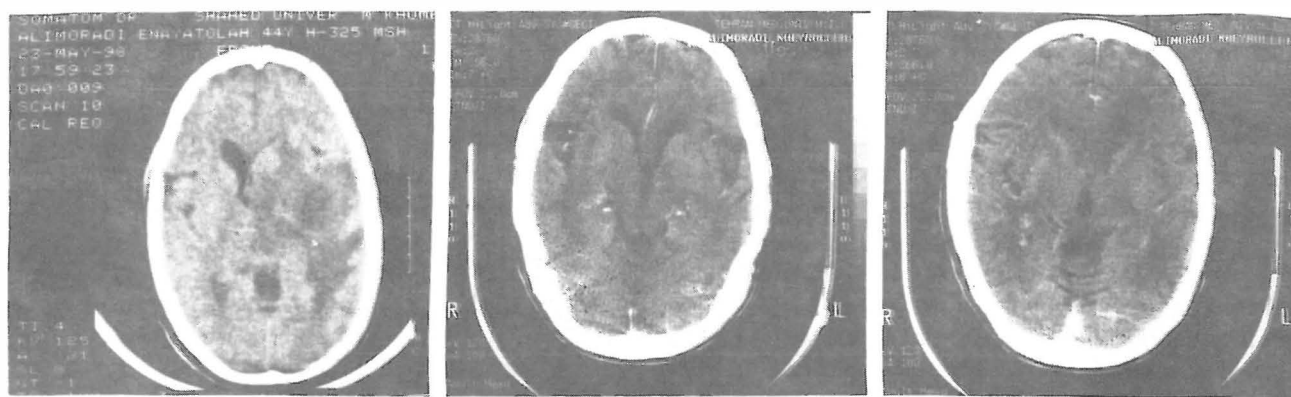


Fig. 2. Preoperative CT scan of case II depicted a left temporal lobe lesion with perifocal edema and minimal enhancement (A). Postoperative computed tomography at one week (B) and 5 months (C).

the most dreaded complications of the disease, occurs in 2-5 percent of patients and usually presents as acute or chronic meningitis which usually follows many weeks after an acute attack of systemic brucellosis not sufficiently or timely treated.^{4,17} Rarely, cases of epidural or brain abscess and cranial osteitis have been reported, most of which arose from the Middle East and the Mediterranean region.^{1,8,11,12,14,20}

Although many authors believe that brucellosis can occur following surgical procedures, trauma or other stressful conditions,^{16,19} however the pathogenesis of this particular form of the disease remains unclear. One can postulate that recrudescence of the disease at the site of surgery could be due to reactivation of bacteria, because the indolent pathogens within the host leukocytes have resisted the immune system and survived for many years.

Factors believed to contribute to the intracellular survival of brucella include: (1) the production of adenine and 5'-guanosine monophosphate, which suppress the myeloperoxidase-H₂O₂ halide system of neutrophils, (2) substances that inhibit phagosome-lysosome fusion in macrophages, (3) enzymes such as superoxide dismutase that defend against oxidative destruction.^{5,9,23}

Although the mechanism by which surgery can affect the biological behavior of pathogens is not clear, however areas of compromised blood supply and immune system disturbance provide a favorable medium for bacterial implantation and regrowth.

Postoperative brucellosis most commonly involves prosthetic heart valves, but total knee prostheses involvement have also been reported.¹³ Among various neoplasms, brucella shows an affinity to infect inclusion tumors. At least two cases of intramedullary and ovarian dermoid cysts secondarily infected by the organism have been reported^{6,24} and our case II could be the 3rd one in the literature.

Association between brucella meningitis and trauma has been reported in one case elsewhere¹⁶ but our case I had not suffered a major trauma, so surgery per se could be more

pertinent as the predisposing factor.

Finally we conclude that asymptomatic patients with a history of systemic brucellosis and sustained elevation of serum IgG levels deserve special attention regarding the possibility of recrudescence disease, so proper preoperative prophylaxis and completion of treatment appear to be necessary before they undergo major cranial or systemic surgery.

REFERENCES

1. Ayala-Gaytan JJ, Ortegón-Baqueiro H, de la Maza M: *Brucella melitensis* cerebellar abscess. J Infect Dis 160(4): 730-2, 1989.
2. Bahemuka M, Shamena AR, Panayiotopoulos CP, et al: Neurological syndromes of brucellosis. J Neurology Neurosurg Psychiatry 51: 1017-21, 1988.
3. Benjamin B, Annobil SH: Childhood brucellosis in southwestern Saudi Arabia: a 5-year experience. J Trop Pediatr 38: 167-71, 1992.
4. Bouza E, Garcia de la Torre M, Parra F, et al: Brucellar meningitis. Rev Infect Dis 15: 582-90, 1992.
5. Canning PC, Roth JA, Dayoe BL: Release of 5' guanosine monophosphate and adenine by *Brucella abortus* and their role in the intracellular survival of the bacteria. J Infect Dis 154: 464-70, 1986.
6. Cokca F, Meco O, Arasil E, Unlu A: An intramedullary dermoid cyst abscess due to *Brucella abortus* biotype 3 at T₁₁-L₂ spinal levels. Infection 22(5): 359-60, 1994.
7. Corbel MJ: Epidemiology and prevalence worldwide. In: Young EJ, Corbel MJ, (eds.), Brucellosis: Clinical and Laboratory aspects. 2nd ed., Boca Raton, FL: CRC Press, pp. 25-40, 1989.
8. al-Eissa YA: Unusual suppurative complications of brucellosis in children. Acta Paediatr 82(11): 987-92, 1993.
9. Frenchik PJ, Markham RJF, Cochrane AH: Inhibition of phagosome-lysosome fusion in macrophages by soluble extracts of virulent *Brucella abortus*. Am J Vet Res 46: 332-5, 1985.
10. Guerreiro CA, Scaff M, Callegaro D, Facure NO, Dianin VM:

- Neurobrucellosis; report of 3 cases. *Arq Neuropsiquiatr* 39(2): 203-13, 1981.
11. Guvenc H, Kocabay K, Okten A, Bektos S: Brucellosis in a child complicated with multiple brain abscesses. *Scand J Infect Dis* 21 (3): 333-6, 1989.
12. Kalelioglu M, Ceylan S, Koksali I, Kuzeyli K, Akturk F: Brain abscess caused by *Brucella abortus* and *Staphylococcus aureus* in a child. *Infection* 18 (6): 386-7, 1990.
13. Malizos KN, Makris CA, Soucacos PN: Total knee arthroplasties infected by *Brucella melitensis*; a case report. *Am J Orthop* 26(4): 283-5, 1997.
14. Marandian MH, Soltanabadi A, Sabouri-Deilamy M, Yalda A, Shoukouhi JJ: Cranial osteitis in two 7 and 8-year-old brothers with associated chronic cerebral brucellosis in one brother. *Ann Radiol (Paris)* 29 (6): 545-8, 1986.
15. McLean DR, Russel N, Khan MY: Neurobrucellosis: clinical and therapeutic features. *Clin Infect Dis* 15: 582-90, 1992.
16. Michowicz SD, Wald U, Shapiro M: *Brucella melitensis* meningitis following head trauma. *Infection* 15 (2): 130-1, 1987.
17. Mousa ARM, Koshy TS, Araj GF, et al: Brucella meningitis: presentation, diagnosis and treatment-- a prospective study of ten cases. *Q J Med* 60: 873-85, 1986.
18. Povar J, Aguirre JM, Arazo P, Franco JM, Alvarez G, Ara JR, Lomba E: Brucellosis with nervous system involvement. *An Med Interna* 8 (8): 387-90, 1991.
19. Puri P, Harvey TW: Colonisation of ventriculoatrial shunt with *Brucella abortus*. *Br Med J (Clin Res Ed)* 282 (6278): 1754-5, 1981.
20. Santini C, Baiocchi P, Berardelli A, Venditti M, Serra P: A case of brain abscess due to *Brucella melitensis*. *Clin Infect Disease* 19 (5): 977-8, 1994.
21. Sharzer LA: Brucellosis: an unusual cause of postoperative fever. *Arch Surg* 107 (1): 112, 1973.
22. Solera J, Martinez-Alfaro E, Espinosa A: Recognition and optimum treatment of brucellosis. *Drugs* 53 (2): 245-56, 1997.
23. Tatum FM, Detilleux PG, Sacks JM, et al: Construction of Cu-Zn superoxide dismutase deletion mutants of *Brucella abortus*; analysis of survival *in vitro* in epithelial and phagocytic cells and *in vivo* in mice. *Infect Immun* 60: 2863-9, 1992.
24. Uwaydah M, Khalil A, Shamsuddine N, Matar F, Araj GF: Brucella-infected ovarian dermoid cyst causing initial treatment failure in a patient with acute brucellosis. *Infection* 26 (2): 131-2, 1998.
25. Young EJ: Human brucellosis. *Rev Infect Dis* 5: 321-42, 1983.
26. Young EJ: The problem patient. Post-op fever in a bounty hunter. *Hosp Prac* 15 (7): 103-4, 1980.
27. Young EJ, Suvannoparrat U: Brucellosis outbreak attributed to ingestion of unpasteurized goat cheese. *Arch Intern Med* 135: 240-3, 1975.
28. Zamora Gomez M, Sanchez Cordero N, Munoz Gonzalez L, Esteban Calro JC, Burgueros Valero B, Moreno Granados F: Fever of unknown etiology during postoperative period following extracorporeal heart surgery. *An Esp Pediatr* 35 (6): 427-8, 1991.