

## Proximal junctional kyphosis in adolescent idiopathic scoliosis following segmental posterior spinal instrumentation and fusion; minimum 2 years follow-up

Hamid Behtash, MD.<sup>1</sup>, Ebrahim Ameri, MD.<sup>2</sup>, Bahram Mobini, MD.<sup>3</sup>, Hossein Vahid Tari, MD.<sup>4</sup>, Hassan Ghandhari, MD.<sup>5</sup>, Mohammad Khaki Nahad, MD.<sup>6</sup>

*Department of Surgery, Shafa Yahyaiian Hospital, Iran University of Medical Science, Tehran, Iran.*

### Abstract

**Background:** To evaluate proximal junctional segment changes in Adolescent Idiopathic Scoliosis (AIS) the posterior spinal fusion and also instrumentation also and finding of probable risk factors, were all considered in this study.

**Methods:** We retrospectively reviewed radiographs of 121 consecutive patients who underwent posterior spinal fusion for AIS from T3 or below, with a mean follow-up of 32.8 months (range, 24-83). All coronal and sagittal measurements including the proximal junctional kyphosis (PJK) angle recorded on standing anteroposterior and lateral radiographs preoperative, early postoperative and on follow-up radiographs. The data were analyzed using the Spss 10.0 software. Dependent (paired) samples student t-test was used for analysis between the groups

**Results:** There was PJK angle above normal for the same junctional segment preoperatively in 13 patients (10.7%) and the incidence of the PJK postoperatively was 7.4% (9 patients, 7 female and 2 male), all detected until 2 years postoperation. The mean increase in the PJK angle from pre-operation until 6 weeks postoperation was 5.9° (range, 0-13°) (P=0.02) and until 2 years post operation was 14.3° (range, 2-16°) (p=0.000). The mean proximal junctional angle increased 1.6° until 2 years postoperation in non-PJK group (n=112).

**Conclusion:** The prevalence of Proximal Junctional Kyphosis was low and a silent radiographic problem. In some cases is preventable with perfect pre-operative planning. There is no specific demographic or radiographic variables or instrumentation types associated with developing PJK.

**Keywords:** adolescent idiopathic scoliosis, posterior spinal fusion, proximal junctional kyphosis.

### Introduction

The operative goal of surgery in Adolescent Idiopathic Scoliosis (AIS) was to prevent progression while providing optimal coronal and sagittal alignment. The Proximal Junctional Kyphosis (PJK) has been seen after insertion of Harrington rods and with the multi-hook sys-

tems but The effect of it on clinical symptoms and patient outcomes is unknown [1-5]. Rhee et al [2] reported PJK in 35% of patients treated with posterior instrumented fusion and postulated that interrupting the posterior tension band and/ or the use of compression forces through claw hook constructs at the upper instrumented vertebra (UIV) may lead to a PJK. It

1-3. Associate Professor of Orthopedic Surgery, Iran university of Medical Sciences.

4&5. Assistant Professor of Orthopedic Surgery, Iran university of Medical Sciences.

6. **Corresponding author**, Spine Surgery fellow, Shafa Yahyaiian Hospital, Iran university of Medical Sciences, Tehran, Iran. E-mail: khakinahad\_m@yahoo.com, Tel: 09123862631.

is possible that in state of imbalance in spine alignment, spinal column spontaneously corrects its balance with compensation from mobile segments, and where there is short segment fusion, and compensation may be retained from multiple segments not just from junctional site [6-12].

The purpose of this study was to determine the incidence of the PJK following posterior spinal instrumentation and fusion in AIS and evaluate multiple demographic and radiographic variables as a probable risk factors for this problem with attention to variations in curve types and implants which used.

### Methods

We reviewed retrospectively clinical charts and radiographs of 121 consecutive patients who underwent posterior spinal instrumentation and fusion (PSF) for Adolescent Idiopathic Scoliosis not extending above T3 with a minimum 2 year follow-up (mean 32.8 months, range 24-82 months). All operations were performed by the senior author at a single university center between 1993 and 2005. We excluded device failures, revision cases and if complete radiographs were not available. There were 90 female and 31 male patients, the average age at time of surgery was 15.6 years (range, 11-20), and average number of fused vertebra was 10.5 (range, 6-14).

According to the surgical classification of AIS by Lenke et al system, [13] the number of patients were: 72 for type 1 (59.5%), 5 for type 2 (4.1%), 15 for type 3 (12.3%), 4 for type 4 (3.3%), 21 for type 5 (17.3%) and 4 for type 6 (3.3%). Fifty six patients had a lumbar A modifier, 20 had a lumbar B and 45 with a lumbar C modifier. A total of 100 patients had a normal thoracic kyphosis sagittal modifier (T5-T12, +10 to +40°), 17 had a thoracic hyperkyphosis sagittal modifier (>40°) and 4 had a hypokyphosis sagittal modifier (<10°). Four patients had a thoracoplasty.

Radiographic measurements were made on

standing anteroposterior and lateral preoperative, early postoperative, 2 years later and at the latest follow-up, including all coronal (PT, proximal thoracic, MT, main thoracic, TL/L, thoracolumbar/ lumbar) and sagittal parameters (T2-T5, T5-T12, T10-L2, T12-S1) with PJK angle that defined as angle between the inferior endplate of the uppermost instrumented vertebra (UIV) to the superior endplate of two vertebra proximal were measured using Cobb's method.

Abnormal PJK was defined by two criteria: the PJK angle  $10^\circ$  and at least  $10^\circ$  more than preoperative as described by Glattes et al [6]. Global coronal balance was measured as the distance between the C7 plumb line and the central sacral vertebral line (CSVL) and global sagittal balance was measured as the distance from the C7 plumb line to the vertical line from the posterior superior of S1 vertebral body (SSVL). The patients were then classified into two groups based on the presence or absence of PJK during years of follow-up after operation.

### Statistical analysis

The data were analyzed using the spss 10.0 software. Dependent (paired) samples student t-test was used for analysis between the groups, and a p value of <0.05 was considered significant.

### Results

The PJK developed in 9 of 121 patients (7.4%) classified as the PJK group, (2 male and 7, female) until 2 years postoperation and after 2 years there was no increase in proximal junctional angle in this group. The average preoperative proximal junctional angle in the PJK group was  $5.1^\circ$  (range, 0- $10^\circ$ ) increased to  $11^\circ$  (range, 2- $18^\circ$ ), (p=0.02) until 6 weeks postoperation and reached  $19.4^\circ$  (range, 12- $28^\circ$ ), (p=0.000) until 2 years postoperation, and then remained constant until final follow-up. In non PJK group the average proximal junctional angle pre-operatively was  $5.1^\circ$  (range, 0- $20^\circ$ ) in-

creased to  $6^\circ$  until 6 weeks postoperation and reached  $6.7^\circ$  (range,  $0-20^\circ$ ) until 2 years postoperation.

The preoperative proximal junctional angle was abnormal in one case of PJK group (was  $10^\circ$ ) and for non PJK group was abnormal in 12 (10.7%) patients (mean,  $13.4^\circ$ , range,  $10-20^\circ$ ). For these 13 cases the proximal fusion level was T7 or below in 8 patients and T6 to T4 in 5 patients, and the angle of proximal junctional kyphosis in these cases decreased to mean of  $13^\circ$  (range,  $4-20^\circ$ ) at 6 weeks postoperation and reached  $14.3^\circ$  (range,  $7-20^\circ$ ) at 2 years postoperation. The proximal junctional angle from the mean pre-operative of  $5\pm 3.5^\circ$  (range,  $0-20^\circ$ ) in overall reached  $7.6\pm 5^\circ$  (range,  $0-28^\circ$ ) until 2-years follow-up. The preoperative and postoperative sagittal and coronal Cobb angles (including all minor and major lateral curves) for two groups are shown in Table 1.

The incidence of PJK at 2-years postoperative, according to the preoperative sagittal thoracic Cobb angle was 6.2% (2 cases) for hyperkyphosis (if T5-T12  $>40^\circ$ ) and 8.2% (7 cases) for normokyphosis (if T5-T12 between 10 and 40 degrees). From 9 cases with PJK, 3 underwent anterior spinal release in addition to posterior spinal instrumentation and fusion. Six were lumbar modifier C, 2 A and 1 B. Only one case in PJK group underwent thoracoplasty and the mean age for both groups was the same,  $15.6\pm 2.1$  years. The clinical characteristics, implants, type of curves and proximal fusion levels are shown in Table 2.

Coronal decompensation in the PJK group improved from the mean of  $20\pm 12$  mm (range,  $0-40$ ) pre-operatively to  $7\pm 6$  mm (range,  $0-20$ ), ( $p=0.000$ ) at 2 years post operation and in the non PJK group from  $17\pm 13$  mm (range,  $0-50$ ) pre-operatively to  $6\pm 6$  mm (range,  $0-30$ ), ( $p=0.000$ ) at 2 years postoperation. The apical vertebral translation (AVT) at 2-years post operation in both groups significantly improved ( $p=0.000$ ). The sagittal balance in both groups changed on average, 8 mm

to anterior at 2-years follow-up and the difference was not significant between two groups. The coronal and sagittal balance measures are shown in Table 3.

Fifty-four patients with rigid curves had anterior spinal release in addition to posterior instrumented fusion. The preoperative mean coronal Cobb angle of Proximal thoracic curve was  $20\pm 13$  degrees, (range,  $0-50^\circ$ ), of main thoracic curve was  $61\pm 25$  degrees ( $0-132^\circ$ ) and of thoracolumbar/lumbar curve  $38\pm 21$  degrees ( $0-96^\circ$ ). In preoperative bending films, PT curve was  $9\pm 9$  degrees (range,  $0-32^\circ$ ), MT curve was  $36\pm 21$  (range,  $0-90^\circ$ ) and TL/L curve  $16\pm 14$  (range,  $0-58^\circ$ ).

The mean preoperative sagittal angles of (T2 to T5, T5 to T12, T10 to L2 and T12 to S1) in overall (121 patients) were in order ( $6.7^\circ$ ,  $34^\circ$ ,  $6^\circ$  and  $-48^\circ$ ) and order for these values at 2-years postoperative ( $9^\circ$ ,  $30^\circ$ ,  $3.8^\circ$  and  $-43^\circ$ ) that resulted in 4 degrees decrease in thoracic kyphosis of T5-T12 and 5 degrees decrease in lumbar lordosis. For the 121 PSF cases, 9 major PT was present curves with the average preoperative angle of  $40.2^\circ$  (range,  $33-50^\circ$ ), decreasing to  $24.2^\circ$  (range,  $18-36^\circ$ ) ( $p=0.000$ ) at 2-years follow-up (40% correction), 106 major MT curves with mean preoperative of  $79.5^\circ$  (range,  $40-132^\circ$ ), decreasing to  $33.2^\circ$  (range,  $9-89^\circ$ ) ( $p=0.000$ ) at 2-years follow-up (58% correction) and 52 major TL/L curves with mean preoperative of  $54.1^\circ$  (range,  $40-96^\circ$ ), decreasing to  $23.9^\circ$  (range,  $10-58^\circ$ ) ( $p=0.000$ ) at 2-years follow-up (55.5% correction). There was no significant changes in Cobb angle of these curves after 2 years. Figure 1, is shown the PJK with posterior instrumentation for Lenke type 5CN, despite of long fusion proximal to the apex of the thoracic area.

There was no significant association between the possible risk factors including, demographic characteristics, Lenke classification (Lumbar and sagittal modifiers), proximal instrumented vertebra, additional ASF, thoracoplasty, fusion length, preoperative and postoperative sagittal

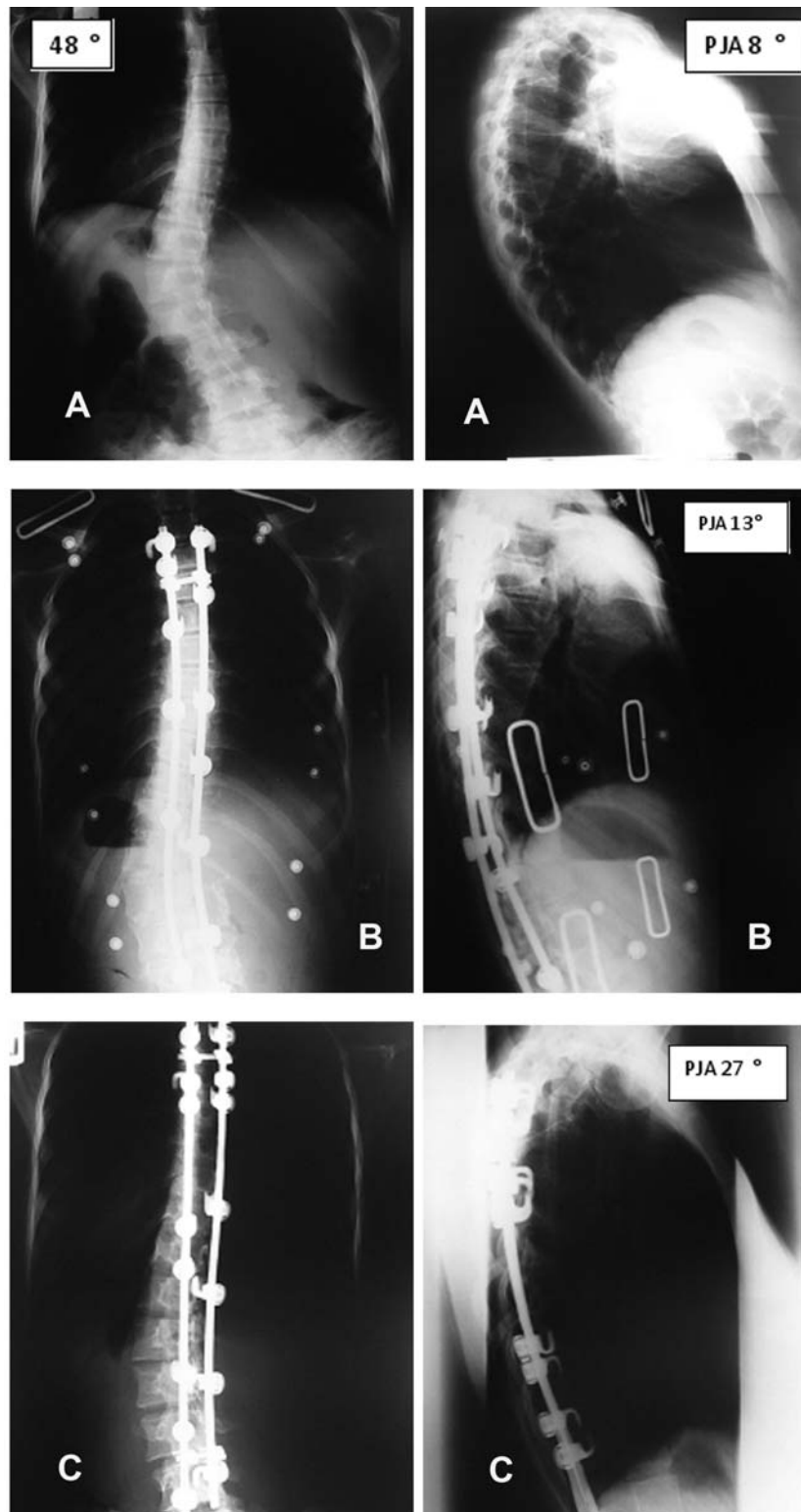


Figure 1. A 17-year-old woman (Lenke type 5CN) was fused with posterior segmental spinal hook instrumentation (T4-L4). A, The major coronal Cobb angle was  $48^{\circ}$ . The sagittal Cobb angle between T5 and T12 was  $40^{\circ}$  and that of proximal junction from T2-T4 was  $8^{\circ}$ . B, six weeks post operation, major Cobb angle  $20^{\circ}$ , the sagittal Cobb angle of T5-T12  $20^{\circ}$  and the proximal junctional angle  $3^{\circ}$ . C, Two years post-operation, the major Cobb angle progressed to  $25^{\circ}$  and the proximal junctional angle to  $27^{\circ}$ .

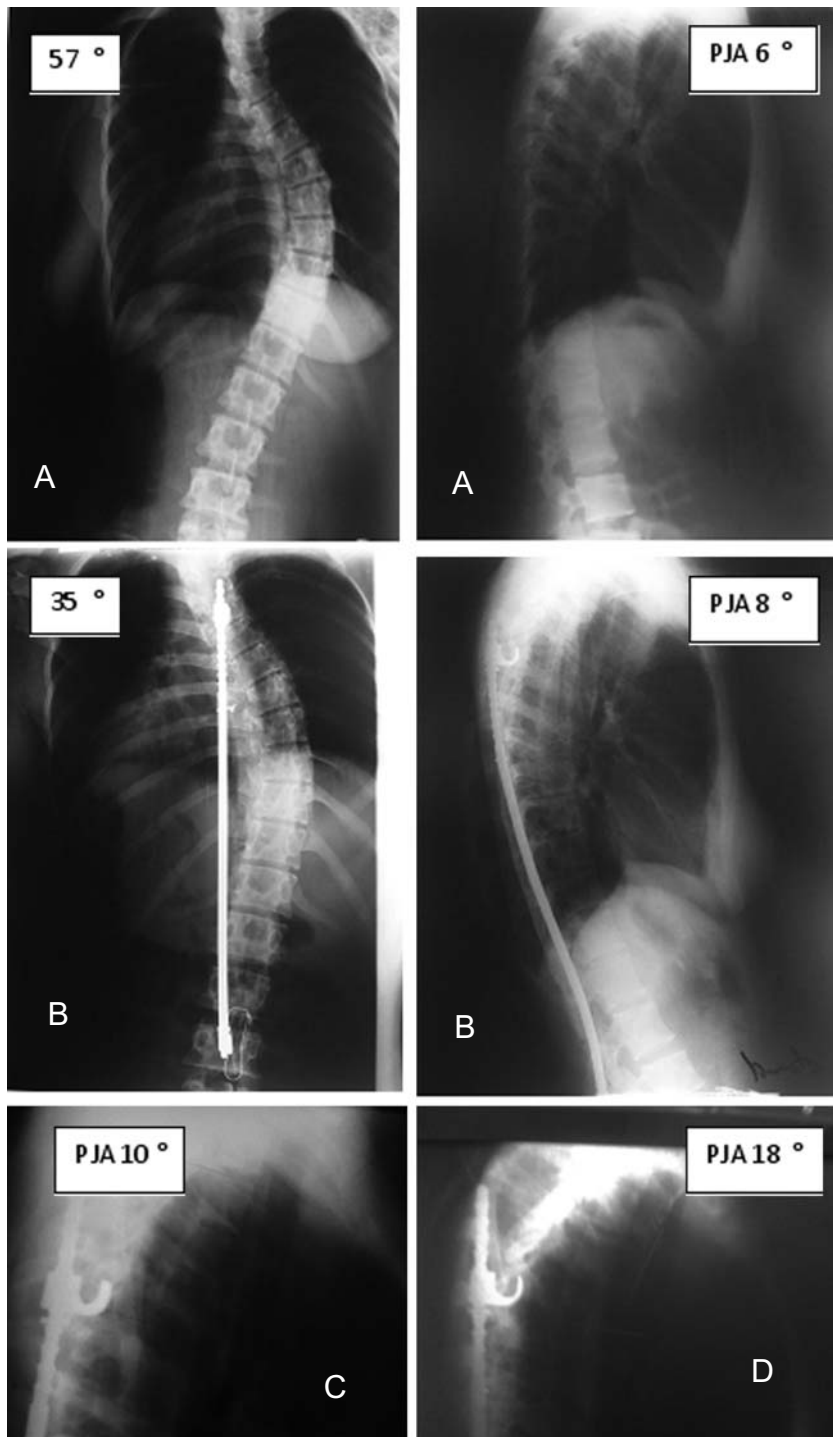


Figure 2. A-D. A 16-year-old woman (Lenke type 1AN) was fused with Harrington distraction Rod (T5-L2). A, The major coronal cobb angle was 57°, proximal junctional angle(PJA) from T3-T5 was 6°. B, 4 weeks post-operation ,major cobb angle was 35 °and the PJA was 8°. C, 1 year post-operation , the PJA was 10°. D,At 2 years post-operation , the PJA progressed to 18°.

Curve type	With PJK(n=9)			No PJK(n=112)			P value
	Pre op	Post op(at 2- year)	P value	Pre op	Post op(at 2-year)	P value	
PJ A®	5.1±3.5(0 to 10)	19.4±5.7(12 - 28)	0.000	5.1±3.6(0 to 20)	6.7±4(0 to 20)	0.00	0.000
T2-T5	6.6±3(2 to 10)	17±9(8 to 30)	0.008	6.7±3.5(0 to 22)	8.3±3.5(0 to 18)	0.00	0.024
T5-T12	39±15(24to 68)	34±12(17 to 50)	0.41	34±15(0 to 80)	30±11(5 to 63)	0.00	0.29
T10-L2	6.9±11(0 to 32)	4±11(-8 to 20)	0.47	6±9(-16 to 32)	3.8±9(-14 to 32)	0.002	0.87
T12-S1	-50±14(-75to-35)	-47±12(-64to-31)	0.29	-48±10(-80to-20)	-42±8(-66to-21)	0.00	0.29
PT	14±17(0 to 40)	11±14(0 to 30)	0.35	21±13(0 to 30)	10±12(0 to 50)	0.000	0.08
MT	40±32(0 to 92)	22±23(0 to 60)	0.006	63±24(0 to 132)	32±17(0 to 89)	0.000	0.17
TL/L	47.6±20(0 to 80)	21±11(0 to 38)	0.001	37±17(0 to 96)	16±13(0 to 58)	0.000	0.3

Table 1. pre and postoperative coronal and sagittal plane curves angles in PJK and non-PJK groups. Mean ± standard Deviation (range in bracket). p\*(Data are analyzed using independent t test). PJA® (proximal junctional angle).

kyphosis of T5-T12 (p=0.61) and of T10-L2 (p=0.27) with increased proximal junctional kyphosis. No patient had additional surgery related to increased proximal junctional kyphosis. Figure 2, showed PJK following posterior fusion with Harrington device.

### Discussion

In this retrospective radiographic analysis of PJK angle, some of the possible causes of this problem were studied, and prevalence of the problem was determined. The prevalence of PJK following 5 different posterior instrumentation used in heterogeneous cases was less

Risk Factor	Total Patients (n=121)	PJK Patients (n=9)	P value
Pre op thoracic cobb angle (T5-T12)			
<10°	4 (3.3%)	0	0.29
10°-40	85(70.2%)	7(77.8%)	
>40°	32(26.4%)	2(22.2%)	
Instrumentation			0.18
Multihook	89(73.5%)	6(66.6%)	
Harrington	20(16.5%)	1(11.1%)	
Harrington+SLW•	7 (5.8%)	1(11.1%)	
All screw	2 (1.6%)	1(11.1%)	
Hybrid	3 (2.5%)	0	
Gender			0.8
Male	31 (25.6%)	2(22.2%)	
Female	90 (74.4%)	7(77.8%)	
Uppermost instrumented Vertebra			0.08
T3	39 (32.2%)	3(33.3%)	
T4	46 (38%)	2(22.2%)	
T5	15 (12.3%)	1(11.1%)	
T6	12 (9.9%)	1(11.1%)	
T7	2 (1.6%)	2(22.2%)	
T8 and below	7 (5.7%)	0	
Curve type(Lenke)			0.067
1	72 (59.5%)	3(33.3%)	
2	5 (4.1%)	2(22.2%)	
3	15 (12.4%)	3(33.3%)	
4	4 (3.3%)	1(11.1%)	
5	21 (17.3%)	0	
6	4 (3.3%)	0	

Table 2. Radiographic, Implants and Demographic parameters of all patients versus the PJK patients.

	With PJK(n=9)		No PJK(n=112)	
	Pre op	Post op(2- year)	Pre op	Post op(2-year)
Coronal balance	20±12(0-40)	7±6(0-20)	17±13(0-50)	6±6(0-30)
AVT;				
Thoracic	50±47(0-120)	23±25(0-60)	68±30(0-140)	27±19(0-100)
Lumbar	52±15(30-80)	19±12(10-50)	39±24(0-110)	14±13(0-60)
Sagittal balance	-5±21(-40to32)	3±19(-31to24)	-6±23(-43to29)	2±20(-38to31)

Table 3. Pre-and postoperative balance and translation in PJK ,non PJK groups. AVT (apical vertebral translation). Measurements in millimeters.

than several studies.[1,3-6,14].This was a pain free condition with no limitation in daily functional status and the effect on the patients self image was minimal [1,6].

Previous studies reported loss of cervical lordosis for maintaining alignment [1], but, we did not study the cervical spine. The overall sagittal balance was not affected by increase in PJK angle at final follow-up, that this may be due to compensation by free distal segments [6]. At the cervicothoracic junction the transition from mobile to fixed motion segments may play a role in development of flexion deformity at the proximal junction[1,6,10,14-15].

In study by Glattes et al [6],PJK was more common when stopping at T3 but changing the T5-T12 sagittal cobb angle or making the thoracic spine more lordotic with fusion did not lead to PJK , also there was no correlation between addition of ASF or thoracoplasty with increase proximal junctional angle [3,5,6,16-19]. In our study PJK was more common with stopping at T3 with no significant correlation with proximal instrumental vertebra (PIV). We found no correlation between patient characteristics or instrumentation device with developing PJK[6].

PJK observed in short and long fusions and number of fused levels had no effect on developing PJK . one of two cases instrumented with all-screw developed PJK, although samples are few for comparison.[4,5,15]. We did not evaluate SRS-24 questionnaire since previous studies demonstrated poor correlation between radiographic and patient outcomes.[6].

In 2 cases which UIV was at T 7( both lenke type 5 with posterior instrumentation and fusion to L4), both of them during 2-years developed PJK with 10 °increase in proximal junctional angle. Some reports recommended that the implant should not stop at the middle or lower thoracic level, which is important to preserve sagittal contour to prevent proximal junctional kyphosis. Although some studies had acceptable results with short posterior spinal fusion for thoacolumbar and lumbar scoliosis, usually these curves are treated by anterior spinal fusion [1,9,10,20-22].

With the implant ending between T3 and T5, Lee et al [1]stated that all proximal segments with more than 5°segmental kyphosis must be included in the implanted fusion to prevent kyphosis , also Yang et al [23] demonstrated that if the focal kyphotic angle is greater than 10 °at the proposed proximal instrumented level, the fusion should be extended to a higher level, however, we noticed that only one of the 13 cases with abnormal proximal junctional angles at pre-operative,lead to proximal junctional kyphosis until final follow-up and in these cases proximal junctional angle until 2 years post-operation increased with mean of 0.9°.

One major problem in measure of PJK, especially when evaluating the C7-T2 junction, is the position of head, that if flexed during radiography ( as with decreased disc space in anterior with flexion) may falsely showed more junctional angle [6]. One of the drawbacks in this study was the large number of different device and curve patterns, which may obscure

findings specific to a certain pattern, otherwise we believe that this is a normal distribution of curve patterns which need to be instrumented and fused.

Development of PJK was mainly during 2 years post-operation that may be correlated with weakness of proximal posterior spine stabilizing muscles due to immobilization for six months after operation by brace and fear of patients to do exercise during early years of follow-up.

### Conclusion

The prevalence of PJK is low and a silent radiographic problem. In some cases is preventable with perfect preoperative planning. The PJK development was not associated with demographic or radiographic variables or instrumentation types. It is safe to replace long PSF for Lenke type 5 with selective ASF for prevention of stopping at apical thoracic segments and reduction in possibility of proximal junctional flexion changes.

### References

1. Lee GA, Betz RR, Clements DH, Huss GK. Proximal kyphosis after posterior spinal fusion in patients with idiopathic scoliosis. *Spine* 1999; 24:795-799.
2. Rhee JM, Bridwell KH, Won DS, et al. Sagittal plane Analysis of Adolescent Idiopathic Scoliosis: The effect of anterior versus posterior Instrumentation. *Spine* 2002;27:2350-2356.
3. Kim YJ, Bridwell KH, Lenke LG, Kim J, Cho SK. Proximal Junctional Kyphosis in Adolescent Idiopathic Scoliosis following segmental posterior spinal instrumentation and fusion. Minimum 5-year follow-up. *Spine* 2005;30:2045-2050.
4. Hollenbeck SM, Glattes RC, Asher MA, Lai SM, Burton DC. The prevalence of increased Proximal Junctional Flexion following posterior instrumentation and Arthrodesis for Adolescent Idiopathic Scoliosis. *Spine* 2008;33:1675-1681.
5. Kim YJ, Lenke LG, Bridwell KH, Cho SK, Kim J, Chel G, et al. Proximal Junctional Kyphosis after 3 Different types of posterior segmental spinal instrumentation and fusions. Incidence and Risk factor Analysis of 410 cases. *Spine* 2007;32:2731-2738.
6. Glattes RC, Bridwell KH, Lenke LG, Kim YG, Rinello A, et al. Proximal Junctional Kyphosis in adult spinal deformity following long instrumented posterior spinal fusion: Incidence, Outcomes, and Risk factor Analysis. *Spine* 2005;30:1643-1649.
7. Lenke LG, Betz RR, Bridwell KH, Harms J, Clements DH, Lowe TG. Spontaneous Lumbar Curve coronal correction after selective Anterior or Posterior Thoracic Fusion in Adolescent Idiopathic Scoliosis. *Spine* 1999;24:1663-1672.
8. Kim YJ, Bridwell KH, Lenke LG, Rhim S, Kim YW. Is the T9, T11, or L1 proximal level the more stable following lumbar/lumbosacral fusions from the thoracolumbar junction to L5-S1? *Spine* 2007;32:2653-2661.
9. Wang T, Zeng B, Xu J, Chen H, Zhang T, Zhou W et al. Radiographic evaluation of selective anterior thoracolumbar or lumbar fusion for adolescent idiopathic scoliosis. *Eur Spine J*. 2008;17:1012-1018.
10. Richard BS, Birch JG, Herring JA, Johnston CE and Roach JW. Frontal plane and sagittal plane balance following Cotrel-Dubousset instrumentation for idiopathic scoliosis. *Spine* 1989;14:733-737.
11. Hardacker JW, Shurtord RF, Capicotto PN, Pryor PW. Radiographic standing cervical segmental alignment in adult volunteers without neck symptoms. *Spine* 1997;22:1472-1480.
12. Hilibrand AS, Tannenbaum DA, Graziano GP, et al. The sagittal alignment of the cervical spine in adolescent idiopathic scoliosis. *J Pediatr Orthop* 1995;15:627-632.
13. Lenke LG, Betz RR, Harms J, Bridwell KH, Clements DH and Lowe TG. Adolescent idiopathic Scoliosis: A new classification to determine extent of spinal arthrodesis. *J Bone Joint Surg Am* 2001;83:1169-1181.
14. Kwon BK, Elgafy H, Keynan O, Fisher CG, Boyd MC, Paquette SJ, et al. Progressive Junctional Kyphosis at the caudal end of lumbar instrumented fusion: Etiology, Predictors, and treatment. *Spine* 2006;31:1943-1951.
15. Helgeson MD, Shah SA, Betz RR, Clements DH, Newton PO, Bastrom P, Marks M. Proximal Kyphosis in Adolescent Idiopathic Scoliosis following four types of instrumentation. Read at the 75th Annual Meeting Podium presentation of the American Academy of orthopedic surgeons; 2008 March 6, Moscone convention center.
16. Kim YJ, Bridwell KH, Lenke LG, Glattes DH, Rhim S, Chel G. Proximal Junctional Deformity After Segmental Posterior Spinal Instrumentation and fusion: Minimum five-year follow-up. *Spine* 2008;33:2179-2184.
17. Sponseller PD, Betz R, Newton PO, Lenke LG,



Low T, Crawford A, et al. Differences in curve Behavior After fusion in Adolescent idiopathic scoliosis patients with open triradiate cartilage. *Spine* 2009;34:827-831.

18. Suk S, Kim JH, Kim SS, Lee JJ, Han YT. Thracoplasty in thoracic adolescent idiopathic scoliosis. *Spine* 2008; 33:1061-1067.

19. Clement JL, Chau E, Kimkpe C, Vallade MJ. Restoration of thoracic kyphosis by posterior instrumentation in adolescent idiopathic scoliosis. *Spine* 2008; 33:1579-1587.

20. Sanders AE, Baumann R, Brown H, Johnston CE, Lenke LG, Sink E. Selective Anterior Fusion Of Thoracolumbar/Lumbar Curves in Adolescents. when can the Associated Thoracic Curve Be Left Unfused? *Spine* 2003;28:706-714.

21. Kaneda K, Fujiya N, Satho S. Results with Zielke instrumentation for idiopathic thoracolumbar and lumbar scoliosis. *Clin Orthop* 1986; 205:195-203.

22. Moe JH, Purcell GA, Bradford DS. Zielke instrumentation (VDS) for the correction of spinal curvature: Analysis of results in sixty six patients. *Clin ortop* 1999;364:32-39.

23. Yang SH, Chen PQ. Proximal Kyphosis After Short Posterior Fusion for Thoracolumbar Scoliosis. *Clin Orthop Relat Res* 2003;411:152-158.