

## Case Reports

### PULMONARY BLASTOMA: REPORT OF A CASE AND REVIEW OF THE LITERATURE

MOHAMAD REZA DAVOUDI,\* M.D., AND DONIA  
FARROKH,\*\* M.D.

*From the Department of Radiology, Imam Reza Medical Center, Mashhad University of  
Medical Sciences, Mashhad, Islamic Republic of Iran.*

#### ABSTRACT

We describe a case of pulmonary blastoma, a rare primary lung malignancy which affects a younger population. This tumor contains both mesenchymal and epithelial elements. Pulmonary blastoma tends to relapse locally and metastasizes mainly in the first few years. It has a poor 5-year prognosis, and shows a potential radio-chemosensitivity. Because these tumors are considered malignant, surgical excision is recommended.

In this paper, we describe a case of pulmonary blastoma in a 3 year old boy with a brief review of literature.

*MJIRI, Vol. 13, No. 3, 231-234, 1999*

#### INTRODUCTION

Pulmonary blastoma is a rare malignant tumor that histologically recapitulates developing lung in early fetal life.<sup>8,9</sup> Because of this resemblance, Barnard originally labeled the tumor in 1952 an "embryoma".<sup>1</sup> In 1967, Spencer hypothesized that the tumor developed from immature pleuroperitoneal tissue believed to be capable of differentiating into both mesenchymal and epithelial portions of the lung. The development of neoplasia in this tissue was thought to be analogous to that of Wilm's tumor (nephroblastoma) from primitive renal blastoma, and the term pulmonary blastoma was proposed to emphasize this feature.<sup>14</sup>

This concept was supported recently by the result of immunohistochemical and ultrastructural studies.<sup>4</sup> The appropriateness of the term "blastoma" has been questioned

by some authors who consider this neoplasm to represent a variant of carcinosarcoma. Although this latter concept may be appropriate, the characteristic histologic resemblance of pulmonary blastoma to fetal lung during the pseudoglandular period suggests that it may have fundamental differences from the neoplasm that is usually called carcinosarcoma.

Pulmonary blastoma is a rare neoplasm, accounting for 0.5 percent of all malignant pulmonary tumors.<sup>5</sup> Approximately 25% of reported cases have occurred in pediatric patients.<sup>16</sup> Because of its slow growth, peripheral location and absence of obstructive effects on the bronchial tree, it may become a very large round mass before discovery.<sup>6,7</sup> The prognosis is poor among those who have metastatic disease, or a primary tumor larger than 5 cm.<sup>14</sup>

In this paper the radiology, pathology and clinical course of this rare neoplasm are discussed.

\* Professor of radiology

\*\* Assistant professor of radiology

CASE REPORT

A 3 year old boy was admitted to the Pediatric Department of Imam Reza Hospital of Mashhad University in May 1997. He presented with a history of low grade fever, cough, dyspnea and tachypnea. On physical exam, there were no respiratory sounds in the left lung. He had severe respiratory distress and was seriously ill. There was no peripheral lymphadenopathy or other abnormal findings on physical exam. Paraclinical work up showed no gross abnormality.

On chest X-ray, opacification of the left lung field with mediastinal shift to the right was the predominant roentgenologic feature (Fig. 1). The opacity was uniform and was interpreted as a massive pleural effusion or a large pulmonary mass lesion with pleural fluid.

Ultrasonography was performed with a 3-5 MHz transducer and showed a solid hypoechoic pulmonary mass in the upper lobe with pleural effusion in the left hemithorax.

Contrast-enhanced computed tomography of the thorax showed a round, well defined mass 11 cm in size in the left upper lobe with a thick, irregular enhancing rim and hypodense center (Fig. 2). There was also a left-sided fluid collection posteriorly. The atelectatic left lower lobe was seen centrally with its open bronchus (Fig. 3).

On the basis of these findings, we had two diagnoses for this patient:

1. A primary lung tumor, such as a pulmonary blastoma or pulmonary sarcoma with pleural effusion.
2. An infected pulmonary cyst with pleural effusion.

In May 1997, thoracotomy was performed to establish the diagnosis. During thoracotomy, a large tumor involving the left upper lobe was found. A left upper lobectomy with tumor decortication of the pleural space achieved total gross tumor removal.

Histological analysis of the tumor showed a biphasic structure with epithelial and mesenchymal components which was diagnosed as pulmonary blastoma. After operation the patient also received chemotherapy. Long-term follow-up is required to provide prognostic information.

DISCUSSION

The spectrum of malignant tumors of infancy and childhood differs from that in adults.<sup>3</sup> In infants and children under 5 years of age, the most prominent tumors are embryomas or blastomas. Although primary pulmonary neoplasms are rare in children, they must be excluded when a mass lesion is noted on a chest X-ray.<sup>3-8</sup> Usually the mass will prove to be a congenital or inflammatory lesion, but unfortunately some malignancies do occur.

The existence of biphasic neoplasms occurring primarily in the lung is a well-known rare event. The spectrum of malignant pulmonary tumors displaying a mixed epithelial/mesenchymal growth pattern is rather narrow.<sup>3,9</sup> The two

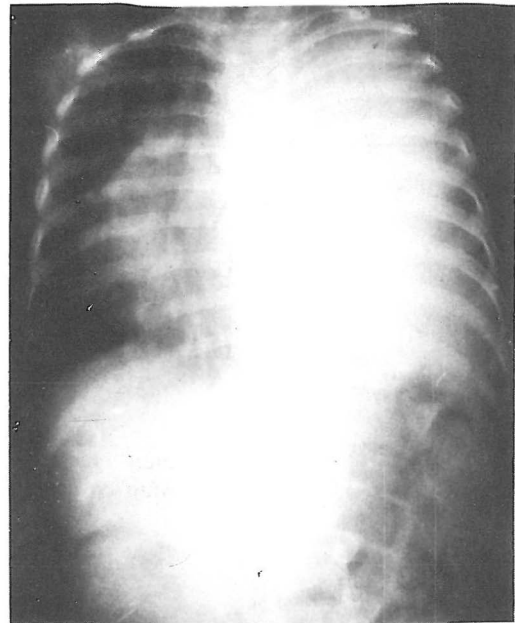


Fig. 1. Chest radiograph reveals opacification of the left lung field with mediastinal shift to the right.

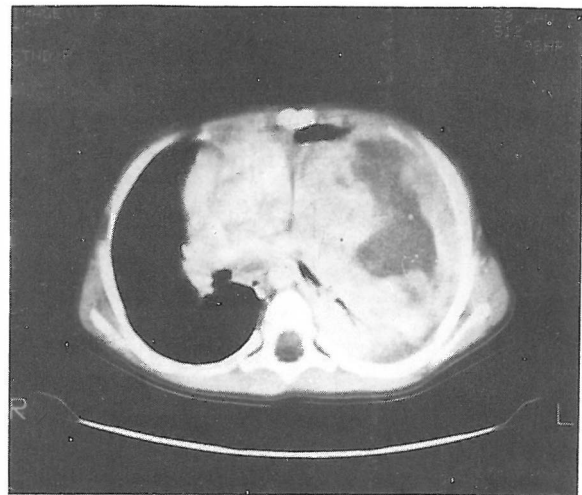

Fig. 2. Contrast-enhanced CT reveals a round mass in the upper lobe with an enhancing rim and irregular center.

most often encountered are carcinosarcomas and pulmonary blastomas.

Pulmonary blastomas are primary malignancies that include the adult type biphasic pulmonary blastoma and well-differentiated fetal adenocarcinoma, and the childhood type pleuropulmonary blastoma.<sup>12</sup> Well-differentiated fetal adenocarcinoma and biphasic blastoma have histologic similarities leading these tumors to be classified as pulmonary blastoma, but they have distinct clinical and prognostic features.<sup>12</sup>

Pathologically pulmonary blastomas typically are large

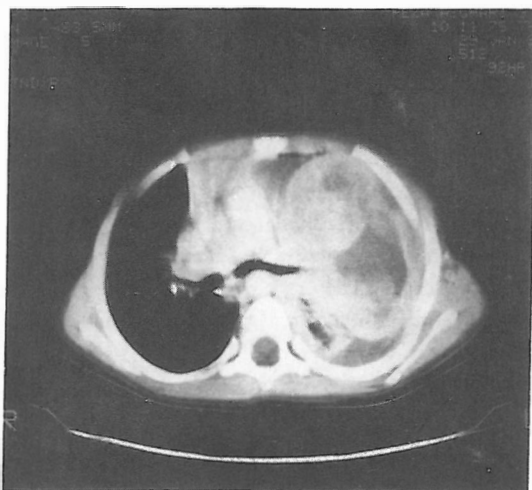


Fig. 3. Contrast-enhanced CT reveals a left sided fluid collection and left lower lobe atelectasis.

well-defined masses located in the periphery of the lung. Extension to and growth within adjacent bronchial lumina may occur but is unusual. Hemorrhage and necrosis are frequent.<sup>15</sup> Microscopically the tumor consists of an admixture of primitive-appearing epithelium and stroma that superficially resembles the pseudoglandular period of lung development. The epithelial cells are arranged in small, slit-like spaces or branching tubules, and are surrounded by polygonal or spindle-shaped stromal cells with hyperchromatic nuclei; occasionally the stroma may differentiate into chondroid or osteoid tissue.<sup>12</sup>

Metastases may show predominance of either epithelial or stromal components, and sometimes both.<sup>12,15</sup>

Little information is available on genetic changes in these tumors, because they are rare. In recent years the immunohistochemical and molecular analysis for P<sub>53</sub> and MDM<sub>2</sub> protein gene products believed to be significant in the pathogenesis of bronchogenic carcinoma, suggest that the adult type biphasic blastoma may have a similar pathogenesis to bronchogenic carcinoma.

Review of the literature has shown that a large number of pediatric pulmonary blastomas are associated with cysts of bronchiolar origin.<sup>10</sup> Because of the development of this malignant tumor in areas of cystic lung disease, surgical excision or close follow-up of pulmonary cysts in children is strongly recommended.<sup>10,17</sup>

Pulmonary blastoma is rare: 207 cases had been documented in the literature by 1995. There is a male-to-female ratio of 3 to 7.<sup>13</sup> The tumor is usually in the periphery, and upper-lobe involvement is more frequent.<sup>6</sup> Some patients are asymptomatic but hemoptysis, cough and chest pain are frequent complaints.<sup>6</sup>

The roentgenographic features are not specific and the tumor usually forms a large, fairly well-defined mass in the lung. In most patients chest X-ray can not help to distinguish

pulmonary blastoma from other peripheral pulmonary masses.

The ultrasonographic pattern of the tumor may be solid, cystic or multicystic. When the tumor is solid, it is usually hypoechoic with some echo-free areas in the center due to necrosis or hemorrhage.

CT usually shows a round complex mass lesion. In huge tumors with central necrosis, contrast-enhanced CT reveals a mass with an enhancing rim and irregular center.

A correct preoperative diagnosis is uncommon. Bronchial washing and brushings and sputum samples often give negative results. Percutaneous biopsy is more likely to contain diagnostic cells, whose appearances may suggest a mixed epithelial and mesenchymal neoplasm.

Pulmonary blastoma is malignant, and eventually metastasis to hilar nodes, pleura and elsewhere takes place. The prognosis is poor among those who have metastatic disease or a primary tumor larger than 5cm. Of 39 patients reviewed by Fong, 17 (44 percent) developed metastases and only two of these survived longer than 2 years. Despite this, occasional patients show exceptionally long survival, even in the presence of metastatic disease. There is some evidence that the prognosis is better in women, and in patients with smaller primary tumors.

Because pulmonary blastoma is considered malignant, surgical excision followed by conventional chemotherapy is recommended. Some patients may need intensive chemotherapy after surgery.<sup>9</sup> In the management of advanced pulmonary blastoma in children with metastatic lesions, intensive chemotherapy should be tested as initial therapy, as well as an adjunct to surgery.<sup>9</sup>

#### ACKNOWLEDGEMENT

We would like to thank Dr. Mirafsharie for his histological diagnosis and Dr. Moddaressi for follow-up of the patient.

#### REFERENCES

1. Barnard WG: Embryoma of lung. *Thorax Clin Pathol* 299: 190-192, 1952.
2. Barson AJ, Jones AW: Pulmonary blastoma. *J Clin Pathol* 27: 480, 1968.
3. Berho MO, Moran CA: Malignant mixed epithelial/mesenchymal neoplasms of the lung. *Semin Diagn Pathol* 12(2): 123-39, 1995.
4. Bonder SM: Mutation in the P53 gene in pulmonary blastoma: immunohistochemical and molecular studies. *Hum Pathol* 27(11): 1117-23, 1996.
5. Calabria R, Srikanth MS: Management of pulmonary blastoma in children. *J Am Surg* 59 (3): 192-6, 1993.
6. Francis D, Jacobsen M: Pulmonary blastoma. Preoperative cytologic and histologic findings. *Acta Cytol* 23: 437, 1979.
7. Klein RL: Pulmonary blastoma in children. *J Pediatr Surg* 29

## Pulmonary Blastoma

- (12): 1553-6, 1994.
8. Lenense GP, et al: Pulmonary blastoma: a rare lung malignancy. *J Lung Cancer* 15 (2): 233-7, 1996.
  9. Lobo-Sanahuia F: Pulmonary blastoma in children: response to chemotherapy. *J Med Pediatr Oncol* 26 (3): 196-200, 1996.
  10. Lopez Anderu JA, Comez J: Pulmonary blastoma and congenital cystic malformations. *J Pediatr* 129 (5): 113-5, 1996.
  11. Merriman TE: Pleuropulmonary blastoma. *J Pediatr Pulmonol* 22(6): 408-11, 1996.
  12. Pacinda SJ, Ledge SC: P53 and MDM2 immunostaining in pulmonary blastomas. *Hum Pathol* 27(6): 542-6, 1996.
  13. Roth JA: Pulmonary blastoma evolving into carcinosarcoma. A case study. *Am J Surg Pathol* 2: 407, 1987.
  14. Spencer RT: Pulmonary blastoma. *J Pathol* 82: 167, 1967.
  15. Samsonou VA, et al: Blastoma of the lung. *Arch Pathol* 56 (2): 60-69, 1994.
  16. Seballos RM, et al: Pulmonary blastoma in children. *J Pediatr Surg* 29 (12): 1553-6, 1994.
  17. Tagge EP, Mulvihill D: Childhood pleuropulmonary blastoma: caution against nonoperative management of congenital lung cysts. *J Pediatr Surg* 31 (1): 187-9, 1996.
  18. Weinblatt ME: Pulmonary blastoma associated with cystic lung disease. *Cancer* 49: 669, 1982.