

The Association between Eye Sign and Capillaroscopy Changes in Patients with Scleroderma Spectrum Disease Presenting with Raynaud's Phenomenon, as Compared to the Normal Population

Saeedeh Shenavandeh^{1*} , Sanaz Dehghani¹

Received: 1 Jul 2025

Accepted: 27 Jan 2026

Published: 18 Mar 2026

Abstract

Background: Capillaroscopy is widely recognized for its role in evaluating microcirculation, particularly in patients with Raynaud's phenomenon and scleroderma-spectrum diseases. The eye sign may provide complementary insights into microvascular assessment. This study primarily investigates whether the eye sign can differentiate patients with systemic sclerosis (SSc) and other connective tissue diseases (CTDs) presenting with Raynaud's from healthy controls. Additionally, we explored correlations between eye sign scores and capillaroscopic changes within patient subgroups.

Methods: This cross-sectional study enrolled 117 individuals, divided into three groups: healthy controls (N=31), systemic sclerosis (SSc) (N=49), and other connective tissue diseases (CTDs) presenting with Raynaud's phenomenon (RP) (N=37). Clinical data, including lung involvement, pulmonary artery hypertension, and skin score, as well as laboratory results, capillaroscopy findings, and eye sign (assessed by naked-eye criteria), were collected from all participants. The primary analysis compared ocular symptom scores between patients and healthy controls. Subgroup analyses and correlation assessments were exploratory.

Results: Eye sign scores did not significantly differ between the combined patient group and healthy controls ($P = 0.158$). Subgroup comparisons also revealed no significant differences ($P = 0.297$ for SSc, $P = 0.262$ for other CTDs). Furthermore, no significant associations were observed between eye sign scores and capillaroscopy findings within the study groups. Additionally, no significant associations were found between eye sign scores and specific clinical manifestations. Confidence intervals were provided to reflect statistical uncertainty.

Conclusion: This study found no statistically significant differences in Eye sign scores between patients and healthy controls, nor any associations with capillaroscopic abnormalities. However, due to the limited sample size and the exploratory nature of the subgroup analyses, these findings should be interpreted with caution.

Keywords: Eye sign, Capillaroscopy, Systemic sclerosis, Raynaud's

*This work has been published under CC BY-NC-SA 4.0 license.

Copyright© Iran University of Medical Sciences

Cite this article as: Shenavandeh S, Dehghani S. The Association between Eye Sign and Capillaroscopy Changes in Patients with Scleroderma Spectrum Disease Presenting with Raynaud's Phenomenon, as Compared to the Normal Population. *Med J Islam Repub Iran*. 2026 (18 Mar);40:28. <https://doi.org/10.47176/mjiri.40.28>

Introduction

Capillaroscopy is a non-invasive, safe, and effective diagnostic technique utilized to evaluate microcirculation. It provides detailed images of capillary morphology, which is crucial for assessing various rheumatic conditions, including patients with Raynaud's Phenomenon (RP) (1-3). This

method is widely employed due to its accessibility and its ability to differentiate between primary and secondary forms of RP, which is essential for the early diagnosis and management of potential underlying connective tissue diseases (CTDs) (4, 5). The most distal capillaries are directly

Corresponding author: Saeedeh Shenavandeh, shenavande@sums.ac.ir

¹ Department of Rheumatology, Shiraz Medical School, Shiraz University of Medical Sciences, Shiraz, Iran

↑What is "already known" in this topic:

Capillaroscopy is a noninvasive method used to evaluate microcirculation, particularly in patients with Raynaud's phenomenon and scleroderma spectrum disorders. The eye sign was evaluated in only 20 patients with scleroderma as an additional method for assessing microcirculation.

→What this article adds:

We found no statistically significant difference in eye sign scores between the SSc and other CTDs groups when compared to healthy controls. Additionally, there was no significant association between eye sign scores and specific clinical manifestations in these patients. Furthermore, the eye sign and capillaroscopy changes did not correlate with one another.

exposed and positioned perpendicular to the nail bed, facilitating visualization with point-of-care tools in the clinic (6).

In systemic sclerosis (SSc) and several other autoimmune rheumatic diseases, including dermatomyositis, antisynthetase syndrome, antiphospholipid syndrome, mixed connective tissue disease (MCTD), systemic lupus erythematosus (SLE), and Sjögren syndrome, the phenomenon (RP) can be observed and is associated with structural alterations in the microvasculature. In fact, in SSc and other diseases within the scleroderma spectrum, microvascular injury or damage and endothelial cell dysfunction occur at an early stage of pathogenesis (7).

Several regions of the human body allow for direct observation of systemic microcirculation, including the nail fold, bulbar conjunctiva, tongue, buccal mucosa, and lip (8, 9). In 1968, it was reported that the bulbar conjunctiva could serve as an additional site for microcirculation evaluation (10). Compared to other regions, the bulbar conjunctiva exhibits greater stability and is less influenced by temperature variations. However, the complexity of its implementation has restricted its application in clinical practice.

The eye sign, a method for assessing bulbar conjunctiva microcirculation, was introduced into clinical practice in 1988 (8). Measurements of vessel diameter and blood flow in healthy individuals have revealed a range of vessel diameters from approximately 8.7 to 24.3 microns (11). In an article by Shi (2023), the eye sign score was discussed as a potential non-invasive assessment tool for microvascular involvement in rheumatologic diseases, such as neuropsychiatric systemic lupus erythematosus. This method entails the direct observation of specific microvascular changes in the bulbar conjunctival microvasculature, including ramified loops, microangiomas, and wound spots (12). The eye sign score may be emerging as a valuable tool for assessing microcirculation in patients with SSc, as suggested by Yu et al. Their findings demonstrated consistency between the eye sign score and NVC. Furthermore, they illustrated the ability of the eye sign score to effectively distinguish between different morphological changes associated with the early, active, and late phases of SSc, as well as to differentiate between pulmonary involvements, such as pulmonary arterial hypertension (PAH) and interstitial lung diseases (13). The findings regarding the association between retinal changes in scleroderma and capillaroscopy have been inconsistent; some studies have reported a significant correlation, while others have found no such relationship (14, 15).

To address both diagnostic and pathophysiological questions, this study included three distinct groups: patients with SSc, patients with other CTDs, and healthy controls. SSc was selected as a prototypical autoimmune disease characterized by well-defined microvascular involvement, while other CTDs represent a spectrum of vascular phenotypes. The inclusion of healthy individuals provided a baseline reference for evaluating the diagnostic performance of the Eye sign. This design facilitated pooled analysis for diagnostic assessment and exploratory subgroup comparisons to investigate disease-specific vascular patterns.

This study primarily aimed to assess whether eye symptoms could differentiate patients with connective tissue diseases presenting with Raynaud's phenomenon from healthy individuals. Additionally, comparisons of subgroups across disease types and correlation analyses with capillaroscopy findings were conducted.

Methods

This cross-sectional study was designed primarily to assess whether eye symptoms can distinguish patients with connective tissue diseases from healthy individuals. We evaluated patients with systemic sclerosis (SSc), dermatomyositis (DM), mixed connective tissue disease (MCTD), and undifferentiated connective tissue disease (UCTD) who presented with the RP (fulfilling the International Consensus Criteria for RP) (16). These patients met the 2013 American College of Rheumatology (ACR) and European League Against Rheumatism (EULAR) criteria for the diagnosis of SSc, the 2017 EULAR/ACR Classification Criteria for Adult and Juvenile Idiopathic Inflammatory Myopathies with definite dermatomyositis, and the MCTD classification criteria established by Alarcon-Segovia et al. (17-19).

Sample size estimation was based on previous studies evaluating the Eye sign and nailfold capillaroscopy in CTDs (13), utilizing the formula for comparing two independent means:

$$n = \frac{2\sigma^2(Z_{1-\alpha/2} + Z_{1-\beta})^2}{\Delta^2}$$

Assuming $\sigma \approx 6$ and $\Delta \approx 3$, the minimum required sample size per group was approximately 30. Our final sample, comprising 86 patients and 31 controls, exceeded this threshold, thereby supporting the adequacy of our design for exploratory analysis. Type I and II error thresholds were established at $\alpha = 0.05$ and $\beta = 0.20$ (80% power). Although these parameters dictate our target sample size, the final cohort was recruited based on availability, thus constituting a convenience sample.

If patients exhibited signs and symptoms suggestive of a CTD but did not meet the established classification criteria, they were classified as UCTD (20). All patients were referred to Hafez Hospital, affiliated with Shiraz University of Medical Sciences, for capillaroscopy. Participants were recruited between March 2022 and March 2024. For the primary analysis, patients with SSc and other CTDs were grouped and compared with healthy controls. Subgroup comparisons were conducted for SSc, UCTD, DM, and MCTD. Patients were seen in the rheumatology clinic of Hafez Hospital, where their clinical and laboratory information was collected and recorded in a chart. Concurrently, capillaroscopy was performed, and all patients received both oral and written information and signed the informed consent form.

We excluded cases in which basic initial complementary tests were not performed. Additionally, patients with smoking habits, diabetes mellitus, or other relevant conditions were excluded from the study. All patients were assessed for sex, age, and symptom duration. The available serological and laboratory tests, including ANA, RF, Anti-CCP, Anti-Scl-70, Anti-Ro, Anti-La, Anti-dsDNA, Anti-Sm,

Anti-RNP, Anti-Jo-1, and Anticentromere, as well as ESR and CRP, were recorded. On the same day, patients who met the inclusion criteria underwent capillaroscopy using the Euromex ST. 1740 stereomicroscope, manufactured in Holland, with $\times 250$ magnification and a Cmax D.C.5000 video camera (5 megapixels). Eight fingers from both hands, excluding the thumbs, were assessed. Fingers with infection, inflammation, signs of trauma or injury, deformities, or poor accessibility were also excluded.

The data were recorded in a format that included the shape of the capillaries (normal or abnormal), capillary diameter—defined as the largest diameter of the apical side of the nailfold capillaries (if ≥ 20 μm , it was categorized as capillary dilatation, and if ≥ 50 μm , it was classified as a giant loop)—mean capillary density (with a mean capillary density of >9 capillaries/mm considered very good density, between 7-9 capillaries/mm regarded as good density, between 4-6 capillaries/mm identified as reduced (low) density, and <4 capillaries/mm classified as very low density); and the presence or absence of hemorrhage (total number) in the affected fingers, based on the international Delphi consensus for data reporting and the PANLAR capillaroscopy study group consensus. The overall NFC findings were categorized as follows: normal, scleroderma pattern (further classified as early, active, and late scleroderma pattern), or non-specific abnormalities (21, 22).

Simultaneously, images of the sclera of both eyes of the patients were captured using a mobile camera, and the eight-eye sign score was assessed (for both eyes) based on visual criteria (Table 1) (13).

In patients with SSc, clinical subsets (diffuse or limited) and skin scoring in scleroderma patients were conducted according to the definition provided by LeRoy et al. using the MRSS (Modified Rodnan Skin Score) (23).

Pulmonary involvement, specifically interstitial lung disease, and pulmonary artery hypertension were evaluated using high-resolution computed tomography (HRCT) during the initial screening and echocardiography as a fundamental clinical assessment, respectively. A pulmonary artery pressure exceeding 40 mmHg on echocardiography was classified as pulmonary artery hypertension (PAH) (24).

Abnormalities in ocular symptoms were primarily compared between patients and healthy subjects. Comparisons

of subgroups and their relationships with capillaroscopic changes were conducted. Subgroup analyses across systemic sclerosis (SSc), undifferentiated connective tissue disease (UCTD), dermatomyositis (DM), and mixed connective tissue disease (MCTD) were performed in an exploratory framework due to limited sample sizes. Exploratory analyses were undertaken to assess the relationships between ocular symptoms and organ involvement (lung, heart, and skin scores) in patient subgroups. Assessments and analyses were conducted using SPSS-26 for Windows, employing variance analysis and the κ -square test. Results are presented as mean \pm standard deviation, and a p -value of <0.05 was considered statistically significant.

To evaluate the diagnostic performance of the Eye sign, we conducted receiver operating characteristic (ROC) curve analysis to compare patients and healthy subjects. Sensitivity, specificity, positive predictive value (PPV), and negative predictive value (NPV) were calculated using standard thresholds. The area under the curve (AUC) was employed to assess overall discrimination ability. To account for potential confounders, we performed an analysis of covariance (ANCOVA) with the Eye sign score as the dependent variable and group (patients vs. controls) as the fixed factor, adjusting for age, sex, and disease duration.

Results

A total of 117 individuals were studied. Among the participants, 49 (41.9%) had SSc, 37 (31.6%) had other CTDs (5 had dermatomyositis, 5 had mixed connective tissue disease, and 23 had undifferentiated connective tissue disease), and 31 (26.5%) belonged to the normal population group. The study population was predominantly female (90.6%), with a mean age of 46.8 years (standard deviation: 11.6 years). In all three studied groups, women constituted the majority (SSc: 99.3%, other CTDs: 94.6%, control: 86%), and there was no significant difference in gender distribution among the three groups ($P=0.671$). The mean ages in the SSc group, other CTDs, and controls were 47.5, 47.4, and 45.2 years, respectively ($P=0.082$).

RP was observed in all patients in the SSc group as well as in the group with other CTDs. In the SSc group, the prevalence of dysphagia and telangiectasia was 26.5% and 27%, respectively. Among the 49 patients diagnosed with SSc, 31 underwent evaluation for interstitial lung diseases, of

Table 1. The eye sign scores

Characteristics	Capillary character/score	
Enlarged capillaries	3-6	5
	>6	10
Twisted capillaries	3-6	5
	>6	10
Helical capillaries		10
	The ratio of the deformity area of ramified loops to the total conjunctival area.	1/8-1/4
Hemorrhages	$>1/4$	10
	1-3	5
Microangioma	>3	10
	Coloration of the vessels and skin surrounding the eyelid.	Mild
Wound spot	Serious	10
	1-2	5
	>3	10

Table 2. Primary comparison of eye sign sores between patients and healthy controls

Group	N	Mean Eye sign Score \pm SD	95% CI	P-value		AUC (95% CI)	Sensitivity (%)	Specificity (%)	PPV (%)	NPV (%)
				Unadjusted P-value	Adjusted P-value					
Patients (SSc+CTDs)	86	20.87 \pm 6.07	[19.56–22.18]	0.158	0.174	0.61 (0.51–0.71)	48.8	67.7	78.4	34.1
Healthy Controls	31	19.00 \pm 6.99	[16.54–21.46]							

which 10 patients (32.3%) were found to have interstitial lung disease. Additionally, 7 patients were assessed for pulmonary hypertension, and 6 of these patients (85.7%) were diagnosed with pulmonary hypertension. The mean skin score was 10.43 \pm 6.50.

The rates of various symptoms among patients with other CTDs were as follows: arthritis (8.3%), arthralgia (55.6%), periorbital edema (10.8%), morning stiffness (2.7%), dysphagia (10.8%), lip furrowing (6%), facial or palmar telangiectasia (27.0%), peringuinal erythema (13.5%), mechanical hands (5.4%), puffy hands (31.4%), dry mouth (40.5%), dry eye (13.5%), heartburn (37.8%), and Gottron's sign (8.1%). This group of patients did not have available HRCT/S or echocardiography on the day of evaluation;

therefore, data regarding pulmonary and cardiac involvement were not accessible. However, none exhibited any symptoms of lung or cardiac involvement during history taking and examination.

Eye sign scores were compared between the combined patient group (SSc and other CTDs) and healthy controls (Table 2). The mean Eye sign score was 20.87 \pm 6.07 in patients and 19.00 \pm 6.99 in controls, revealing no statistically significant difference ($P = 0.158$; Table 1). This indicates limited diagnostic differentiation of Eye sign between patients and healthy individuals. After adjusting for age, sex, and disease duration using ANCOVA, the difference in Eye sign scores between patients and healthy controls

Table 3. Capillaroscopy and laboratory characteristics in patients with SSc, other CTDs, and the control group

Variable		SSc group (N=49)	other CTDs (N=37)	control group (N=31)	P	
		Frequency (Percentage)	Frequency (Percentage)	Frequency (Percentage)		
Capillaroscopy pattern	Normal	1 (2.1%)	1 (2.9%)	31 (100%)	0.002	
	Nonspecific abnormalities	14 (29.8)	23 (67.6)	0 (0%)		
	SSc pattern	Early	4 (8.5)	4 (11.8)		0 (0%)
		Late	0 (0%)	0 (0%)		0 (0%)
		Active	28 (59.6)	6 (17.6)		0 (0%)
Total SSc pattern	32 (68.1)	10 (29.4)	0 (0%)			
Morphology	abnormal	14 (28.6)	9 (24.3)	-	0.744	
Morphology range	<33% of total capillaries	7 (14.3)	6 (75)	-	0.320	
	33-66% of total capillaries	4 (8.2)	2 (25)	-		
	More than 66% of total capillaries	3 (6.1)	0 (0)	-		
Dimension	Dilation	20 (40.8)	23 (62.2)	-	0.147	
	Giant loop	1 (2)	10 (27)	-		
	Dilation and Giant Loop	24 (49)	0 (0)	-		
Mean capillary density	Good density (≥ 7)	22 (44.9)	27 (73)	-	0.084	
	Reduced density (4-7)	22 (44.9)	5 (13.5)	-		
	Very low density (<4)	2 (4.1)	2 (5.4)	-		
Hemorrhages	Present	30 (61.2)	21 (56.8)	-	0.751	
Lab Test	Total Tests Performed	Frequency (%) / mean \pm standard deviation				
		SSc group (N=49)	Other CTDs (N=37)	Control group (N=31)		
ANA Positive	113	38 (79.2)	24 (68.6)	0 (0)		
dsDNA Positive	110	0 (0)	2 (6.1)	0 (0)		
RF positive	113	0 (0)	2 (5.7)	0 (0)		
ACA positive	108	0 (0)	1 (3.1)	0 (0)		
Anti-RO positive	110	1 (2.1)	9 (27.3)	0 (0)		
Anti-LA positive	109	0 (0)	3 (9.4)	0 (0)		
Anti-Jo positive	109	0 (0)	1 (3.1)	0 (0)		
Anti-RNP positive	110	0 (0)	7 (21.2)	0 (0)		
ESR (millimeters per hour)	102	14.91 \pm 7.30	20.34 \pm 21.33	7.61 \pm 3.69		

ANA: Antinuclear Antibody Positive; dsDNA: Double-Stranded DNA Antibody Positive; RF: Rheumatoid Factor Positive; ACA: Anti-cardiolipin Antibody Positive; Anti-RNP Positive: Anti-Ribonucleoprotein Antibody Positive; ESR: Erythrocyte Sedimentation Rate.

remained non-significant (adjusted $P = 0.174$). This suggests that these covariates did not substantially influence the primary outcome.

ROC analysis for the Eye sign yielded an AUC of 0.61 (95% CI: 0.51–0.71), indicating limited discriminative ability between patients and healthy controls. At a threshold of ≥ 22 , sensitivity was 48.8%, specificity was 67.7%, PPV was 78.4%, and NPV was 34.1%. These findings suggest that the Eye sign alone may not be sufficient for diagnostic differentiation.

In the studied population, 62 participants (53%) tested positive for ANA. Additionally, 2 individuals (1.7%) were positive for dsDNA, with the same percentage (1.7%) observed for RF. Thirteen participants (12%) tested positive for ACA. Furthermore, 10 individuals (8.5%) were positive for Anti-RO, and 3 (2.6%) tested positive for Anti-LA. One participant (0.9%) was positive for Anti-Jo, and 7 individuals (6%) demonstrated Anti-RNP positivity. The average ESR was recorded at 14.15 ± 15.49 mm/hour (Table 3).

In the capillaroscopy evaluation, the SSc group demonstrated an SSc pattern in 68.1% of cases and nonspecific abnormalities in 29.8%. In contrast, the other CTDs group exhibited an SSc pattern in only 29.4% of cases, with nonspecific abnormalities observed in 67.6%. The study groups differed significantly regarding capillaroscopy patterns ($P=0.002$), with the SSc group showing the highest prevalence of the SSc pattern. Additionally, the SSc group displayed a higher occurrence of active scleroderma patterns compared to other CTDs; however, this difference was not statistically significant ($P=0.053$). No significant differences were noted in other elements of capillaroscopy (Table 3).

As shown in Table 4, none of the studied groups exhibited a significant difference in any of the eye sign compared to the control group. Although the eye sign score was lower in the normal population than in the other two groups, the difference between these groups and the control group was

not statistically significant ($P>0.05$). Subgroup comparisons of Eye sign scores across SSc, other CTDs, and controls were exploratory in nature. Due to small sample sizes, these findings should be interpreted with caution. Where applicable, 95% confidence intervals were reported to reflect statistical uncertainty.

As demonstrated in Table 5, no significant relationship was observed between the eye sign score and capillaroscopy changes in patients with SSc and other CTDs.

In patients with SSc, the analysis of the total eye score across various clinical manifestations revealed no significant differences, as indicated by p-values exceeding 0.05. Participants with dysphagia had a mean total eye score of 21.53 ± 7.18 , compared to 20.13 ± 5.27 in those without dysphagia ($P=0.900$). For interstitial lung diseases, the mean scores were 20.50 ± 3.68 and 20.71 ± 5.76 , respectively ($P=0.819$). Regarding pulmonary hypertension, individuals with the condition had a mean score of 17.50 ± 5.24 , while those without it scored 25.00 ± 0.00 ($P=0.286$). Furthermore, facial or palmar telangiectasia exhibited mean scores of 19.68 ± 5.81 and 22.05 ± 5.60 , respectively ($P=0.175$). The skin score showed no significant correlation with the eye score ($r = 0.212$, $P = 0.182$) (Table 6).

In the other CTDs group, the results indicated that participants with arthritis had a mean score of 25.00 ± 5.00 , compared to 20.80 ± 6.72 for those without the condition ($P = 0.266$), suggesting no significant difference. Similarly, arthralgia ($P = 0.290$), Gottron sign, periorbital edema ($P = 0.421$), peringual erythema ($P = 0.928$), mechanic's hands ($P = 0.801$), puffy hands ($P = 0.822$), morning stiffness ($P = 0.571$), dry mouth ($P = 0.658$), dry eye ($P = 0.243$), heartburn ($P = 0.323$), dysphagia ($P = 0.900$), and facial or palmar telangiectasia ($P = 0.905$) also demonstrated no significant differences (Table 6).

A sample of capillaroscopy and the eye signs of both eyes of two patients with systemic sclerosis are displayed in Figure 1.

Table 4. Exploratory comparison of eye sign scores across SSc, other CTDs, and healthy controls

Characteristics	Condition	SSc group (N=49)	other CTDs group (N=37)	control group (N=31)
Enlarged capillaries	3-6	11 (22.4)	9 (24.3)	1 (3.2)
	>6	0 (0)	1 (2.7)	0 (0)
P (comparison with control group)		0.112	0.093	-
Twisted capillaries	3-6	27 (55.1)	17 (45.9)	19 (61.3)
	>6	15 (30.6)	15 (40.5)	11 (35.5)
P (comparison with control group)		0.562	0.497	-
Helical capillaries		7 (14.3)	4 (10.8)	1 (3.2)
P (comparison with control group)		0.093	0.068	-
The ratio of the deformity area of ramified loops to the total conjunctival area.	1/4-1/8	36 (73.5)	24 (64.9)	21 (67.7)
	<1/4	13 (26.5)	12 (32.4)	9 (29)
P (comparison with control group)		0.880	0.911	-
Hemorrhages	1-3	25 (51)	15 (40.5)	12 (38.7)
	>3	0 (0)	0 (0)	1 (3.2)
P (comparison with control group)		0.243	0.340	-
Color tuning of the vessels and skin surrounding the eyelid.	Mild	32 (65.3)	25 (67.6)	15 (48.4)
	serious	2 (4.1)	2 (5.4)	2 (6.5)
P (comparison with control group)		0.223	0.190	-
Total eye sign score		20.51±5.79	21.35±6.41	19.00±6.99
95% CI		[18.89 – 22.13]	[19.28 – 23.42]	[16.54 – 21.46]
P (comparison with control group)		0.297	0.262	-

Table 5. Association between eye sign and capillaroscopy findings in SSc and other CTDs

Capillaroscopy changes		SSc group (N=49)		Other CTDs (N=37)	
		Mean ± SD of Total Eye Score	P	Mean ± SD of Total Eye Score	P
Whole finding pattern	Normal	-	0.989	-	0.082
	Nonspecific abnormalities	20.35±4.58		20.43±6.01	
	SSc pattern	20.31±6.34	0.846	25.00±6.42	0.216
	SSc pattern	20.00±10.80		25.00±7.07	
	Early	-	-	-	
	Late	20.35±5.76		25.00±6.32	
	Active	20.30±4.99	0.904	20.80±6.56	0.175
Morphology	Abnormal	20.35±7.45		23.88±5.46	
Morphology range	<33% of total capillaries	23.57±7.48	0.128	23.33±6.05	0.726
	33-66% of total capillaries	20.00±7.07		25.00±7.07	
	More than 66% of total capillaries	13.33±2.88		-	
Dimension	Normal	20.00±0.00	0.637	-	0.082
	Dilation	20.75±4.94		20.43±6.01	
	Giant loop	-		-	
	Dilation and Giant Loop	19.79±6.67		25.00±6.23	
Mean capillary score	Good density (≥7)	20.00±4.74	0.152	20.74±6.30	0.213
	Reduced density (4-7)	20.68±5.83		26.00±6.51	
	Very low density (<4)	12.50±3.53		22.50±3.53	
Hemorrhages	Absent	20.31±4.64	0.905	20.31±6.27	0.281
	Present	20.50±6.34		22.38±6.44	

Table 6. Association between the eye sign Score and clinical manifestations in SSc and other CTDs

SSc group (N=49)		
Clinical manifestation	Mean ± SD of total eye score	P
Dysphagia	21.53±7.18	0.900
Interstitial Lung diseases	20.50±3.68	0.819
Pulmonary hypertension	17.50±5.24	0.286
Facial or palmar telangiectasia	19.68±5.81	0.175
Skin score	0.212	0.182
Other CTDs group (N=37)		
Clinical manifestation	Mean ± SD of Total Eye Score	P
Arthritis	25.00±5.00	0.266
Arthralgia	22.50±6.58	0.290
Gottron sign	23.33±5.77	0.564
Periorbital edema	18.75±8.53	0.421
Periungual erythema	21.00±7.41	0.928
Mechanic's Hands	20.00±7.07	0.801
Puffy Hands	20.90±7.68	0.822
Morning stiffness	24.00±0.00	0.571
Dry mouth	21.25±5.27	0.658
Dry Eye	18.00±2.73	0.243
Heart burn	20.35±7.95	0.323
Dysphagia	20.00±10.00	0.900
Facial or palmar telangiectasia	21.50±5.79	0.905

Discussion

This study aimed to investigate the differences in ocular signs among patients with SSc, other CTDs, and the normal population, as well as to identify any associations between ocular signs and capillaroscopy changes in patients with scleroderma and other CTDs who presented with RP.

While the original design included three distinct groups (SSc, other CTDs, and healthy controls), the primary objective was to determine whether the ocular symptom could differentiate patients from healthy individuals. Accordingly, we performed a pooled analysis of all patients versus controls to directly address this diagnostic question. Subgroup comparisons were conducted within an exploratory framework to investigate potential heterogeneity across disease types. This approach balances diagnostic clarity with hypothesis-generating insights and aligns with recent recommendations for biomarker evaluation in heterogeneous autoimmune populations.

Our results did not demonstrate statistically significant differences in eye sign scores between individuals with SSc and other CTDs compared to healthy controls. However, given the limited sample size and the absence of a formal power calculation, these findings should be interpreted with caution. The lack of statistical significance does not confirm the absence of an association, and the possibility of a type II error cannot be excluded. This finding contrasts with previous research, such as the study by Yu et al. (2022), which reported that eye sign scores were higher in SSc patients compared to healthy controls, suggesting a significant burden of ocular manifestations in systemic conditions like SSc. (25)

Our results did not reveal statistically significant associations between the eye sign score and capillaroscopy variables in patients with SSc and other CTDs. A previous study examined the relationship between eye sign scores and capillaroscopy. In the study conducted by Yu et al., 60

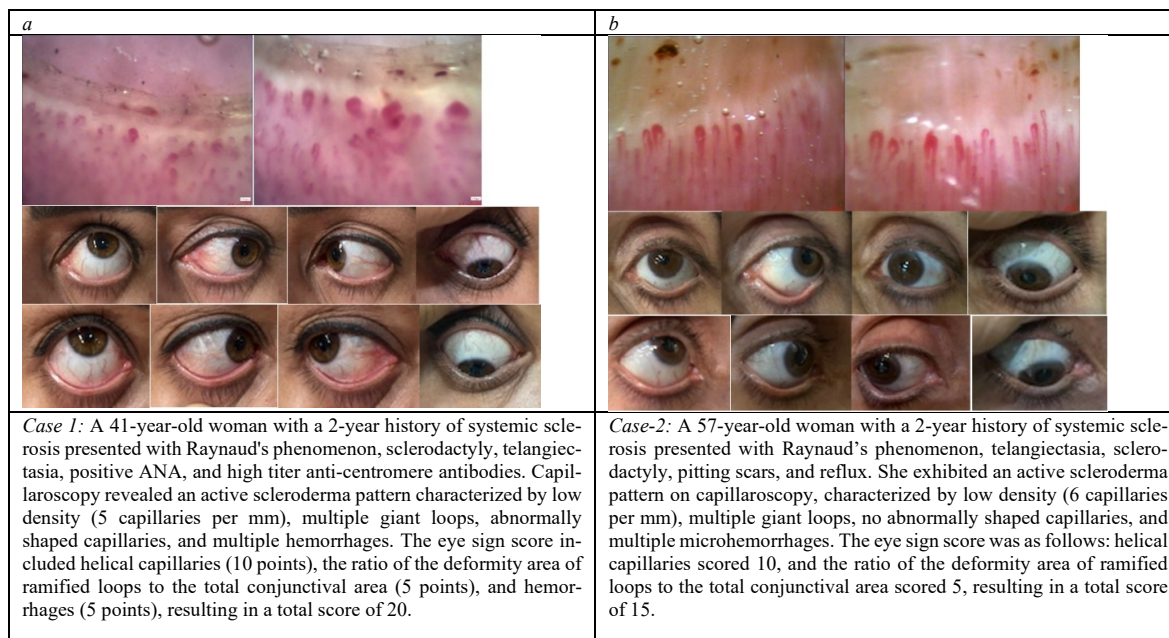


Figure 1. Illustrates capillaroscopy and the eye sign in both eyes of two patients with systemic sclerosis

SSc patients and 20 healthy individuals were enrolled. All subjects were assessed using methods of NVC and eye sign evaluation. The study found a positive linear correlation between eye sign scores and NVC severity in all patients with SSc (13). While our study included a larger overall sample of patients exhibiting a scleroderma pattern of capillaroscopy, the smaller sample size within each disease subgroup (SSc and other CTDs) may have reduced our statistical power. To strengthen these findings, future studies should be conducted with larger subgroup sizes. Furthermore, this lack of association should be interpreted cautiously due to the limited sample size and potential confounding factors.

As reported by Shi et al. (2023), the presence of eye sign in patients with neuropsychiatric lupus erythematosus has been associated with increased vascular damage (26). However, our findings did not support a similar association in patients with SSc and other CTDs.

In justifying the results obtained in the present study, it is important to consider that conjunctival microcirculation, evaluated through eye sign scores and nailfold capillary networks assessed via capillaroscopy, is influenced by various physiological mechanisms. The conjunctiva is a highly vascularized tissue that plays a crucial role in ocular surface health, while nailfold capillaries are primarily involved in peripheral circulation and are often utilized as a proxy for systemic microvascular health (27). Studies by Deng (2016) and Jiang (2014) have suggested that microvascular responses in the conjunctiva can be significantly affected by local factors such as inflammation and environmental conditions, which may not be reflected in the systemic changes observed in nailfold capillaries (28, 29). Capillaroscopy typically focuses on the morphology and density of capillaries in the nailfold, which may not provide

a comprehensive overview of conjunctival vascular dynamics (30). Studies have reported that the median apical diameter of nailfold capillaries in healthy subjects is approximately 17 μm (31), while the diameter of conjunctival capillaries ranges from approximately 8.7 to 24.3 microns, with a mean value of around 15.5 microns in healthy individuals (11). Although the naked eye can only observe the blood vessels of the scleral conjunctiva that are larger than about 0.1 millimeters in diameter, larger vessels and those congested due to inflammation are more easily visible.

Additionally, the pathophysiological processes underlying microvascular changes in systemic conditions, such as SSc, may not uniformly affect both conjunctival and nailfold capillary networks. For instance, studies by Smith et al. (2016) and Niklas et al. (2022) have demonstrated that SSc is characterized by specific microvascular alterations primarily observed in the nailfold capillaries, including capillary loss and dilatation, which may not manifest similarly in conjunctival vessels (32, 33). This indicates that while both systems are influenced by microvascular dysfunction, the nature and extent of these changes can differ significantly, resulting in a lack of correlation between conjunctival microcirculation and capillaroscopic findings.

In both groups of SSc and other CTDs, we did not observe statistically significant associations between any of the skin symptoms and the eye sign score. The conjunctiva, being a highly vascularized tissue, can exhibit changes due to local inflammatory processes or environmental factors that are independent of the systemic manifestations of SSc and other CTDs. For instance, inflammatory conditions such as episcleritis or conjunctivitis may occur in SSc patients but do not necessarily correlate with the severity or

type of skin symptoms (34). This divergence in underlying mechanisms may explain why skin symptoms do not correlate with eye sign scores, as they may reflect different aspects of the disease process.

This limitation indicates that some potentially meaningful associations may have gone undetected, and the absence of statistically significant findings should be interpreted as inconclusive rather than confirmatory. Subgroup analyses were exploratory and constrained by small sample sizes, which further increased uncertainty and limited the reliability of observed trends. Confidence intervals have been provided where relevant to reflect this limitation. Conducting a longitudinal study to evaluate changes in eye sign and capillaroscopy over time may potentially reveal dynamic associations. Future studies should incorporate formal power calculations and multivariable adjustments to better assess diagnostic utility and control for confounding.

Conclusion

The present study aimed to investigate the differences in eye signs between patients with SSc, other CTD, and the normal population, as well as to identify any association between Eye sign scores and capillaroscopy changes in patients with SSc and other CTDs presenting with Raynaud's phenomenon. Although the relationship between these two factors is biologically plausible, our study did not detect statistically significant associations. This suggests that while both eye sign and capillaroscopy changes may reflect underlying microvascular dysfunction, they do not necessarily correlate with each other, as they may involve different pathophysiologic mechanisms in these populations. However, given the limited sample size and the exploratory nature of subgroup analyses, these findings should be interpreted with caution, as the possibility of a type II error cannot be excluded. Further research is warranted to elucidate the complex interplay between ocular manifestations and systemic microvascular abnormalities in CTDs.

Acknowledgment

The authors would like to thank Shiraz University of Medical Sciences, Shiraz, Iran, and the Center for Development of Clinical Research of Namazi Hospital and Dr. Nasrin Shokrpour for editorial assistance.

Conflict of Interests

The authors declare that they have no competing interests.

Authors' Contributions:

SS: conceptualization, methodology, capillaroscopy and analysis, patients gathering, review and editing, supervision; SD: writing, data analysis, review and editing.

Ethical Considerations

Ethics approval was obtained from the Human Ethics Committee of our University of Medical Science under code number IR.SUMS.MED.REC.1403.039. Informed consent was acquired from all participants prior to their involvement in the study. This article does not include any animal studies.

Funding Support

This thesis received support from the Dean of the School of Medicine, based on the research project number 28975, and was sponsored by the Vice Chancellor of Shiraz University of Medical Sciences.

Data Availability

All data and materials of this manuscript are available from the corresponding author on reasonable request.

AI Use Statement

N/A.

References

- Smith V, Herrick A, Ingegnoli F, Damjanov N, Angelis, Denton C, et al. Standardisation of nailfold capillaroscopy for the assessment of patients with Raynaud's phenomenon and systemic sclerosis. *Autoimmun Rev.* 2020;102458.
- Velez RG, Kirkegard LR, Diaz LM. AB1574 descriptive study of capillaroscopies performed in the rheumatology service of a third level hospital. *BMJ Publishing Group Ltd;* 2023.
- Cordellat IM, Almela CM, Verdejo JI, Garcia EG, Olmos CF, et al. SAT0187 Capillaroscopy: A Useful Tool for Identifying Primary Raynaud. *Ann Rheum Dis.* 2014;73(Suppl 2):657-8.
- Lambova S. Scleroderma-like capillaroscopic pattern in SLE is not a sign of overlap syndrome in both adults and children. *Lupus Sci Med.* 2022;9.
- Chojnowski M, Felis-Giemza A, Olesińska M. Capillaroscopy – a role in modern rheumatology. *Reumatologia.* 2016;54:67-72.
- Roko P.A. Nikolic M, Maggie Larché M, PhD, MRCP (UK), Mohammed Osman M, PhD, FRCPC. Capillaroscopy in Systemic Autoimmune Rheumatic Diseases: A Clinical Tool Linking Diagnosis and Pathogenesis. *Canadian Rheumatology Today.* 2025;2(1).
- Cutolo M, Soldano S, Smith V. Pathophysiology of systemic sclerosis: current understanding and new insights. *Expert Rev Clin Immunol.* 2019;15(7):753-64.
- Yan Y, Li GX, Yuan JS. Study on mechanism of eye-signs in blood stasis syndrome. *Zhongguo Zhong Xi Yi Jie He Za Zhi.* 1996;16(4):213-5.
- Contaldo M. Oral Mucosa Capillaroscopy: A Narrative Review. *Cancers.* 2024;16(22):3774.
- Schumacher HR, Ligot PN, Barry PE. Conjunctival and nailfold microcirculation in patients with rheumatoid arthritis and normal subjects. *Acta Rheumatol Scand.* 1968;14(1-4):253-64.
- Shahidi M, Wanek J, Gaynes B, Wu T. Quantitative assessment of conjunctival microvascular circulation of the human eye. *Microvasc Res.* 2010;79 2:109-13.
- Shi J. POS0380 performance of eye sign in diagnosing patients with neuropsychiatric systemic lupus erythematosus. *BMJ Publishing Group Ltd;* 2023.
- Yu S, Ni X, Zhao J, Wu R. [Retracted] Eye Sign is an Alternative for Evaluation of the Microcirculation in Patients with Systemic Sclerosis. *Evid Based Complementary Altern Med.* 2022;2022(1):1034535.
- Ushiyama O, Ushiyama K, Yamada T, Koarada S, Tada Y, Suzuki N, et al. Retinal findings in systemic sclerosis: a comparison with nailfold capillaroscopic patterns. *Ann Rheum Dis.* 2003;62(3):204-7.
- de A. F. Gomes B, Santhiago MR, Magalhães P, Kara-Junior N, de Azevedo MNL, Moraes HV, Jr. Ocular findings in patients with systemic sclerosis. *Clinics (Sao Paulo).* 2011;66(3):379-85.
- Maverakis E, Forum P, Kronenberg DG, Chung L, Fiorentino D, Allanore Y, et al. International consensus criteria for the diagnosis of Raynaud's phenomenon. *J Autoimmun.* 2014;48-49:60-5.
- Alarcón-Segovia D, Cardiel MH. Comparison between 3 diagnostic criteria for mixed connective tissue disease. Study of 593 patients. *J Rheumatol.* 1989;16(3):328-34.
- van den Hoogen F, Khanna D, Fransen J, Johnson SR, Baron M, Tyndall A, et al. Classification criteria for systemic sclerosis: an ACR-EULAR collaborative initiative. *Arthritis Rheum.* 2013;65(11):2737.
- Hoffmann-Vold A-M, Gunnarsson R, Garen T, Midtvedt Ø, Molberg Ø. Performance of the 2013 American College of

- Rheumatology/European League Against Rheumatism Classification Criteria for Systemic Sclerosis (SSc) in large, well-defined cohorts of SSc and mixed connective tissue disease. *J Rheumatol.* 2015;42(1):60-3.
20. Mosca M, Tani C, Vagnani S, Carli L, Bombardieri S. The diagnosis and classification of undifferentiated connective tissue diseases. *J Autoimmun.* 2014;48-49:50-2.
 21. Smith V, Herrick AL, Ingegnoli F, Damjanov N, De Angelis R, Denton CP, et al. Standardisation of nailfold capillaroscopy for the assessment of patients with Raynaud's phenomenon and systemic sclerosis. *Autoimmun Rev.* 2020;19(3):102458.
 22. Ingegnoli F, Herrick AL, Schioppo T, Bartoli F, Ughi N, Pauling JD, et al. Reporting items for capillaroscopy in clinical research on musculoskeletal diseases: a systematic review and international Delphi consensus. *Rheumatology.* 2021;60(3):1410-8.
 23. Clements PJ, Lachenbruch PA, Seibold JR, Zee B, Steen VD, Brennan P, et al. Skin thickness score in systemic sclerosis: an assessment of interobserver variability in 3 independent studies. *J Rheumatol.* 1993;20(11):1892-6.
 24. Galiè N, Humbert M, Vachiery J-L, Gibbs S, Lang I, Torbicki A, et al. 2015 ESC/ERS guidelines for the diagnosis and treatment of pulmonary hypertension: the joint task force for the diagnosis and treatment of pulmonary hypertension of the European Society of Cardiology (ESC) and the European Respiratory Society (ERS): endorsed by: Association for European Paediatric and Congenital Cardiology (AEPC), International Society for Heart and Lung Transplantation (ISHLT). *Eur Heart J.* 2016;37(1):67-119.
 25. Turk M, Hayworth JL, Nevskaya T, Pope J. Ocular Manifestations in Rheumatoid Arthritis, Connective Tissue Disease, and Vasculitis: A Systematic Review and Metaanalysis. *J Rheumatol.* 2020;48(1):25-34.
 26. Shi LH, Liu Z, Yu S, Xia Q, Zhao J, Wu R. Performance of Eye Sign Combined With Increased Interleukin-6 in Cerebrospinal Fluid in Patients With Neuropsychiatric Lupus Erythematosus. *Int J Rheum.* 2023;26(8):1464-73.
 27. Shahidi M, Wanek J, Gaynes BI, Wu TH. Quantitative Assessment of Conjunctival Microvascular Circulation of the Human Eye. *Microvasc Res.* 2010;79(2):109-13.
 28. Deng Z, Wang J, Jiang H, Fadli Z, Liu C, Tan J, et al. Lid Wiper Microvascular Responses as an Indicator of Contact Lens Discomfort. *Am J Ophthalmol.* 2016;170:197-205.
 29. Jiang H, Zhong J, DeBuc DC, Tao A, Xu Z, Lam BL, et al. Functional Slit Lamp Biomicroscopy for Imaging Bulbar Conjunctival Microvasculature in Contact Lens Wearers. *Microvasc Res.* 2014;92:62-71.
 30. Lima CF, Morais IH, Suckow K, Nisihara R, Skare TL. Nailfold Capillaroscopy and Microvascular Involvement in Diabetes Mellitus. *Sci Med.* 2021;31(1):e39679.
 31. Ingegnoli F, Gualtierotti R, Lubatti C, Bertolazzi C, Gutierrez M, Boracchi P, et al. Nailfold capillary patterns in healthy subjects: a real issue in capillaroscopy. *Microvasc Res.* 2013;90:90-5.
 32. Smith V, Thevissen K, Trombetta AC, Pizzorni C, Ruaro B, Piette Y, et al. Nailfold Capillaroscopy and Clinical Applications in Systemic Sclerosis. *Microcirculation.* 2016;23(5):364-72.
 33. Niklas K, Niklas A, Mularek-Kubzdela T, Puszczewicz M, Samborski W. Relationship Between Changes Observed in Nailfold Capillaroscopy and Serological Profile, Lung Fibrosis, And Elevated Risk of Pulmonary Hypertension in Patients With Systemic Sclerosis and Mixed Connective Tissue Disease. *Advances in Dermatology and Allergology.* 2022;39(5):880-6.
 34. Gomes BdAF, Santhiago MR, Magalhães PdA, Kara-Júnior N, Azevedo MNLd, Moraes HVd. Ocular Findings in Patients With Systemic Sclerosis. *Clinics.* 2011;66(3):379-85.