

A 5-year evaluation and results of treatment of chronic locked dislocations of the shoulder joint

Ali Akbar Khorsandi, MD.¹, Morteza Nakhaei Amroodi, MD.², Maziar Khorsandi,³
Syawash Mirsaid Ghazi, MD.⁴

Department of Orthopedic and Shoulder Surgery, Shafa Yahyaian Hospital, Iran University of Medical Sciences, Tehran, Iran.

Abstract

Background: Chronic neglected dislocation of the shoulder joint can be defined as a neglected dislocation for more than a 3 week period. However, it has been shown that the negligence could range from a 24 hour period to 6 months¹. Depending on age, signs, symptoms, etiology and types of dislocation, conservative treatment or surgical intervention could be considered.

Methods: In this study, 16 patients (13 were male and 3 were female) were treated with chronic shoulder dislocations, 3 of which had bilateral dislocations. The age of this group ranged from 13-65 years with a mean age of 34 years. These patients were treated by closed or open reduction, either anterior, posterior or both approaches. Of 19 dislocations, 6 were anterior unilateral, 7 posterior unilateral, 1 anterior bilateral and 2 posterior bilateral dislocations. The mean period between dislocations and treatments was 3 months (from 4 weeks to 11 months), and the mean follow up period was 40 months (from 21 months to 5 years).

Results: This study has shown that treatment varies according to pathology. In this study the mean size of head defects was 35% and the extent of severity determined the approach. Findings at the last follow up were assessed according to Rowe and Zarins score and of the 19 shoulders assessed, 9 showed good and 10 showed excellent results. There was no recurrence of the dislocation in any patient.

Conclusion: In some selected instances, open reduction of a chronic locked neglected shoulder dislocation of a 6 months period or more in young patients is recommended. This method is, however, contraindicated in elderly patients; in such cases a shoulder prosthesis is indicated.

Keywords: locked neglected anterior or posterior dislocation, closed or open reduction, shoulder prosthesis.

Introduction

The shoulder is the most commonly dislocated major joint [1,2]. Approximately 45% of the dislocations are seen in the shoulder girdle. 84% of them are anterior glenohumeral, 1.5% posterior glenohumeral, 12% acromioclavicu-

lar and 2.5% involve the sternoclavicular joint [2].

More than 60% of posterior dislocations of the glenohumeral joint are missed at the time of initial evaluation [3- 6].

There are several potential reasons that these injuries may be missed on the initial evaluation. Patients presenting with chronic dislocations of

1. Corresponding author, Associate Professor of Orthopedic and Shoulder Surgery, Shafa Yahyaian Hospital, Iran University of Medical Sciences, Tehran, Iran. Tel:+9821 22435390 Cellphone: +98912 1124399, email: alikhorsandi@yahoo.com.

2. Assistant Professor of Orthopedic and Shoulder Surgery, Shafa Yahyaian Hospital, Iran University of Medical Sciences, Tehran, Iran.

3. Medical Student of Dundee University, UK.

4. Practitioner, Shafa Yahyaian Hospital.

the glenohumeral joint usually give a history of major trauma or a history of a convulsive episode from either an intrinsic seizure disorder or an accidental electric shock. A group of patients with alcohol and drug dependency initially had substantial pain in the shoulder joint with a reduction in the mobility of the arm. The initial shoulder discomfort often improves to tolerable levels within a few weeks of the injury; and the patient may begin to use the shoulder at waist level for daily activities with limited external rotation in chronic posterior dislocations. However, in a chronic anterior dislocations, the arm will be left in relative abduction and limited internal rotation; the patient will be unable to reach his/her mouth, but still be able to perform some daily activities. Often, this gradual recovery and pain resolution may be mistakably diagnosed as frozen shoulder, and the correct diagnosis might be missed, as shown by Rowe and Zarins in a report of seven patients with chronic untreated shoulder dislocation in 1982 [2]. This creates difficulty in diagnosing chronic dislocation of the glenohumeral joint for an inexperienced surgeon. In this study we present a series of 19 neglected locked shoulder dislocations in 16 patients and the results of their treatments.

Methods

From 2001 to 2006, 16 patients (3 bilateral and 13 unilateral) were treated with chronic neglected locked shoulder dislocations. 13 patients were male and 3 female. Of 19 dislocations, 6 were anterior unilateral, 7 posterior unilateral, 1 anterior bilateral and 2 posterior bilateral dislocations. The mean age was 34 years (ranging from 13 to 65 years). The first patient was diagnosed within 2 weeks of staying in the hospital, 5 patients within 6-12 weeks, 8 patients within 13-26 weeks, and 2 cases within 40-44 weeks after the initial injury. Only 11 of the patients had been correctly diagnosed with chronic locked shoulder dislocations, while 5 patients (2 of which had bilateral dislocations)

underwent some other form of treatment due to misdiagnosis. Physiotherapy was the treatment of choice for the ones wrongly diagnosed, usually with frozen shoulder. The chief complaints of these patients were difficulties in daily activities (eating, washing the face, combing hair, etc.). Some patients had limited external rotation of the shoulder and pain, which are usually associated with posterior dislocation. On the other hand, some others had limited internal rotation of the shoulder and pain; such symptoms are usually associated with anterior dislocation. Therefore, in the majority of patients, the primary reason for referral was functional disability. There were certain pertinent clues that pointed towards the correct diagnosis, especially asymmetry of the shoulders, the absence of humeral head prominency, the presence of the humeral head hidden under the acromion process and some range of motion limitation.

In cases with locked posterior dislocations, the average forward flexion was 90°, internal rotation to L5, with no external rotation. The patients kept their forearm against their chest somewhat comfortably. However, in cases with locked anterior dislocations the average forward flexion was 100°, external rotation 60°, with no internal rotation, and eating was not easily possible.

In addition to taking history and physical examination, we used plain x-rays in AP, axillary lateral and true lateral scapular views and C.T. scans [8] to elicit the changes in the humeral head [9] and the glenoid fossa. Of the 16 patients studied, only a shoulder of one of the patients had an associated fracture of the proximal humerus in the surgical neck, which was also accompanied with locked neglected posterior dislocations.

The type of treatment for each patient was selected according to the duration of the dislocation, bone stock, the patient's age, general health, mental status, the severity of the pain, the limitation of the range of motion and the neurovascular status.

Treatment options were closed reduction (A), open reduction (B), and hemiarthroplasty (C).

A: Closed reduction under general anaesthesia was tried in one patient with bilateral posterior dislocation. She was a 65 year old woman with a long standing high blood pressure who suffered from a seizure due to hyponatremia as a result of the overuse of diuretics two weeks prior to the diagnosis of the shoulder dislocation. Reductions were carried out according to the Milch manoeuvre; traction on the affected extremity and direct pressure was applied from behind to push the humeral head anteriorly into the socket. Both shoulder reductions were stabilized using temporary percutaneous k-wires inserted under image intensifier control, followed by shoulder immobilization on both sides using 20 degree external rotation braces. Pins were removed after 3 weeks and physiotherapy was commenced.

B: 14 patients (2 patients with bilateral dislocations) were treated by open reduction. 8 of the shoulders were treated by the anterior approach as they had suffered anterior dislocations, 5 shoulders were treated by the posterior approach and both approaches were used to treat 3 difficult posterior dislocations. All the 14 patients have had dislocations since 2-11 months ago, and all were young (mean age 32.2 years old).

All patients underwent general anesthesia and were put in the beach chair position for the operation. The anterior approach was carried out with the deltopectoral incision, followed by carefully elevating the attachment of the tendon of the subscapularis muscle and the capsule to expose the glenoid fossa by inserting the Fukuda retractor. The posterior approach was carried out by skin incision and deltoid splitting on a line 2/3 anterior and 1/3 posterior to the deltoid muscle. Following the elevation of the attachment of the infraspinatus and the teres minor muscles and the capsule, the glenoid fossa was exposed by inserting the Fukuda retractor. In 12

of the patients due to the tightness of the surrounding structures imposed especially by the anterior and the posterior capsule in long standing dislocations, it was necessary to release the anterior and the posterior capsule in the posterior and the anterior approaches respectively.

In this study neither bone grafting for the Hill Sachs lesions nor the Neer modification of the McLaughlin procedure (the transfer of the subscapularis tendon with lesser tuberosity to Hill Sachs lesions) were used.

In all these patients, the anterior and the posterior capsular shifts were used for the anterior and the posterior approaches respectively (the Neer technique [10]). Bankart lesion was found and was repaired by transosseous sutures in six patients (one of which had bilateral lesions) with anterior dislocations. In four patients (one of which had bilateral dislocation), with 3 posterior and 2 anterior dislocations, it was necessary to maintain the reduction by temporary k-wires which were removed 3 weeks after the operations. Post-operatively, for the anterior locked dislocations, only the arm sling was used, whereas for the posterior locked dislocations the external sitting brace was used for 4-6 weeks in accordance with the protocol.

C: Hemiarthroplasty (modular offset type of Bigliani prosthesis [11]) was used on only one of the patients, a 55 years old man with a locked posterior dislocation and an accompanying comminuted fracture of the proximal humerus at the surgical neck since 10 months prior to the operation.

He had been treated primarily for the fracture on the surgical neck. However, his fracture had healed in a good position when he was further referred for the hemiarthroplasty.

The patients were followed up for a mean period of 40 months (ranging from 21 months to 5 years). The follow up included interview and physical examination as well as radiography of the affected shoulder.

For all the patients, after mobilization of the affected shoulder, self assisted exercises of the

Neer protocol [10] and subsequently physiotherapy were recommended (TENS, U.S, hot pack, icepack, functional faradic, active and passive mobilization) under strict supervision.

Results

The patients were assessed according to Rowe and Zarins scoring system [2] which is classified as follows:

Excellent (90-100 units of 100): Patients in this category have no pain; 100% normal shoulder motion; able to perform daily activities and even sports, adequate strength in lifting, pushing and throwing; with no shoulder instability.

Good (70-89 units of 100): Patients in this category have mild discomfort, though they are on no medications; they are capable of elevation, internal or external rotation of up to 75%; mild to-moderate limitation in daily activities and sports; with no shoulder instability.

Fair (50-69 units of 100): The patients in this category have moderate disabling pain, hence they are on occasional medications; they are capable of elevation, lacking internal or external rotation of up to 50%; moderate limitation in overhead activities and lifting; unable to throw; mild-to-moderate apprehension of the arm in extended position.

Poor (<50 of 100): constant disabling pain, therefore constant medications; can barely reach the face; no rotation; unable to use arm in gainful activities; recurrent subluxation or dislocations.

Considering the classification above the results of this study were as follows:

A: Closed reduction and pinning were used for only one patient with bilateral posterior dislocation of two weeks duration. At 3 years follow up both shoulders were stable and painless with full range of motion and normal functionality (excellent result).

B: Of the 14 patients (two with bilateral dislocations) treated with open reduction, eight of the shoulders had excellent and eight of them had good results at the mean follow up of 43

months (Fig. 1).

C: Only one patient with posterior dislocation underwent hemiarthroplasty. His operation showed good results at two years follow up.

There was no recurrence of the dislocation in any patient.

Discussion

The incidence of posterior dislocation is rare in comparison to anterior dislocation [12]. This may possibly be due to some features of shoulder anatomy. The scapula is angulated anteriorly at approximately 45° on the thoracic cage. This places the posterior half of the glenoid fossa behind the humeral head and acts as a buttress to prevent posterior dislocations. The acromion as well as the spine of the scapula also provides resistance. In addition the strong pectoralis major muscle reduces the impact of anterior blows on the glenohumeral articulation [12].

The majority of posterior shoulder dislocations are due to indirect forces caused by accidents such as an electrical shock, events such as seizures and more recently in cases of drug abuse patients where there is a sudden simultaneous spasm of the musculature around the shoulder joint and the strong internal rotators overpower the weak external rotators. The combined strength of latissimus dorsi, pectoralis major and subscapularis muscles simply overpower the infraspinatus and teres minor muscles. Other factors such as position of the arm and muscle weakness must also be considered.

Anterior and posterior dislocations of the shoulder often go undiagnosed. However, it is worth mentioning that despite the rare presentation, posterior shoulder dislocation is the most commonly missed major joint dislocation in the body. Since the AP x-ray may appear deceptively normal, inadequate physical examination may lead to a missed diagnosis of the dislocation [13].

According to Apley [14], a history of seizure,

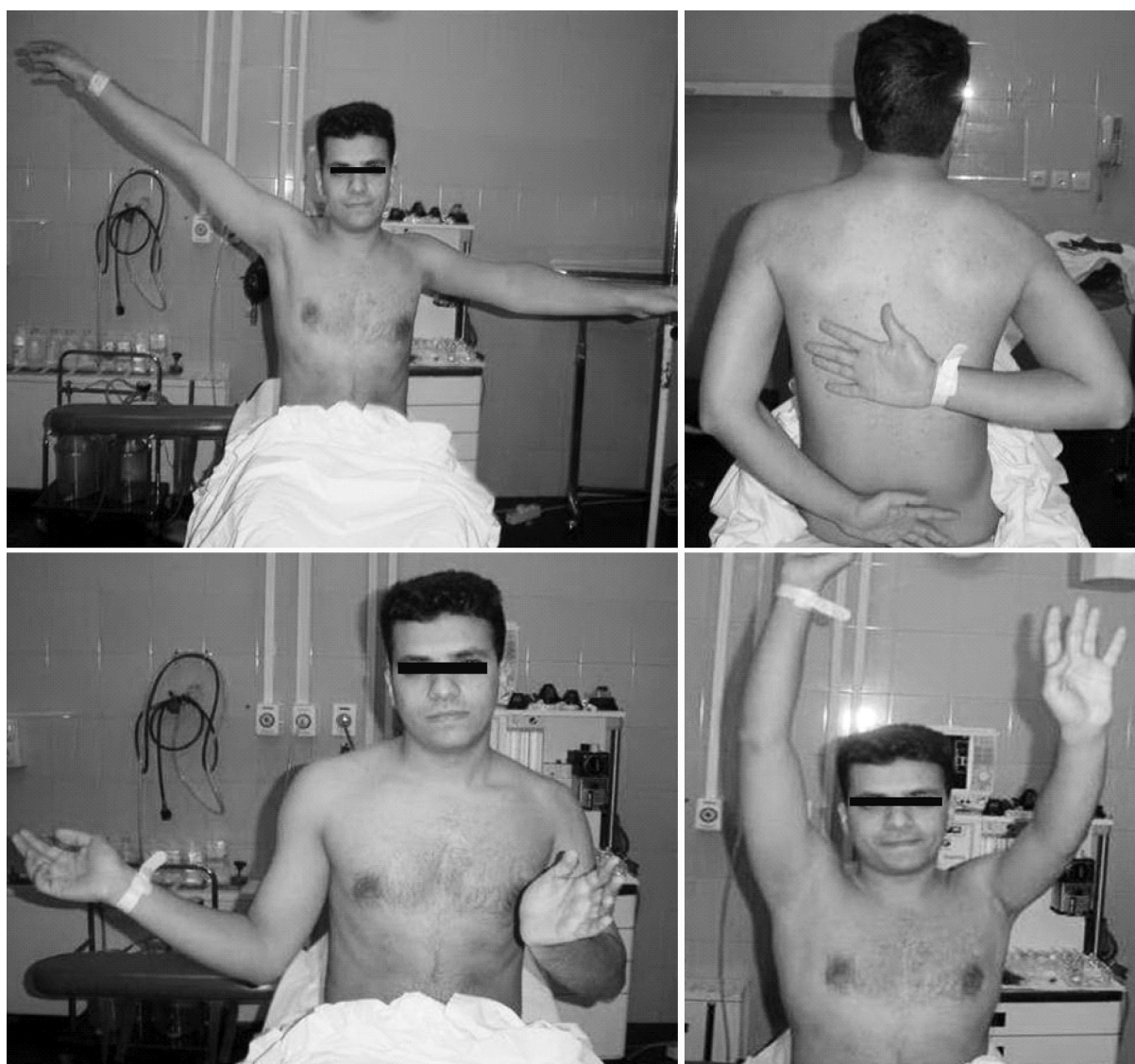

Fig 1. A 27 year old man with neglected posterior dislocation of the left shoulder since 8 months ago was treated with open reduction and temporary K-wire fixation.

electrical shock or trauma, with painful and limited external rotation of the shoulder indicates a posterior dislocation.

In this study there was only one patient with a unilateral shoulder dislocation associated with fracture of the proximal humerus. However, Stableforth and Sarangi [8] had 50% and Hawkins et al [10] had 49.9% incidences of proximal humerus fractures in their posterior dislocations. Since there was only one case of shoulder dislocation with an associated fracture of the proximal humerus in this study, it is strongly recommended that in every case of

proximal humerus fracture, the possibility of a posterior dislocation should be investigated.

Since the time McLaughlin described his operative procedures for locked neglected dislocations in 1952 [14], many articles have been published which recommend a variety of treatments, these range from conservative treatments to different kinds of surgical treatments.

The treatment plan is based on the general condition and needs of the patient, the duration of the dislocations, size of impression defects, general health from point of physical and mental status, patient's age, disability, demand, neu-

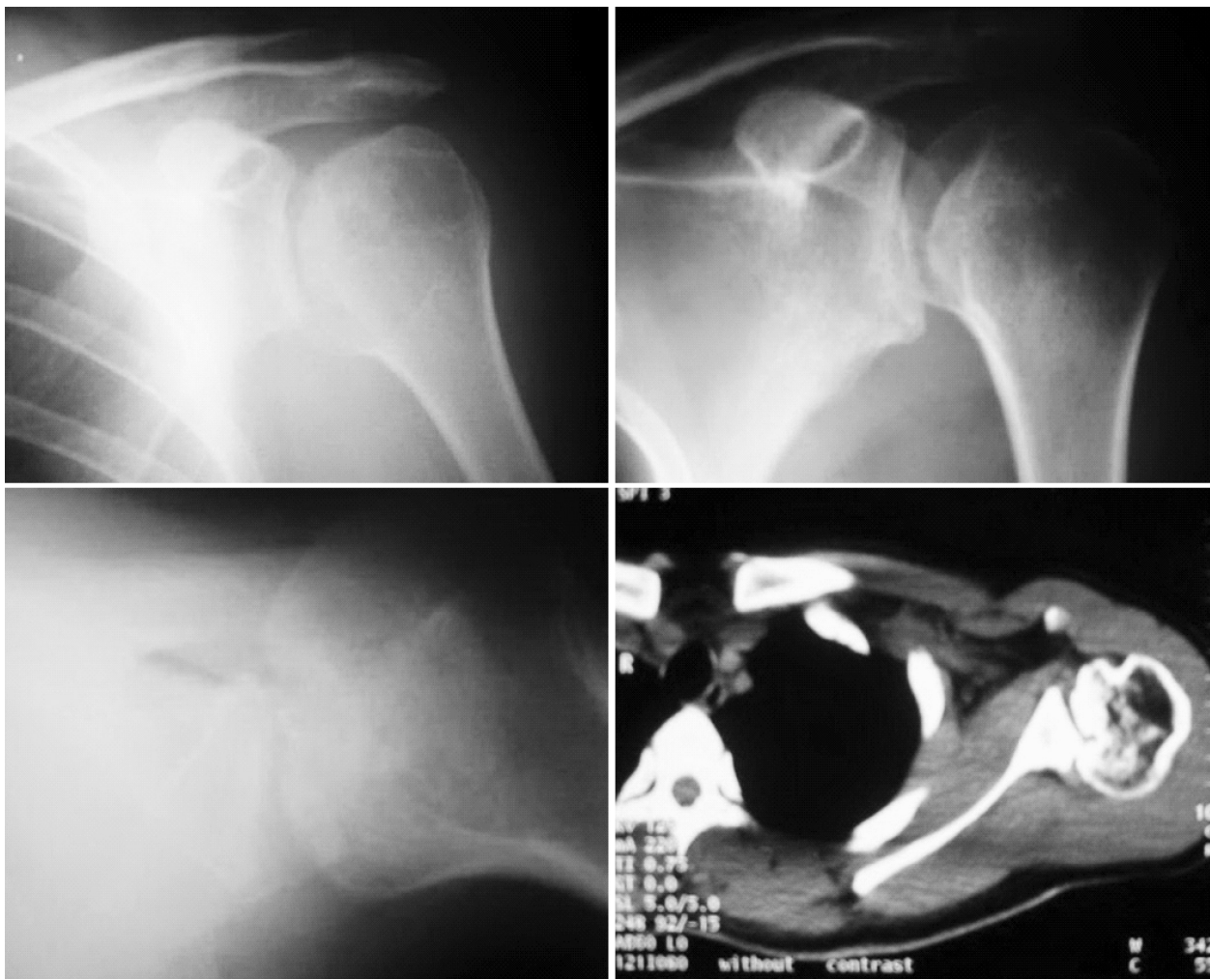

Fig 1. (cont.) Preoperative x-rays and CT-scans.

rovascular status, pain, shoulder range of motion and bone stock.

After several years, untreated patients may have a functional shoulder value of between 60%-85% of normal; this is comparable to the function obtained with a good shoulder fusion [15].

In this study successful closed reduction and temporary percutaneous pin fixation was carried out in one patient with bilateral posterior dislocations, which accompanied a head defect of about 30%. It is worth mentioning that this patient's shoulder dislocations were diagnosed two weeks after they occurred.

For all other patients with posterior dislocations (9 patients) open reduction with pin fixation was carried out and postoperatively their

shoulders were immobilized in 20° external rotation braces for 4 weeks with arms at the sides. The result was excellent after 3 years of follow up.

14 patients (two with bilateral dislocations) were treated by open reduction either through the anterior approach for anterior dislocations for five patients with unilateral dislocations, through the posterior approach for posterior dislocations for five patients with unilateral dislocations or through both approaches for four patients with difficult unilateral posterior dislocations. For the four patients with difficult unilateral posterior dislocations, it was necessary to maintain the reduction by temporary k-wires which were removed after three weeks. Postoperatively, for anterior locked dislocations,

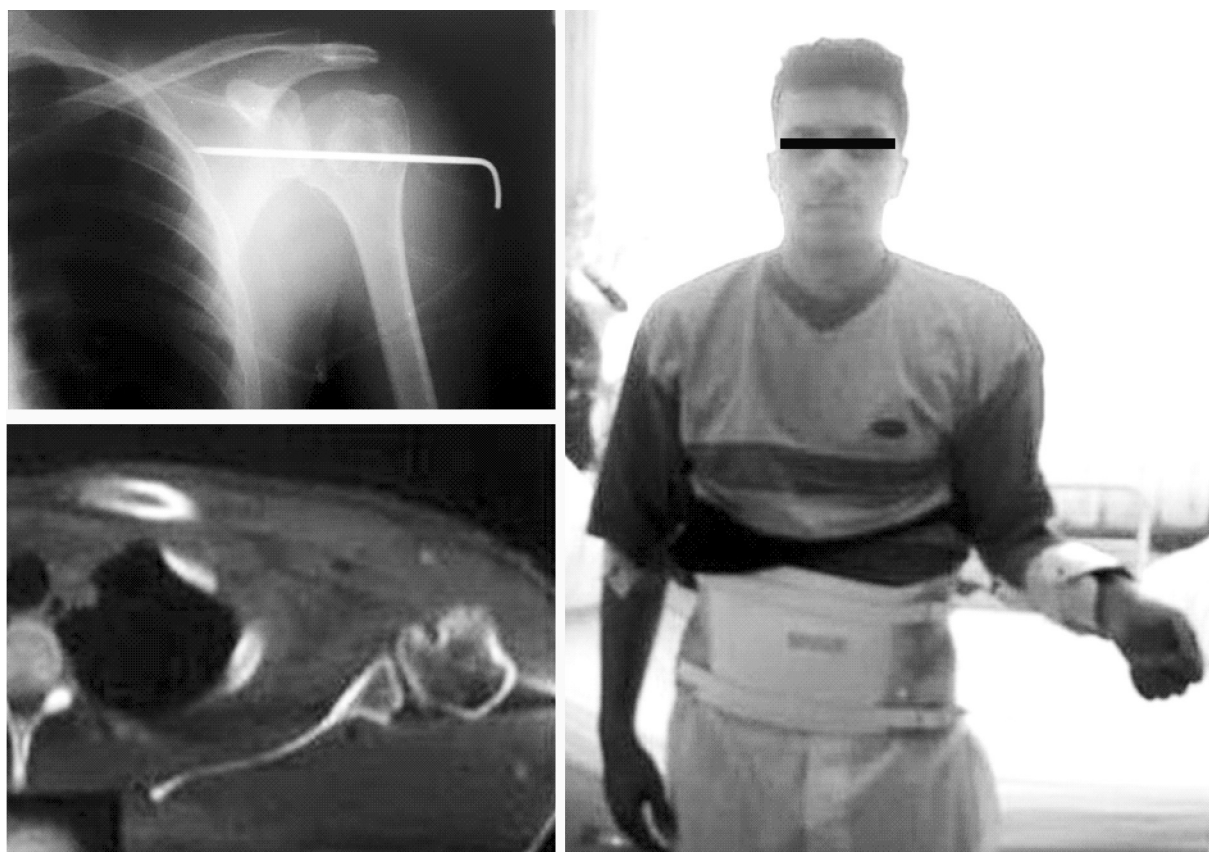


Fig 1. (cont.) Postoperative x-ray, CT-scans and postoperative immobilization brace.

only arm slings were used, but for posterior locked dislocations an external sitting brace was used for 4-6 weeks in accordance with the protocol. In these patients 50% (7 patients, one with bilateral dislocation) had excellent and 50% (7 patients, one with bilateral dislocation) had good results at a mean follow up of 43 months. One 55 year old patient with a posterior shoulder dislocation which occurred 10 months prior to the diagnosis of the dislocation was treated with hemiarthroplasty and his outcome after 2 years was good.

Conclusion

In conclusion this study has shown that due to good and excellent results with open reduction there will be no need for any reconstructive surgeries such as bone grafting or McLaughlin procedure for locked chronic neglected shoulder dislocation. In addition, open reduction may also be recommended for neglected shoul-

der dislocations of more than 6 months in young patients. This study has also demonstrated that exercise and physiotherapy under strict supervision was an important factor in the prognosis of the patients. However, older patients or some of the patients who are diagnosed at a very late stage may need hemiarthroplasty.

Aparicio et al [16] reported seven missed traumatic posterior dislocations of the shoulder in six patients. Four of five shoulders presented a defect in the humeral head involving 20%-25% of the articular surface. Two shoulders dislocated for more than 6 months were treated according to McLaughlin's technique modified by Hawkins. At a minimum follow-up of 2 years and 2 months, the functional results according to Hawkins were good in all seven shoulders. There was no recurrence of the dislocation in any patient.

El Shewy et al [17] reported 17 patients with unreduced neglected posterior shoulder dislo-

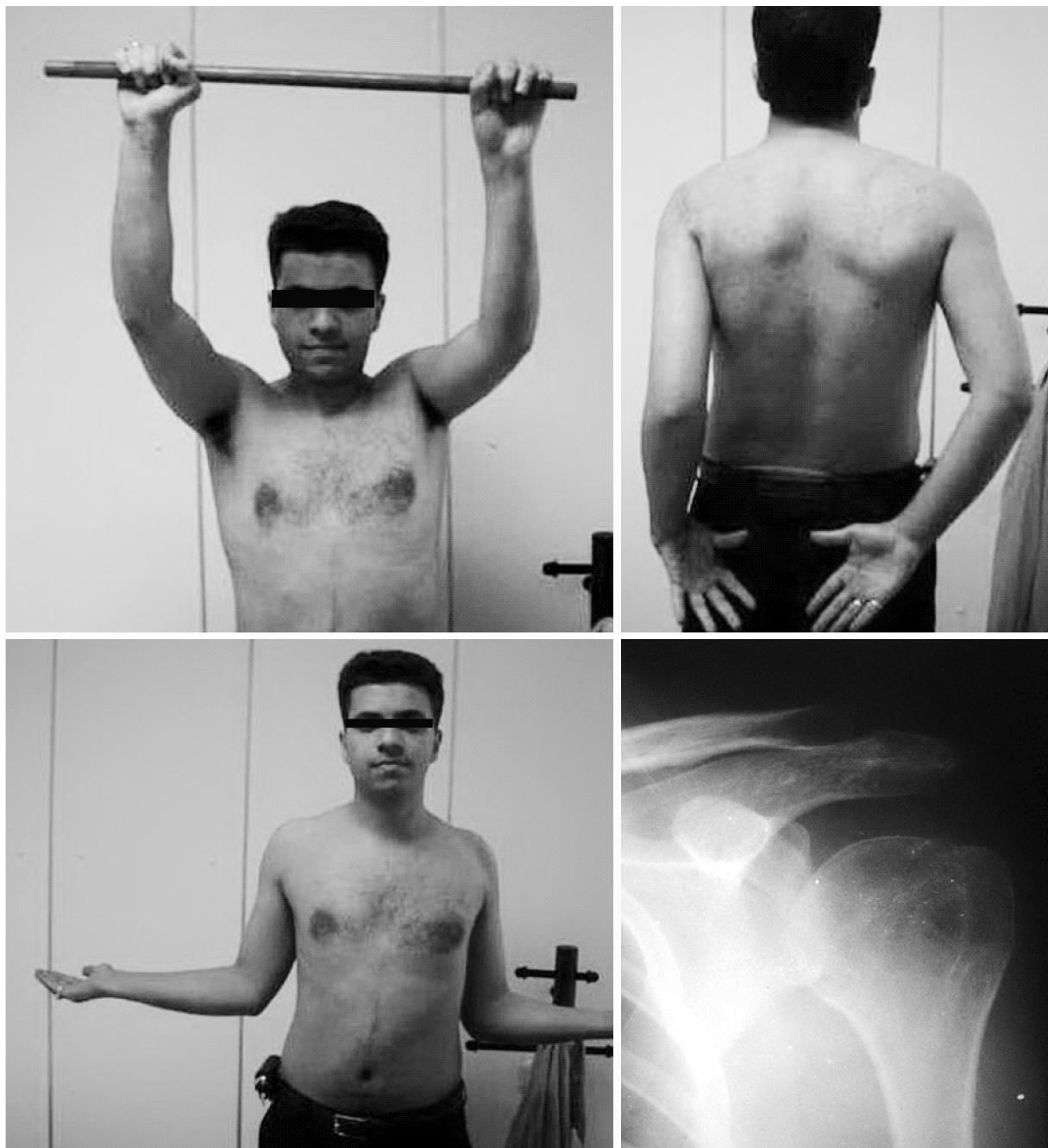

Fig 1. (cont.) D. Range of motion and x-ray 2 months post operation.

cation with an impression fracture involving less than 25% of the humeral head who were treated by open reduction together with posterior cruciate capsular repair (shift) as described by Neer. After a minimum follow-up of 5 years (range, 5–10 years), the average UCLA score improved from 18 preoperatively to 33 postoperatively. They concluded that open reduction with posterior cruciate capsular repair offers a

good solution for the problem of neglected unreduced posterior shoulder dislocation excluding cases with osteoarthritic changes and those with impression fracture involving less than 25% of the head.

Mean articular defect in our cases was 35%. We did not use any reconstructive procedure (Mc Laughlin's or capsular shift etc.). However, we did not have any recurrence of the dislo-

cations in any patient. The mean follow up period was 40 months (from 21 months to 5 years) whereas 8 of our 14 patients were treated at a time more than 6 months after dislocations. So, it seems that our results were acceptable.

dislocations of the shoulder. *J Orthop Sci* 2000; 5(1):37-42.

17. El Shewy MT, et al. Open reduction and posterior capsular shift for cases of neglected unreduced posterior shoulder dislocation. *The American Journal of Sports Medicine* 2008; 36:133-136.

References

1. Iannotti Joseph P, Williams JR, Gerald R. Disorders of the shoulder. NY: Lippincott, Williams and Wilkins. 2007; pp.1:462.
2. Rowe C, Zarins B. Chronic unreduced posterior dislocation of the shoulder, *J Bone Joint Surg Am* 1982; 64:495-505.
3. Eiji Itoi, et al. Immobilization in external rotation after shoulder dislocation reduces the risk of recurrence: a randomized controlled trial. *J Bone Joint Surg Am Oct* 2007; 89: 2124–2131.
4. Goga IE. Chronic shoulder dislocation. *J Shoulder Elbow Surg* 2003;12:446-450.
5. Hawkins RJ, Neer CS II, Pinata RM, Mendsa FX. Locked posterior dislocation of the shoulder. *J Bone Joint Surg Am* 1987; 69:9-18.
6. Hersche O, Gerber C. Iatrogenic displacement of fracture dislocations of the shoulder. A report of seven cases. *J Bone Joint Surg Br* 1994;76:30-33.
7. Thakker TH, Prabhakar MM, Patel DA. Posterior dislocation of shoulder joint. *Indian J Orthop* 2006; 40: 24-8 [serial online] 2006 [cited 2008 mar 28]; 40:24-8 Available.
8. Ivokovic A, Boric I, Cicak N. One stage operation for locked bilateral posterior dislocation of the shoulder. *J Bone Joint Surg Br* 2007;89-B:825-8.
9. Cicak N. Posterior dislocation of the shoulder. *J Bone Joint Surg Br* 2004; 86-B:324-32.
10. Neer CS II. Shoulder reconstruction, Philadelphia, WB Saunders Company, 1990; 320-325.
11. Louis U Bigliani, Even L Flatow. Shoulder arthroplasty. Williams and Wilkins, 2005; 23.
12. Cave E, Burke JF, Boyd RJ. Trauma management. Chicago: Year Book Medical Publishers, 1974.
13. Kessel L. Clinical disorders of the shoulder. First ed, Churchill Livingstone, Edinburgh. 1982;150-165.
14. Apley G. Apley's system of orthopaedics and fracture, 7 ed, Solomon, Butterworth and co, 1993;572.
15. Warner Jon JP, Iannotti Joseph P, Gerber Christian. Shoulder surgery, Lippincott-Raven, 1997;100.
16. Aparicio G. et al. Neglected traumatic posterior