

Original Articles

LAPAROSCOPIC DIAGNOSIS OF CRYPTORCHIDISM AND LAPAROSCOPIC ORCHIOPEXY: THE FIRST REPORT FROM THE MIDDLE EAST

N. SIMFOROOSH, M.D.*

*From the Department of Urology, Shahid Labbafi-Nejad Medical Center, Shahid Beheshti University of
Medical Sciences, Tehran, Islamic Republic of Iran.*

ABSTRACT

Laparoscopic orchiopexy (LO) was used in place of open surgery in 10 patients for diagnosing cryptorchidism in our department. In this method a large abdominal incision was not given in search of intra-abdominal testes. Anorchia was diagnosed in four patients, which was shown to be bilateral in one. In one subject with ambiguous genitalia, revealing the presence of intra-abdominal gonads established the infant's gender as male. In four patients, five laparoscopic orchiopexies were performed without celiotomy for the first time in Iran and the middle east which was bilateral in one patient.

Except for two patients, all procedures were performed on an outpatient basis.

Today laparoscopy is the method of choice for diagnosing cryptorchidism. Our report has shown that orchiopexy can be performed for intra-abdominal testes without submitting to open surgical techniques.

MJIRI, Vol. 12, No. 2, 101-104, 1998.

INTRODUCTION

Various methods exist for evaluating the presence or absence of cryptorchidism, but unfortunately most are often unsuccessful in this regard.^{1,3}

Laparoscopy is the procedure of choice for diagnosing the presence and/or the position of cryptorchid testes today.^{4,5} Different methods have been used in the past for treating such patients. Some involve extensive dissection

of the testicular vessels up to the kidney, which is nevertheless inadequate due to the limited incision. The two-stage method,⁶ the Fowler-Stephens method,⁷ autotransplantation,⁸ and finally orchiectomy have all been applied for the treatment of cryptorchidism. Each of the above methods has advantages and disadvantages. With the increasing popularity of laparoscopic surgery, which is new compared to diagnostic laparoscopy, today the Fowler-Stephens two-stage method⁹ and one-stage orchiopexy¹⁰ are used and reported as less invasive procedures. Taking our five cases into consideration, there have been less than 20 laparoscopic orchiopexies

*Professor of Urology, Shahid Beheshti University of Medical Sciences.

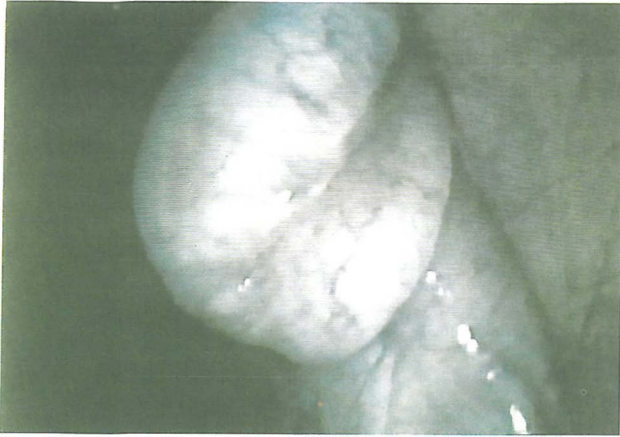

Fig. 1. A cryptorchid testis present at the internal inguinal ring within the abdomen of a child which was easily diagnosed laparoscopically.

reported throughout the world to date.

PATIENTS AND METHODS

Diagnostic laparoscopy was performed for the first time in Iran for diagnosing cryptorchidism on March 3, 1993. Since then, laparoscopy has been used in 10 patients with empty scrotums and non-palpable testes in the inguinal canal in order to evaluate the presence or absence of intra-abdominal testes.

The mean age of the patients was 9.8 years. Four patients were shown to be anorchid, one of them bilaterally. In one patient with ambiguous genitalia, an intra-abdominal gonad was observed via laparoscopy. Open biopsy revealed the presence of testicular tissue in the gonad and thus identified the infant's gender as male. In two patients, after laparoscopically diagnosing cryptorchidism, open orchiopexy was performed. One of these subjects had previously undergone open surgery for diagnostic purposes, but no testes had been found. On July 3, 1993, orchiopexy was performed via the laparoscope for the first time, and all orchiopexies have been done in a similar manner ever since. A total number of five orchiopexies have been accomplished laparoscopically in four patients without celiotomy. In the patient who underwent bilateral orchiopexy, the one-stage Fowler-Stephens procedure was performed laparoscopically on one side due to shortness of the vessels (the testis was present beneath the colon and below the inferior border of the kidney).

Operative technique

Following abdominal penetration via an 11 mm trocar—according to standard principles—CO₂ was insufflated up to 10-13 mmHg pressure. After observing the testis (Figs. 1, 2a), the other two trocars (5 and 11 mm, respectively,

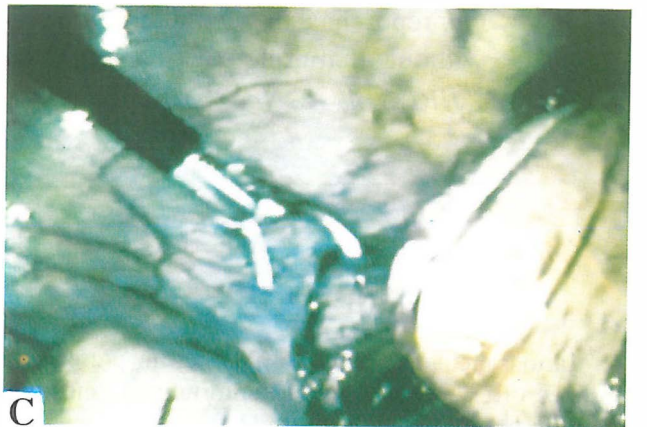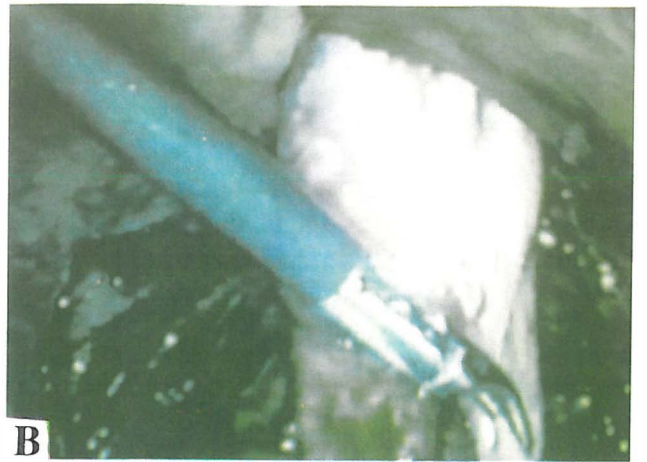

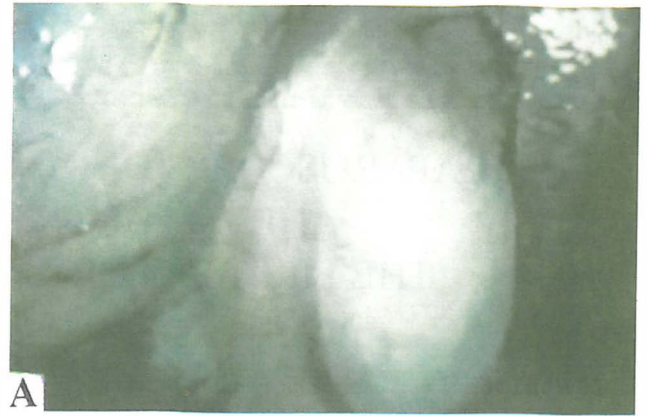
Fig. 2. a. Laparoscopic view of an intra-abdominal testis, showing the vas deferens entering the testis medially. b. The gubernaculum of the testis has been transected, the vas deferens freed, and the testis slowly being prepared for extraction. c. The spermatic vessels and vas deferens have been dissected completely and are shown while being pulled through the inguinal canal. The testis is no longer present within the abdomen and cannot be seen anymore with the laparoscope.

positioned bilaterally on the lower abdomen one-half the distance from the umbilicus to the anterior superior iliac spine) were inserted. Surgical instruments were introduced via these trocars and the spermatic vessels were dissected free after dividing the overlying parietal peritoneum. Following dissection of the spermatic vessels, the peritoneum covering the testis was freed with diathermy scissors. The gubernaculum was divided at the lower pole of the testis (Fig. 2b). At this stage a small incision was made on the scrotum and a hemostat was introduced into the abdominal cavity after dilating the inguinal canal with Hegar dilators and, under direct visualization, the terminal portion of the testis was grasped and traction applied toward the scrotum. During this stage it would often be necessary to dissect and free the vas deferens from intra-abdominal adhesions.

The testis was thus extracted from within the abdomen. Blood supply and perfusion of the testis was evaluated (i.e., pricking the superficial vessels of the tunica vaginalis resulted in brisk bleeding), thus confirming the patency of the spermatic vessels. Afterwards the testis was fixed in a Dartos pouch inside the scrotum (Figs. 2c, 3).

Intra-abdominal CO₂ was evacuated, and the resultant trocar incisions closed via a subcuticular suture. The mean time required for diagnostic laparoscopy was 35 minutes. The mean time required for laparoscopic orchiopexy was two and a half hours which is expected to gradually decrease.

RESULTS

All diagnostic laparoscopies were performed on an outpatient basis, and patients were discharged after becoming fully alert and conscious and returned to work after two days. In the LO group, two patients were admitted for 2 days while the others were managed outpatiently.

No patient required open surgery. One patient required blood transfusion due to a retroperitoneal hematoma, which was managed non-operatively and the patient was discharged in good health. In all cases of LO, the testes were easily placed within the scrotum.

DISCUSSION

Nearly 20% of patients with empty scrotums also have non-palpable testes within the inguinal canal upon examination.¹¹ In such cases sonography, CAT scanning, and even angiography, venography and herniography have been used in order to evaluate the presence or absence of intra-abdominal testes.¹¹ Nevertheless, these methods were often unsuccessful and neither were comparable to laparoscopy. We experienced the greater




Fig. 3. Laparoscopically mobilized testis is shown outside the abdomen.

diagnostic value of laparoscopy upon performing this procedure in 10 patients, i.e., the presence or absence of intra-abdominal testes was evaluated in less than 10 minutes via a less than 1 cm infra-umbilical incision, and a large incision and/or extending the incision and entering the peritoneum in search of testes was totally unnecessary. The superiority of this modality is unequivocally apparent and it is the procedure of choice for the diagnosis of cryptorchidism.

The traditional method of treatment for intra-abdominal testes is abdominal exploration, often requiring a large incision. If the testis was located at a very high level, many would perform orchiectomy, a method condemned by the author. Others would propose the two-stage method or the one or two-stage spermatic vessel transection procedure (Fowler Stephens). We successfully performed the one-stage Fowler procedure in one patient and the testis was placed intra-scrotally without open surgery.

Laparoscopy has been applied for the surgical treatment of cryptorchidism by two different methods:

When the testis is present at a very high level, the spermatic vessels are ligated with clips and orchiopexy is performed six months later. In this method, contrary to the Fowler-Stephens procedure, there is no danger of harming the vasculature of the vas deferens and the risk of testicular atrophy is decreased. But, if the testis is located near the inguinal canal, orchiopexy can be performed at the same time (one-stage procedure). Wilter et al. were the first to report the successful performance of laparoscopic orchiopexy in eight patients.¹¹ With this method, the spermatic vessels and vas deferens are dissected free of the parietal peritoneum, the gubernaculum is transected and the testis is transferred into the scrotum. We used this method in our patients. If the testis cannot be adequately brought down, a small incision can be given on the inguinal canal, and the adequately mobilized testis grasped

Laparoscopic Orchiopexy

and fixated in the Dartos pouch. Even though laparoscopic orchiopexy has been successfully performed, long-term comparative follow-up studies of the results are lacking.

Nevertheless, in the case of nonpalpable testes, identification of the testis and dissection and mobilization of its vascular supply appears simpler and more successful compared to open surgery due to the 10× magnification of the laparoscope. Even in situations in which orchiopexy is to be performed with open surgery, this can be accomplished post-laparoscopically via a smaller, more well-placed incision.

In conclusion, regarding the author's experience and that of other researchers, laparoscopy appears to be the procedure of choice for the evaluation and diagnosis of undescended testes, and this modality can be used for orchiopexy of intra-abdominal testes.

REFERENCES

1. Weiss RM, et al: High resolution real time ultrasonography in the localization of the undescended testis. *J Urol* 135: 936, 1986.
2. Wolvezson MK, et al: CT in localization of impalpable cryptorchid testes. *AJR* 134: 725, 1980.
3. Kogan B, et al: Magnetic resonance imaging in genital anomalies. *J Urol* 138: 1028, 1987.
4. Lowe DH, et al: Laparoscopy for localization of nonpalpable testes. *Surg Gynec Obstet* 159: 439, 1984.
5. Manson AL, et al: Preoperative laparoscopic localization of the nonpalpable testes. *J Urol* 134: 919, 1985.
6. Steinhardt GF, et al: Orchiopexy: planned two-stage technique. *J Urol* 133: 434, 1985.
7. Stephens FD: Fowler Stephens' orchiopexy. *Sem Urol* 6: 103, 1988.
8. Silber SJ et al: Successful autotransplantation of an intraabdominal testis to the scrotum by microvascular technique. *J Urol* 115: 452, 1976.
9. Peters CA, et al: Laparoscopic management of nonpalpable testes. *J Endourol Suppl* 7: 5170, 1993.
10. Gaur DD, et al: Laparoscopic orchiopexy for the intraabdominal testis. *J Urol* 153: 479-81, 1995.
11. Stewart LH, et al: Laparoscopic removal of intraabdominal testis. *Brit J Urol* 70: 208, 1992.