

## INGUINAL HYDATID CYST: REPORT OF A RARE CASE

M.R. KOUHSARI, M.D., AND H.A. MANZAR, M.D.

*From the Department of Surgery, Razi Hospital, Guilan University of Medical Sciences, Rasht, Islamic Republic of Iran.*

### ABSTRACT

Hydatid cyst, the larval stage of *Echinococcus spp.*, is a common parasitic disease in Iran. The liver and the lungs are the most commonly involved organs. Hydatid cysts have also been reported in bones and soft tissues such as muscle, brain tissue, spleen, thyroid and even in the heart. Hydatid cyst of the inguinal area, resembling a hernia is a rarity presenting at an unusual site. A hypersensitivity reaction to components of hydatid fluid may cause a serious or even fatal reaction if cyst rupture occurs. Sudden occurrence, lack of a good clinical history, and the severity and complexity of symptoms and signs makes the diagnosis difficult. This paper reports sudden rupture of an inguinal hydatid cyst in a patient while taking a bath, resulting in severe anaphylactic shock and acute pulmonary edema, wrongly described by the patient's family as "steam suffocation". This case report emphasizes the value of a good and detailed clinical history, the need to include hydatid cyst in the list of inguinal swellings in endemic areas, and to consider hydatid cyst rupture in the differential diagnosis of sudden shock, sudden LVF, pulmonary edema and severe allergic reactions.

*MJIRI, Vol. 12, No. 2, 177-179, 1998.*

### INTRODUCTION

Human infection with echinococci has a world-wide distribution.<sup>1</sup> Although relatively uncommon in most of North America, echinococcal disease of the liver is found throughout the world, particularly in areas where sheep are raised. These areas include the Mediterranean, Australia, New Zealand and countries in the Middle East such as Iran.<sup>2</sup>

Almost every organ of the human body has been involved, including the brain, heart, spleen, biliary tract, thyroid, parotid, tongue, tooth, bone, broad ligament,

prostate, bladder, tonsil, pulmonary artery and inferior vena cava.<sup>3</sup> Our case was present in the inguinal canal.

Daughter cysts may leak from the main cyst when punctured by a biopsy needle and these may seed the peritoneal cavity. This can also occur as a result of blunt abdominal trauma.<sup>4</sup> Intraperitoneal rupture results in the showering of hydatid fluid, brood capsules and scolices into the peritoneum leading to transient peritoneal irritation.<sup>5</sup> A hypersensitivity reaction to components of hydatid fluid may cause a serious or even fatal reaction, if there is rupture of cysts.<sup>6</sup> Usually the reproductive elements survive and initiate the formation of new cysts.<sup>7</sup>

We report a case of secondary hydatid cysts resembling bilateral inguinal hernia. The left one ruptured due to blunt trauma resulting in acute hypersensitivity reaction and the right sided inguinal hydatid cyst was removed

#### Correspondence:

M.R. Kouhsari, M.D., Assistant Professor of Surgery, Razi Hospital, Rasht, I.R. Iran, 41448.

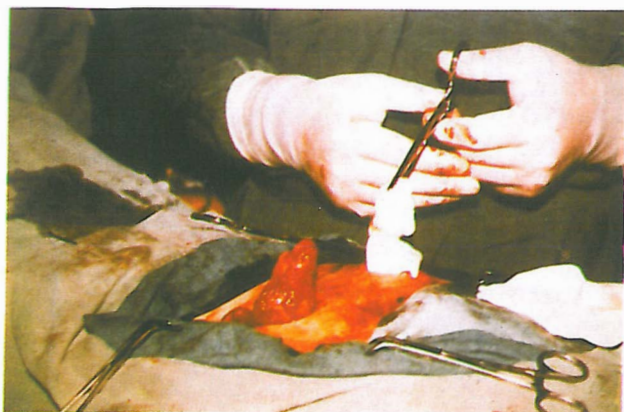


Fig. 1. Intraoperative view of the hydatid cyst.

surgically at a later date.

## Case report

In March 1989, a 31 year old young man from Manjeel was admitted to the Medical Emergency Ward of Roodbar General Hospital of Guilan. His clinical presentation included dyspnea, sweating, left inguinal pain and shock. In the emergency room he was unable to describe his medical history. His wife reported that he had no cardiovascular or respiratory illness in the past. Four years back, he had undergone abdominal surgery for liver disease. Recently he complained of hernia-like swellings in both groin areas, one of which reduced while he was taking a bath. At the same time, symptoms of "steam suffocation" also appeared.

On physical examination, he was pale, anxious and breathless. Both ears were red and edematous. Heart rate was 108/min and regular. Blood pressure was 70 mmHg (systolic).

On cardiac auscultation, a normal  $S_1$  &  $S_2$  with an audible  $S_3$  was present. Bronchial breath sounds with wheezing and rhonchi were scattered throughout both lungs and fine crepitations were audible at the base of both lungs. Signs of bronchospasm were more clear on auscultation of the lung apex.

A surgical scar was visible at the right upper quadrant. The liver and spleen and no mass were palpable in the abdomen. The left inguinal region was tender. A cystic, non-tender oval swelling of 10 cm was palpable in the right groin.

Aside from sinus tachycardia, no significant change could be found in the electrocardiogram. Hypersensitivity and allergic shock was successfully managed in the emergency room by appropriate parenteral drug treatment.

Routine blood tests showed 8% eosinophilia. Other hematology and blood chemistry tests were normal. Nothing abnormal was detected in the chest radiograph

and abdominal ultrasound study. Right inguinal sonography reported a cystic mass of 10 × 10 cm.

## Surgical approach and outcome

Upon incision of the right inguinal region, an extra-abdominal, oval cyst was found adherent to the spermatic cord within a hernial sac. It was carefully dissected and removed. On exploration of the left inguinal canal, the cyst wall, daughter cysts, and the laminated membrane were found inside a sac. All these contents were removed from the inguinal canal. Pathology of the cysts revealed *Echinococcus multilocularis*.

The patient recovered and left the hospital in good general health. He was also given albendazole 300 mg daily for 30 days.<sup>8-10</sup>

## DISCUSSION

Hydatid cyst of the inguinal canal is very rare. Authentic textbooks on parasitology<sup>4</sup> and surgery<sup>5,7</sup> have not reported such a case until today. To our knowledge and after an enthusiastic literature review, no clear-cut case has been described in which the site of disease was the inguinal canal.

This case illustrates the difficulty encountered in making a diagnosis of hydatid cyst at unusual sites when clues are not recognized. The differential diagnosis of such swellings includes inguinal hernia, enlarged lymph nodes, psoas abscess, encysted hydrocele of the spermatic cord, tumors of the cord, hydatid of Morgagni, aneurysm of the external iliac artery, distended psoas bursa and effusions into the hip joint. Sonography of scrotal swellings can differentiate hydatid cyst from other swellings of the cord. Lipomas of the spermatic cord can mimic an indirect hernia sac exactly.<sup>11</sup>

This patient was previously operated for hepatic hydatid cyst, and the presence of a hernial sac in the inguinal canal indicates that in this case cystic fluid might have entered the inguinal hernial sac, which later caused the hydatid cyst.

Spillage of hydatid fluid and peritoneal infestation by its contents was considered a possibility in such a case. Therefore, an accurate and detailed search for daughter cysts was undertaken by an abdominal CT scan.

Drug therapy should be considered as an adjunct rather than an alternative to surgery and administered for at least a few weeks postoperatively. Drugs have been continued from a few months to several years in different reports.<sup>12</sup>

Prolonged use of albendazole, as the sole mode of therapy, has been advised only when there is disseminated hydatidosis with no chance of cure by surgery, the patient is not a good candidate for surgery, or the cysts are surgically unapproachable.

## REFERENCES

1. Matson RM, Richard MD, Smyth JD: Hydatidosis, a global problem of increasing importance. *Bull WHO* 55: 499-507, 1977.
2. Doty E, Tompkins RK: Management of cystic disease. *Surgical Clinics of North America*, April, 290-294, 1989.
3. Radford AJ: Hydatid disease, In: Weatherall DJ, Ledinghom JGG, Warrel DA, (eds.), *Oxford Textbook of Medicine*. Second ed., Vol. 1, Oxford: Oxford University Press, p. 563, 1988.
4. John DT: *Medical Parasitology*. Philadelphia: W.B. Saunders, pp. 246-254, 1992.
5. Schwartz SI: Hydatid cysts, In: Schwartz SI, Shires GT, Spencer FC, (eds.), *Principles of Surgery*. 6th ed., Vol. 2, New York: McGraw-Hill, p. 1332, 1994.
6. Bastani B, Dehdashti F: A review on hydatid cyst of the liver with a brief report of 126 cases from Fars province. *MJIRI* 6(4): 257-264, 1993.
7. Saidi F: *Surgery of Hydatid Disease*. Philadelphia: W.B. Saunders, p. 286, 1986.
8. Morris DL, Dykes PW, Dickson B, Marriner SE, Bogan JA, et al: Albendazole in hydatid disease. *Br Med J* 286: 103-104, 1983.
9. Schantz PM: Effective medical treatment of hydatid disease. *JAMA* 253: 2095, 1985.
10. Webster LT Jr: Drugs used in the chemotherapy of helminthiasis. In: Goodman Gilman A, Rall TW, Nies AS, Taylor P (eds.), *The Pharmacological Basis of Therapeutics*. 8th ed., Vol. II, New York: Pergamon Press, p. 964, 1991.
11. Wantz GE: Abdominal Wall Hernias, In: Schwartz SI, Shires GI, Spencer FC, (eds.), *Principles of Surgery*. 6th ed., New York: McGraw-Hill, pp. 1519-1520, 1994.
12. Eyail L, Zveibil F, Stamler B: Anaphylactic shock due to rupture of a hepatic hydatid cyst. *J Ped Surg* 260: 217-218, 1991.



Figure 1