

A CASE REPORT OF *LINGUATULA SERRATA* IN HUMAN PHARYNX FROM SHIRAZ, SOUTHERN IRAN

S.M. SADJJADI, S.M. ARDEHALI, AND A. SHOJAEI*

From the Parasitology and *Mycology Department, Shahid Beheshti Hospital, Medical School, Shiraz
University of Medical Sciences, Shiraz, Islamic Republic of Iran.

ABSTRACT

A case of linguatulosis due to *Linguatula serrata*, a zoonotic pentastomid parasite in the pharynx of a 35 year old woman from Shiraz is described. After removal of the parasites the patient was discharged without any further complaints.

MJIRI, Vol. 12, No. 2, 193-194, 1998.

INTRODUCTION

Linguatula serrata is a parasitic zoonoses and a member of an unusual phylum, i.e., pentastomida, with characteristics of both arthropods and annelids. Adult pentastomes parasitize the respiratory tract of reptiles or carnivorous mammals. The length of pentastomes range from a few millimeters to 15 cm or more depending upon the species. They tend to be colorless, transparent and possess two pairs of hooks on either side of a projection that bears the true mouth.¹ These parasites are cosmopolitan, and are mainly seen in tropical and subtropical areas. Cases of human disease have been reported from equatorial Africa, South-East Asia and the Middle East.^{1,2,3} Human infection results from ingestion of the third-stage larvae of *L. serrata* found in raw liver or lymph nodes of sheep, goats and camel. In this instance, humans are infected as temporary definitive hosts or via ingestion of eggs excreted from dogs, after which the nymphs settle in various organs. The infection generally remains asymptomatic, and is diagnosed after autopsy. Larval stages of *L. serrata* have been detected from domestic ruminants in Iran.⁴ Adult *L. serrata* have been identified in the nasal passages of over fifty percent of stray dogs in Shiraz (Oryan, Sadjjadi, et al., unpublished data). There are very few reported cases of human pentastomiasis from Iran.^{5,6} However, there are no reports of human pentastomiasis from the Fars province.

Correspondence:

Dr. S.M. Sadjjadi, Dept. of Parasitology and Mycology, School of Medicine, Shiraz University of Medical Sciences, Shiraz. P.O. Box 71345-1735, I.R. Iran. Tel: +98 71 305410 19 ext. 5335 Fax: 98 71 59847 E-mail: sadjjadm@pearl.sums.ac.ir

Case report

The patient was a 35 year old female from the city of Shiraz in Fars province, who complained of itching of the nose, palate and throat with copious nasal and lacrimal discharge and redness of the eyes and face. Upon examination of the pharynx there were 5 white spots on her palate. The white spots were soft and measured 5 × 2 mm. The specimens were removed with fine forceps and stained using FAAL method. Briefly, this method fixes, clears and stains the specimen simultaneously. Its components include formalin, lactophenol, azocarmine and distilled water. In microscopic studies the bodies were annulated and had 2 rows of closely set spines on both sides, characteristic of the nymphal stage of *Linguatula serrata* (Figs. 1-3).

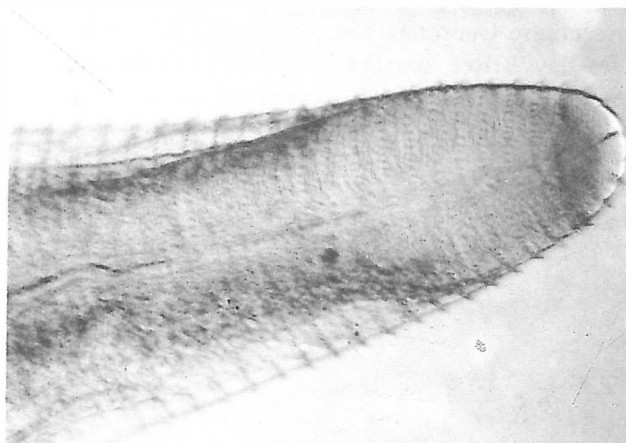


Fig. 1. *Linguatula serrata* from the patient's throat demonstrating the posterior part with annulation and thorns.

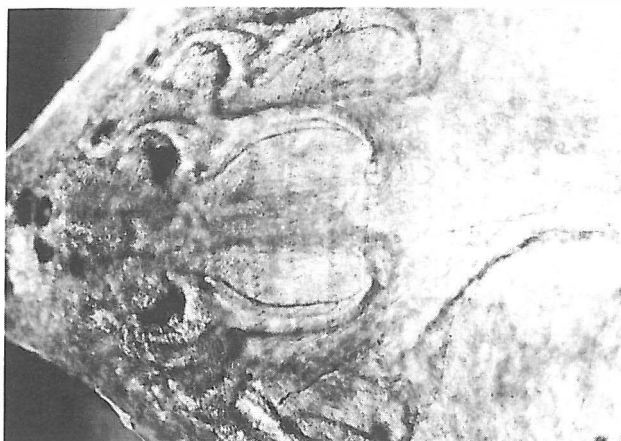

Fig. 2. *Linguatula serrata* demonstrating the anterior part with hooks and the mouth part.

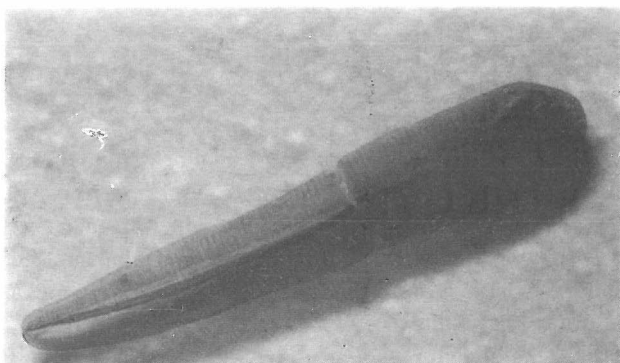


Fig. 3. The nymphal stage of *Linguatula serrata*.

DISCUSSION

Various organs in sheep, goat and camel can be infected with *L. serrata*.^{1,2,3} Consumption of raw liver is not unusual in Iran, particularly in women of child bearing age as in the present case. Our patient reported consumption of raw liver a few days before coming to the clinic. The case presented here is very much similar to the Marrara syndrome reported from Sudan which is seen after ingestion of raw liver, lungs, trachea and rumen of goats. In Lebanon another similar

condition is referred to as Halzoun which is the result of infestation of the upper respiratory tract by *Linguatula serrata* nymphs following consumption of raw or undercooked liver of sheep.^{3,8} The case presented in this report is nasopharyngeal linguatulosis resulting from ingestion of encapsulated nymphs in the uncooked liver of sheep. After removal of the parasites the patient was discharged without any further complaints. Regarding this report and similar observations,^{5,6} it is important to consider *Linguatula serrata* as a cause of irritation and discomfort of the throat in ear, nose and throat clinics.

REFERENCES

1. Beaver PC, Jung ROC, Cup EW: Crustacea, Linguatulid, Millipeds, Centipeds, Scorpions, Spiders, Ticks and Mites. In: Beaver PC, Jung ROC, Cup EW, (eds.), Clinical Parasitology. 9th edition, Philadelphia: Lea and Febiger, pp. 572-573, 1984.
2. Drabick JJ: Pentastomiasis. Review of Infectious Diseases 9: 1087-1094, 1987.
3. El-Hassan AM, Eltoum IA, El-Asha BMA: The Marrara syndrome: isolation of *Linguatula serrata* nymphs from a patient and the viscera of goats. Transactions of the Royal Society of Tropical Medicine and Hygiene 85: 309, 1991.
4. Mobedi I, Bazargani T, Mohaddess A, Tirgari S, Yazdanpanah A, Sadjjadi SM, Dalimi AH: Survey of condemned organs and study of parasites of camel in slaughterhouses of Tehran. Proceedings of the Scientific Seminar of the Veterinary Organization. Tehran, Vol. I, pp. 1-20, 1988. (In Persian).
5. Fata AM, Elahi R, Berenji F, Mirsalehi M: Pentastomiasis and report of the first case of Halzoun syndrome in Khorasan province. Medical Journal of Mashhad University of Medical Sciences 37: 137-142, 1994. (In Persian).
6. Hodjati MH, Naghili B: Report of a case with nasopharyngeal pentastomiasis from West Azerbaijan. Medical Journal of Tabriz University of Medical Sciences 23: 42-50, 1987. (In Persian).
7. Dalimi-Asl AH: Study of helminth parasites of carnivores in the northern parts of Iran. Ph.D. Thesis, School of Public Health, Tehran University of Medical Sciences, p. 120, 1989.
8. Manson-Bahr PEC, Bell DR: Unusual Parasites. In: Manson-Bahr PEC, Bell DR, (eds.), Manson's Tropical Diseases. 19th edition, London: Balliere-Tindall, pp. 561-563, 1987.