

## PENETRATING HEAD INJURY WITH A KNIFE—A CASE REPORT

S. AZHARI, M.D., AND A. KARIMI, M.D.

*From the Department of Neurosurgery, Imam Hosein Medical Center, Shaheed Beheshti University of  
Medical Sciences, Tehran, Islamic Republic of Iran.*

### ABSTRACT

A case of a transcranial stab wound is presented in which the patient was stabbed in the left temporal bone with a knife which, after traversing the tentorium, passed through the occipital squama and its tip reached the upper cervical area. The subject underwent surgery and was discharged without neurological sequelae. The fundamental principles of management in this specific type of head injury are discussed.

**Keywords:** Stab wound, penetrating head injury.

*MJIRI, Vol. 12, No. 2, 195-197, 1998.*

### INTRODUCTION

Stab wounds to the skull and brain have become extremely uncommon. Unlike craniocerebral missile injuries, low velocity penetrating stab wounds damage a focal area along the tract.<sup>1</sup> Although the nature and shape of offensive instruments are variable, generally over 90 percent of injuries result from an assault, and knives are the predominant weapon used.<sup>1-6</sup>

The most appropriate management in the field is to leave the instrument *in situ* and carefully transport the patient to a well-equipped trauma center.<sup>2</sup> We present a patient admitted with a knife embedded in the skull and discuss the neurosurgical management strategies.

### Case report

A 25 year old man from Afghanistan was admitted to the emergency department of Imam Hosein Medical Center after sustaining a temporal stab wound with a knife. The injury reportedly occurred during an assault. His friends attempted to withdraw the instrument, but they were not successful due to firm engagement of the knife in the skull.

On admission, vital signs were stable. He was conscious and oriented with a Glasgow Coma Scale score of 15/15. Neurological examination revealed no deficits. The patient received antitetanus serum, antibiotics, dexamethasone and a loading dose of phenytoin. Skull x-ray films (Fig. 1) showed intracranial penetration of the knife through the temporal squama with its tip reaching the upper cervical area.

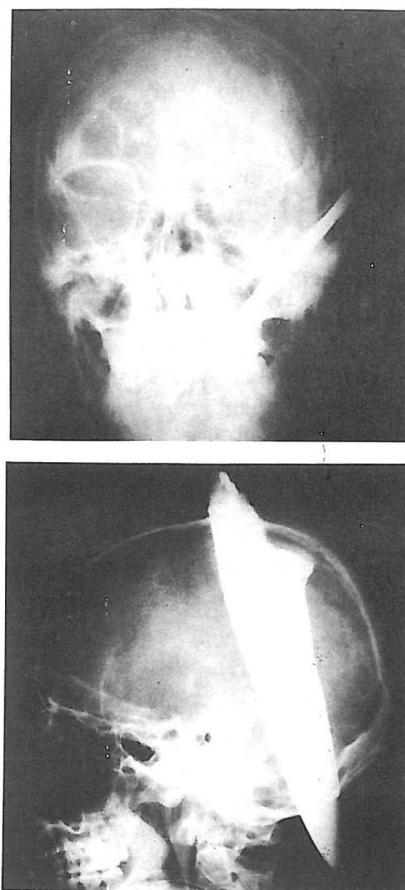


Fig. 1. Skull x-ray films (AP and lat) reveal the trajectory of the knife with its entrance point at the left temporal and its tip at the upper cervical area.

A CT scan confirmed the trajectory of the blade but was not useful because it was marred by heavy artifact (Fig. 2).

An angiogram was scheduled, but due to neurological deterioration the patient was transferred to the operating room with a GCS of 10/15. Under general anesthesia and in the prone position, the head was fixed in a horseshoe headholder and the handle covered with a sterile towel (Fig. 3). A left temporo-occipital skin flap was turned down and the incision extended toward the upper cervical area. After performing craniectomy around the entrance and exit sites, the knife was disengaged from the skull. The dural laceration was extended, necrotic brain tissue and hematoma were debrided, and the knife was withdrawn through its original path. Profuse bleeding from the transverse sinus wall laceration and disrupted cortical vessels was controlled and the dura repaired by pericranial patch grafts. The postoperative CT scan showed no hematoma (Fig. 4). The patient had an unremarkable postoperative course. In spite of our insistence, he refused angiography and was discharged after 10 days without any neurological deficit. There was no receptive aphasia, and visual field examination by confrontation showed no hemianopia.

## DISCUSSION

Early recognition and management of stab wounds to the brain is essential to ensure an optimal outcome.<sup>1</sup> If the weapon has been removed, the wound can be missed on physical examination.<sup>3</sup> Temporal stab wounds are particularly dangerous because of short distance to the brain stem and vascular structures. Of the six patients reported by De Villiers who had received a posterior temporal stab wound, five patients died and one had moderate disability.<sup>4</sup> In our case with a posterior temporal stab wound, the trajectory of the knife was in a direction such that no damage to vital structures occurred. Transcranial stab wounds and, in particular, transorbital injuries have been associated with post-traumatic aneurysms in up to 12% of cases and vasospasm in 10%.<sup>5-8</sup>

Although controversy exists with regard to timing of angiography, early angiography within 24 hours of injury appears warranted, with repeat studies being performed on a selective basis.<sup>9</sup> The cardinal principle is that no attempt should be undertaken to remove the offending instrument until careful investigation is done, and the surgeon is prepared to remove the instrument with an appropriate surgical plan.

During operation, care must be taken not to produce any rocking movement which may be transmitted to the tip of the instrument, and removal should retrace the original trajectory of the weapon.<sup>3</sup> The fundamental principles of surgical management include the prevention of early or late infection, thorough debridement of necrotic tissue and hematoma, removal of all accessible bone fragments and

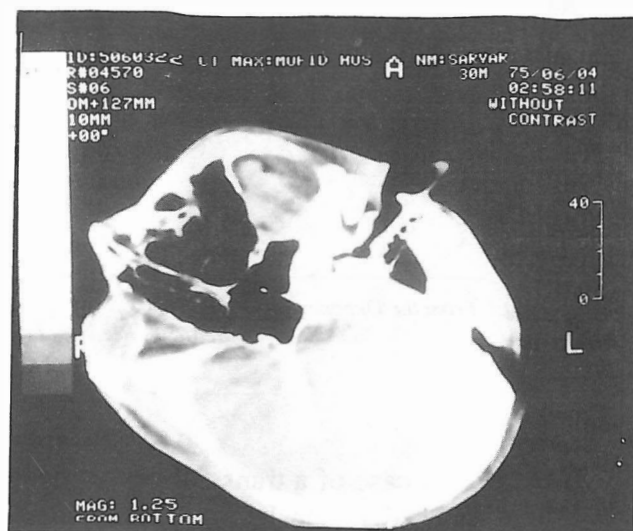


Fig. 2. CT scan shows heavy artifact produced by the blade.

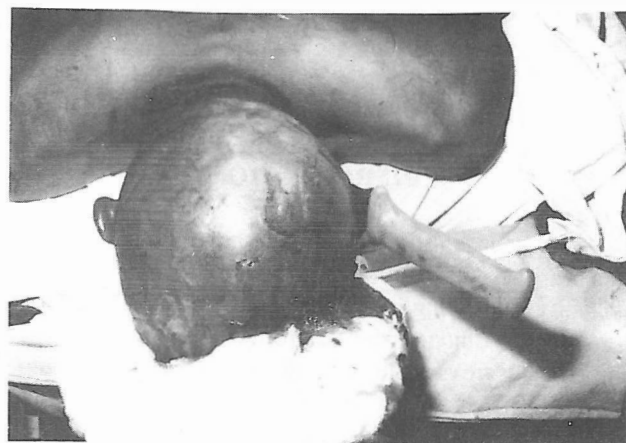

Fig. 3. The handle of the knife and head position is shown.

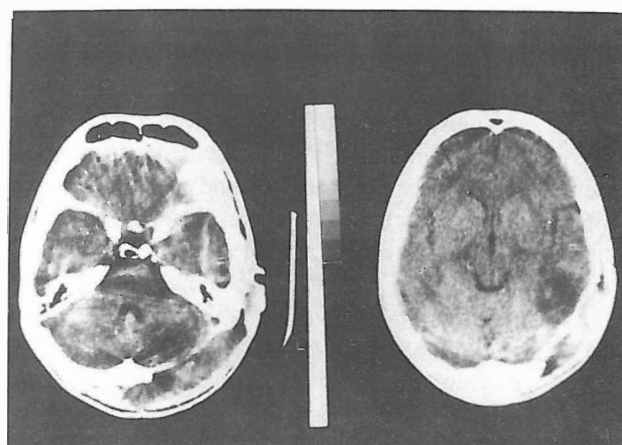

Fig. 4. Postoperative CT scan shows porencephalic area in left cerebellar hemisphere.

foreign body and meticulous closure to prevent cerebrospinal fluid fistula.<sup>2</sup> The two most common complications of these injuries are infection and secondary hemorrhage.<sup>3,6-9</sup>

## REFERENCES

1. Khalil N, Elwany MN, Miller JD: Transcranial stab wounds: morbidity and medicolegal awareness. *Surg Neurol* 35: 294-9, 1991.
2. O'Neill OR, Gilliland G, Delashaw JB, Purtzer TJF: Trans-orbital penetrating head injury with a hunting arrow: case report. *Surg Neurol* 42: 494-7, 1994.
3. Kelly DF, Nikas DL, Becker DP: Management of cranial stab wounds. In: Youmans JR, (ed). *Neurological Surgery*. Philadelphia: W.B. Saunders Company, pp. 1978-86, 1996.
4. Haworth CS, De Villiers JC: Stab wounds to the temporal fossa. *Neurosurgery* 23: 431-435, 1988.
5. Mezue W, Saddeqi N, Ude A: Barbed spear injury to the skull base : case report. *Neurosurgery* 28: 428-430, 1991.
6. De Villiers JC, Grant AR: Stab wounds at the cranio-cervical junction. *Neurosurgery* 17: 930-936, 1985.
7. Kieck CF, De Villiers JC: Vascular lesions due to trans-cranial stab wounds. *J Neurosurg* 60: 42-46, 1984.
8. Haddad FS, Haddad GF, Taha J: Traumatic intracranial aneurysms caused by missiles: their presentation and management. *Neurosurg* 28: 1-7, 1991.
9. DuTrevou MD, Van Dellen JR: Penetrating stab wounds to the brain: timing of angiography in patients presenting with the weapon already removed. *Neurosurgery* 31: 905-912, 1992.

