

THE EFFECTS OF ANTERIOR DISCECTOMY AND INTERPOSITIONAL IMPLANT UPON LUMBAR MOTION SEGMENT STABILITY

KEIKHOSROW FIROOZBAKHS, Ph.D.,
AND FRED V. ORCUTT, M.D.

*From the Department of Orthopaedics and Rehabilitation, University of New Mexico School of Medicine,
Albuquerque, New Mexico, U.S.A.*

ABSTRACT

The cadaver spine motion segment behavior under torsional load was evaluated with the disc intact, with partial anterior discectomy and with spacer insertion. The results of this study explain how anterior lumbar discectomy and interbody fusion (ALIF) affects the torsional stability of the motion segment.

The pseudarthrosis rate of the anterior lumbar discectomy and interbody fusion (ALIF) is known to vary with level. Therefore fifteen fresh human cadaveric degenerated discs at L3-4, L4-5, and L5-S1 levels were loaded in torsion: intact; after anterior discectomy; and, after spacer interposition and removal.

Torsional rigidity of intact L5-S1 was greater than L3-4 (41%) or L4-5 (53%). Anterior discectomy significantly decreased the torsional rigidity compared to intact: L3-4 (73%); L4-5 (48%); and L5-S1 (55%). Interpositioning of spacer partially restored the torsional stability compared to discectomy: L3-4 (22%); L4-5 (18%); and L5-S1 (38%).

In conclusion, L5-S1 degenerated discs are rotationally more stable than L3-4 or L4-5. Anterior discectomy significantly increases torsional flexibility. Spacer interposition partially restores the disc's torsional stability which is most prominent at the L5-S1 level. Increased rotational flexibility seems related to pseudarthrosis rate.

Keywords: Lumbar spine; Biomechanics, Rotational instability, Arthrodesis.

MJIRI, Vol. 12, No. 1, 71-74, 1998.

INTRODUCTION

Anterior lumbar discectomy and interbody fusion (ALIF) has been employed to treat a number of disorders

Correspondence:

Keikhosrow Firoozbakhs, Ph.D., Department of Orthopaedics and Rehabilitation, University of New Mexico School of Medicine, Albuquerque, NM 87131-5296, U.S.A.

including degeneration,^{2-4,6,7,10,13,19,21} herniation,^{11,22,24} and instability either with or without posterior arthrodesis. ALIF involves removal of the anterior portion of the annulus fibrosis (AF), the cartilage end plates (EP) and the entire nucleus pulposus (NP). A bone plug is then inserted to facilitate arthrodesis. During the postoperative course a decrease of the intervertebral space, iliac graft fragmentation and resorption and nonunions have been observed. Loguidice et al.¹⁴ observed that the pseudarthrosis

Discectomy and Lumbar Stability

Table I. Details of specimens.

Specimen No.	Age (Yr)	Sex	Bone mineral density L4(g/cm ²)	Cause of death
91-93	70	M	0.92	respiratory arrest
92-121	70	M	0.98	congestive heart failure
906	60	F	0.99	cardiac arrest
92-176	67	F	0.85	cardiac arrest
91-39	57	M	1.20	cardiac arrest

The bone mineral density of L4 is a representative of the subjects' overall vertebral bone density.

rate varied with fusion level; 31% at L3-4; 21% at L4-5; and 16% at L5-S1. This suggests that the stability characteristics of the lower lumbar motion segments may vary with level. Previous studies have indicated that the AF and facets resist torsion.^{1,5,17,18} Haher et al.⁹ found the disc to be the most important structure for resisting torsion. Farfin et al.⁵ reported that 40 to 50% of the torque strength of a motion segment was provided by the disc. Others^{15,16,18,23} found an alteration in motion behavior with disc injury.

Based on these studies, we propose that large shear strain at the site of attempted arthrodesis may disrupt osteogenesis and promote nonunion. Understanding the physiology and biomechanics of ALIF may result in more effective methods of treatment and may improve clinical results.

The purpose of this study is to compare the torsional rigidity of the lower three lumbar discs in situations simulating ALIF.

MATERIALS AND METHODS

This study employed 15 fresh human cadaveric motion segments at levels of L3-L4, L4-L5, and L5-S1. Specimens were age 57 or older so that discs would likely be degenerated, inasmuch as ALIF is typically performed on degenerated discs. Saline discography demonstrated grade III degeneration²⁰ in each disc. Posterior elements were removed in order to isolate testing to the disc. Vertebral body mineral density was determined by dual-photon absorptiometry with a Lunar DP4 Scanner.

The motion segments were stored at -27°C in normal saline soaked towels in sealed plastic bags. When thawed for testing they were bathed in normal saline at 22°C. The discs were localized radiographically using 25 gauge needles inserted into each EP. Four screws were inserted at 90° intervals into both vertebral bodies which were potted with acrylic in metal cups. Radiographs confirmed disc location and orientation.

The specimens were loaded in torsion using an Instron

Table II. Percent change in rotational rigidity of L3-L4 motion segment.

Specimen No.	Discectomy	With Spacer	Spacer Removal
91-93	-55	-32	-61
92-121	-85	-69	-88
906	-80	-43	-83
92-176	-86	-60	-88
91-39	-59	-50	-65
Mean±SD	-73±14.8	-50.8±14.4	-77±13.0
P Value	0.0004	0.001	0.0009

Positive and negative signs, respectively, indicate increase and decrease from the initial intact state.

Table III. Percent change in rotational rigidity of L4-L5 motion segment.

Specimen No.	Discectomy	With Spacer	Spacer Removal
91-93	-66	-43	-79
92-121	-62	-54	-71
906	-27	+4	-35
92-176	-60	-43	-75
91-39	-26	-16	-41
Mean±SD	-48.2±19.9	-30.4±23.7	-60.2±20.5
P Value	0.006	0.046	0.003

Positive and negative signs, respectively, indicate increase and decrease from the initial intact state.

electrohydraulic testing machine at a rate of 0.6 N-m/deg.⁸ In order to exclude the possibility of flexion or extension of the motion segment (due to lack of muscle stability),^{9,12,18} no compressive loading was used in testing. This seemed

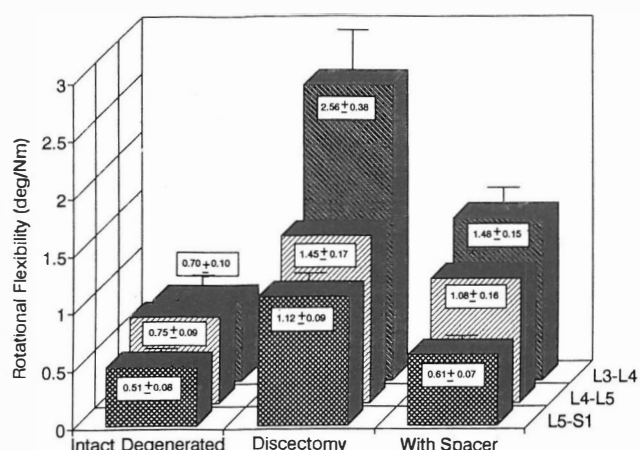


Fig. 1. Rotational flexibilities of the motion segments at three levels for the intact disc, after discectomy, and after interposition of the spacer.

appropriate in this study where the posterior elements of the motion segments were removed. Each specimen was subjected to four 10° rotational cycles of loading and unloading: first, intact; second, after discectomy; third, after interposition of a metal spacer; and fourth, after spacer removal. The rate of loading and the rotational angle was selected to simulate a physiological loading but to remain nondestructive.⁸ The discectomy was produced by removing a 2.5 cm segment of anterior AF with superior and inferior EP's and the entire NP, simulating the surgical procedure. The specimens were distracted under 100 Newton force so that an aluminum spacer block, whose thickness was determined by the distance between individual vertebral surfaces, could be inserted tightly. Distraction was released during subsequent testing. Throughout the testing, tissues were moistened with normal saline.

A torque-rotation curve was determined for each of the 60 tests and was plotted with a rate of 50 readings per second. Torsional rigidity (the average slope of the torque-rotation curve) was determined. The data for the discectomy and spacer tests were normalized to their respective intact specimens. Significance was determined using paired Student's t-tests at the $p < 0.05$ level.

RESULTS

The age, sex, cause of death, and bone mineral density of the subjects are given in Table I. The average torsional rigidity of the intact L5-S1 discs was significantly higher than L3-4 (41%) and L4-5 (53%). The rotational rigidity data in term of percent loss compared to the intact specimens are given in Tables II, III and IV. The average decrease in the stability after discectomy in L3-4 was 73%, in L4-5 was 48% and in L5-S1 was 55%. Interpositioning of spacer partially restored the torsional stability compared to discectomy: L3-4 (22%); L4-5 (18%); and L5-S1 (38%). Upon removal of the spacer, the torsional rigidity was not significantly different than that after discectomy, implying that testing was nondestructive.

DISCUSSION

The findings confirm that the intact L5-S1 disc is inherently more stable than the L3-4 or L4-5 discs. There is a marked increase in flexibility at all levels when an anterior discectomy is performed. This increase is most prominent at L3-4. The increased flexibility is only partially restored when a spacer is inserted.

Figure 1 compares the rotational flexibility of the three

Table IV. Percent change in rotational rigidity of L5-S1 motion segment.

Specimen No.	Discectomy	With Spacer	Spacer Removal
91-93	-70	-40	-78
92-121	-37	-30	-37
906	-44	-14	-48
92-176	-50	-5	-73
91-39	-75	+5	-80
Mean±SD	-55.2±16.5	-16.8±18.3	-63.3±19.4
P Value	0.002	0.101	0.002

Positive and negative signs, respectively, indicate increase and decrease from the initial intact state.

levels before and after discectomy and after spacer insertion. This suggests that there may be a relationship between rotational flexibility and the nonunion rate reported by Loguidice et al.¹⁴ After anterior discectomy and spacer interpositioning, the torsional rigidity of the motion segment is decreased compared to the intact disc: L3-4(52%); L4-5 (31%); and L5-S1 (16%). We note that posterior instrumentation increases the torsional stability postoperatively. This study implies that by further increasing rotational rigidity, the nonunion rate may be lessened. Anterior implants used to promote arthrodesis should be designed to maximize rotational stability.

ACKNOWLEDGEMENT

This project was supported in part by the Dedicated Health Research Funds of the University of New Mexico School of Medicine.

REFERENCES

1. Adams MA, Hutton WC: The relevance of torsion to the mechanical derangement of the lumbar spine. *Spine* 6: 241-248, 1981.
2. Blumenthal SL, Baker J, Dossett A, Selby DK: The role of anterior lumbar fusion for internal disc disruption. *Spine* 13: 566-569, 1988.
3. Chow SP, Leong JCY, Ma A, Yau APMC: Anterior spinal fusion for deranged lumbar intervertebral disc. *Spine* 5: 452-458, 1988.
4. Crock HV: Anterior lumbar interbody fusion. *Clin Orthop* 165: 157-163, 1982.
5. Farfan HF, Cossette JW, Robertson GH, Wells RV, Kraus H: The effect of torsion on the lumbar intervertebral joints: the role of torsion in the production of disc degeneration. *J Bone Joint Surg* 52A: 468-497, 1970.
6. Flynn JC, Hoque MA: Anterior fusion of the lumbar spine. *J Bone Joint Surg* 61A: 143-150, 1979.
7. Fujimaki A, Crock HV, Bedbrook GM: The results of 150 anterior lumbar interbody fusion operations performed by two surgeons in Australia. *Clin Orthop* 165: 164-167, 1982.
8. Goel VK, Nishiyama K, Weinstein JN, King Liu Y: Mechanical properties of lumbar spinal motion segments as affected by partial disc removal. *Spine* 11(10): 1008-1012, 1986.
9. Hafer TR, Feimy W, Baruch H, Delvin V, Welin D, O'Brien M, Ahmad J, Valenza J, Parish S: The contribution of the three columns of the spine to rotational stability; a biomechanical model. *Spine* 14(7): 663-669, 1989.
10. Harmon PH: Anterior excision and vertebral body fusion operation for intervertebral disc syndromes of the lower lumbar spine. *Clin Orthop* 56: 133-162, 1963.
11. Inoue S, Watanabe T, Hirose A, Tanaka T, Matsui N, Saegusa O, Sho E: Anterior discectomy and interbody fusion for lumbar disc herniation. *Clin Orthop* 183: 22-31, 1984.
12. Janevic J, Ashton-Miller A, Schultz AB: Large compressive preloads decrease lumbar motion segment flexibility. *J Orthop Res* 9(2): 228-236, 1991.
13. Lane JD, Moore Es Jr: Transperitoneal approach to the intervertebral disc in the lumbar area. *Ann Surg* 127: 537-551, 1948.
14. Loguidice VA, Johnson RG, Guyer RD, Stith WJ, Ohnmeiss DD, Hochschuler SH, Rashbaum RF: Anterior lumbar interbody fusion. *Spine* 13: 366-369, 1988.
15. Markolf KL, Morris JM: The structural components of the intervertebral disc: a study of their contributions to the ability of the disc to withstand compressive forces. *J Bone Joint Surg* 56A: 675-687, 1974.
16. Panjabi MM, Krag MH, Chung TQ: Effects of disc injury on mechanical behavior of the human spine. *Spine* 9: 707-713, 1984.
17. Panjabi MM, White AA, Johnson RM: Cervical spine mechanics as a function of transection of components. *J Biomech* 8: 327-336, 1975.
18. Posner I, White AA, Edwards T, Hayes WC: A biomechanical analysis of the clinical stability of the lumbar and lumbosacral spine. *Spine* 7: 374-389, 1982.
19. Raugstad TS, Harbo K, Hogberg A, Skeie S: Anterior interbody fusion of the lumbar spine. *Acta Orthop Scand* 53: 561-565, 1982.
20. Sachs BL, Vanharanta H, Spivey MA: Dallas discogram description. A new classification of CT/discography in low back disorders. *Spine* 12: 287-294, 1987.
21. Sorensen KH: Anterior interbody lumbar spine fusion for incapacitating disc degeneration and spondylolisthesis. *Acta Orthop Scand* 49: 269-277, 1978.
22. Suzuki J: Anterior body fusion for lumbar disc herniation. *J Jpn Orthop Assn* 32: 948-954, 1958.
23. Tencer AF, Ahmed AM, Buke DL: Some static mechanical properties of the lumbar intervertebral joint, intact and injured. *J Biomech Eng* 104: 193-201, 1982.
24. Tsuchiya K: A long term follow-up study of transperitoneal anterior vertebral body fusion (Suzuki's method) for lumbar disc herniation—especially on the influence of vertebral body fusion upon the lumbar vertebral column. *J Jpn Orthop Assn* 47: 731-737, 1973.