

UNUSUAL AND RARE TERATOMAS OF THE HEAD AND NECK: A REPORT OF THREE CASES

M. NAGHIBZADEH, M.D.

*From the Department of Otolaryngology, Ghaem Medical Center, Mashhad University of
Medical Sciences, Mashhad, I.R. Iran.*

ABSTRACT

Teratomas are bulky lesions that rarely occur in the head and neck regions. They are composed of tissues from all germ layers with varying degrees of differentiation. They arise from pluripotential stem cells and ectopic embryonic non-germ cells. The most common sites of occurrence in the head and neck are the cervical region and the nasopharynx. Three cases of these tumors are reported here that were found in the nasopharynx, cervical region and the base of the tongue.

MJIRI, Vol. 12, No. 1, 89-92, 1998.

INTRODUCTION

Teratomas are multipotential tumors that are believed to arise from toti- or pluripotential cells. In the course of growth they may differentiate into tissues that represent more than one germ layer of embryo. In other words, they may contain cartilage, bone and fat of mesodermal origin, or skin, hair and brain tissue of ectodermal origin. They may have glandular structures of intestinal mucosa of endodermal origin. Teratomas may occur at any site in the body, but it is of importance to know that they usually occur near the midline or in the glands where primitive nest cells may be trapped from the stages of early fetal development.^{2,17} The most favored site in infancy is the sacrococcygeal region and midline of the head and neck.⁷⁻¹⁴ Teratomas are of considerable clinical significance because of the respiratory distress that they produce¹⁶ and their tendency towards malignant transformation (carcinoma or sarcoma) in approximately 30% of cases.^{2,4,11} Therefore, they should be excised as soon as feasible.⁹

CASE REPORTS

Case 1

A 3,100 g female was born at 41 weeks' gestation with respiratory distress. A tumor was found to be protruding from the oral cavity without adhesion to the oral vestibule

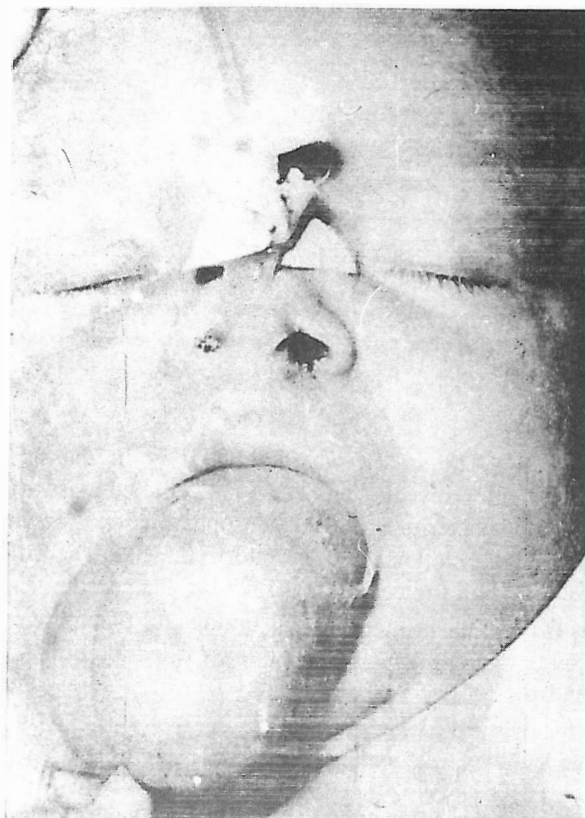

Fig. 1. Large teratoma protruding from the oral cavity.

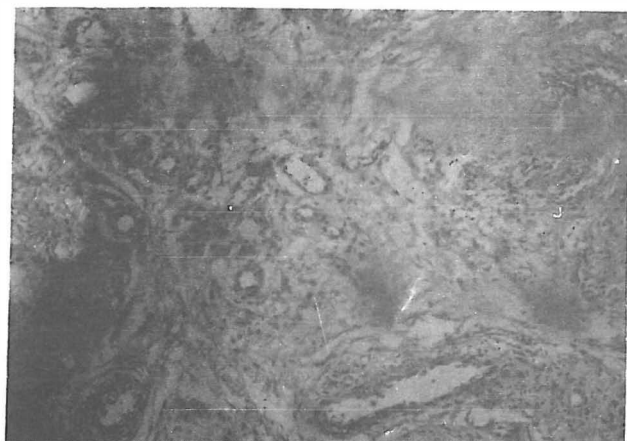


Fig. 2. Photomicrograph of the specimen.

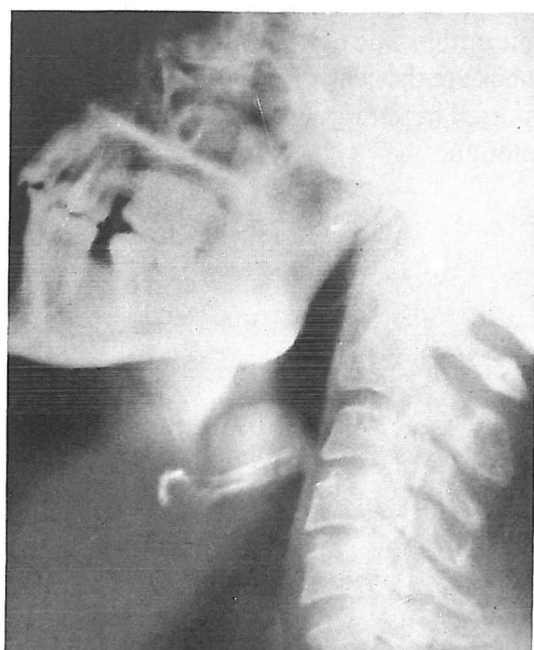


Fig. 3. Lateral neck x-ray. Tumor seen in the inferior part of the oropharynx.

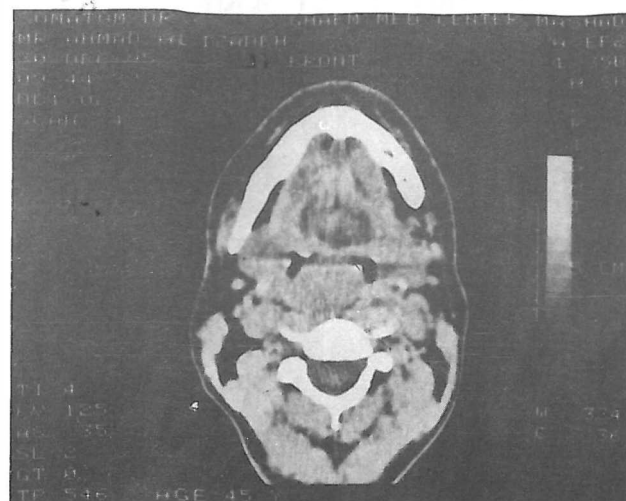

Fig. 4. Axial CT scan showing tumor in the inferior part of the oropharynx.

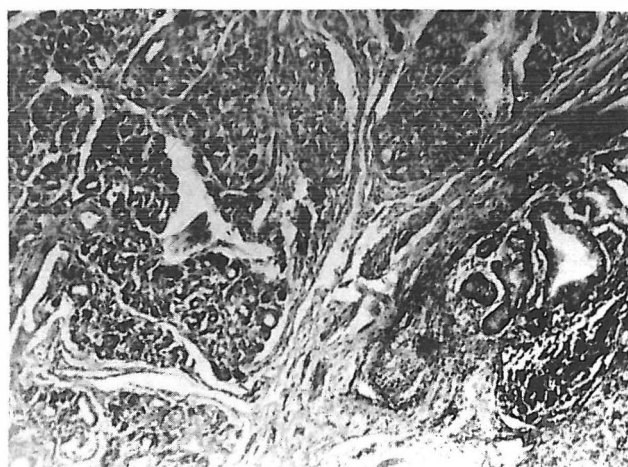


Fig. 5. Photomicrograph of the tumor containing connective tissue, muscle, mucous epithelium and glandular tissue.

(Fig. 1). The infant was immediately intubated, and examination revealed an 8×5×3 cm pedicled mass arising from the posterior wall of the nasopharynx and presenting through the cleft palate. Laboratory studies and neurologic examination showed normal findings. No communication between the nasopharyngeal tumor and the intracranial cavity could be detected. The mass filled the oral cavity, and the tongue was normal in size. Therefore, surgical excision was performed, and the tumor was removed transorally.

At the age of two, the patient's cleft palate was repaired, and she was followed with no further problems until eight years of age.

Case 2

A 35 year old male was admitted to our hospital for evaluation. He had respiratory distress, especially during sleep, a "hot potato" voice, and dysphagia due to a tumor at the base of his tongue. Symptoms had begun when he was 10 years old and progressed slowly. Physical examination, lateral neck X-ray and CT scan (Figs. 3,4) showed a hard, solid encapsulated mass in the inferior part of the oropharynx. Arising from pediculated adhesions at the base of the tongue, vallecula and pharyngeal surface of the epiglottis, the tumor had not invaded surrounding tissues.

A 4×3.5 cm encapsulated tumor was successfully removed transorally with the patient under general

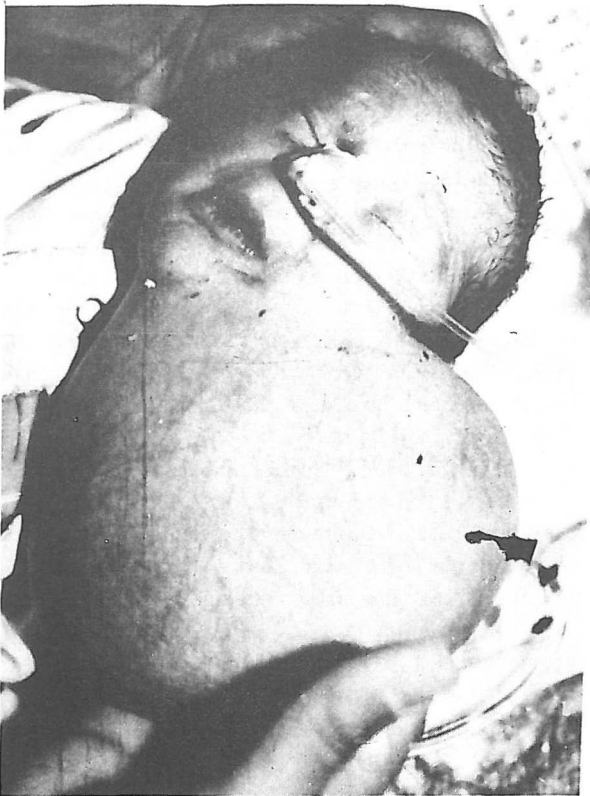

Fig. 6. Case no. 3 with a large neck mass involving the left side and lower lateral portion of the face.

anesthesia. The mass microscopically contained connective tissue, muscle, mucosal epithelium, and glandular tissue surrounded by keratinized squamous epithelium.

The patient remains disease-free following his operation. Teratoma of the tongue is an unusual and extremely rare tumor of the oral cavity with only six reported cases in the literature up to the year 1992.^{1,8}

Case 3

A 4,350 g male was born at 40 weeks' gestation by cesarean section. The child had mild respiratory distress immediately following delivery. An obvious neck mass was detected involving the left side of the neck and lower lateral portion of the face. Mild paresis of the marginal mandibular branch of the facial nerve was also noted. The tumor had the clinical appearance of a cystic hygroma⁶ (Fig. 6). Ultrasonography showed a large cervical mass with mixed echogenicity, showing both solid and cystic components. A diagnosis of probable cystic hygroma colli was made, but it did not transilluminate. On the 25th day of life, a 25×11×8 cm tumor was excised from the infant while under general anesthesia.

Histologic evaluation revealed a wide range of cellular differentiation with variable degrees of maturation in the brain tissue (Fig. 8), cartilage, connective tissue and muscle

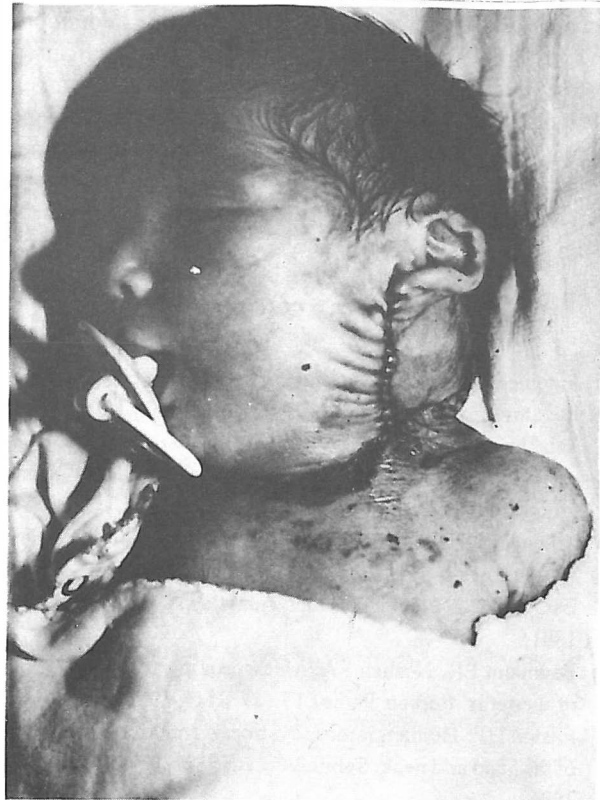

Fig 7. Case no. 3 after surgery.

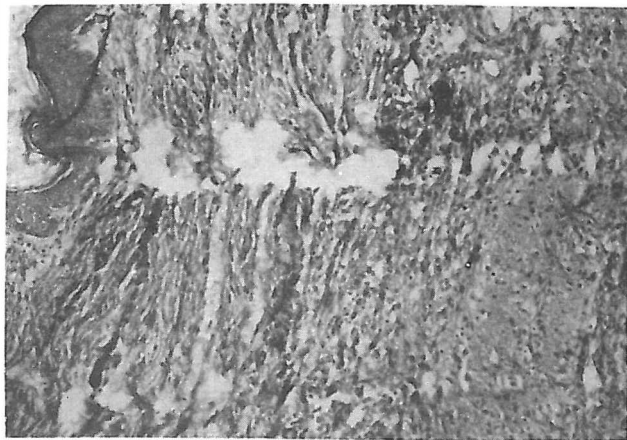


Fig. 8. Photomicrograph of the teratoma with abundant brain tissue.

which were surrounded by keratinizing squamous epithelium.

DISCUSSION

Teratomas of the head and neck are rare developmental malformations that most commonly present at birth¹⁰ and rarely occur in patients over the age of two years.¹⁴ The

most common site of presentation is the cervical region and nasopharynx. Head and neck teratomas most commonly emerge during the neonatal stage and present with airway obstruction and a high mortality rate in untreated patients. The tumors are usually benign, but they have an incidence of malignancy when discovered in adulthood. The treatment of choice for teratoma is complete surgical excision with preservation of normal anatomic structures.

REFERENCES

1. Antoine GA, et al: Teratoma of the tongue, a case report and literature review. *Laryngoscope* 95 (10): 1262-1263, 1985.
2. Azizkhan RG, et al: Diagnosis, management and outcome of cervicofacial teratomas in neonates: a childrens' cancer group study. *J Pediatr Surg* 30(2): 312-6, 1995.
3. Ballenger JT: Tumors and cysts of the face, mouth, head and neck. In: Ballenger JT, (ed.), *Diseases of the Nose, Throat, Ear, Head & Neck*. Philadelphia: Lea & Febiger, p. 330, 1991.
4. Baumann ER, Nerlich PA: Metastasizing cervical teratoma of the fetus. *Pediatr Pathol* 13 (1): 21-7, 1993.
5. Filston HF: Hemangiomas, cystic hygromas, and teratomas of the head and neck. *Semin Pediatric Surgery* 3 (3): 147-59, 1994.
6. Jaarsma AS, et al: Neonatal teratoma presenting as hygroma colli. *Int J Pediatrics* 153 (4): 276-8, 1994.
7. Kountakis SE, et al: Teratomas of the head and neck. *Am J Otolaryngol* 15 (4): 276-8, 1994.
8. Lalwani AK, Engel TL: Teratoma of the tongue, a case report and review of the literature. *Int J Pediatr Otorhinolaryngol* 24 (3): 261-8, 1992.
9. Nmadu PT: Cervical teratoma in later infancy, report of 13 cases. *Ann Trop Pediatr* 13 (1): 95-8, 1993.
10. Sharma AK, et al: Teratoma in pediatric age group, experience with 75 cases. *Indian Pediatr* 3 (5): 689-94, 1993.
11. Rothschild MD, et al: Evaluation and management of congenital cervical teratoma, case report and review. *Arch Otolaryngol Head Neck Surgery* 120 (4): 444-8, 1994.
12. Rybac LP, et al: Obstructing nasopharyngeal teratoma in the neonate, a report of two cases. *Arch Otolaryngol Head Neck Surg* 117 (12): 1411-15, 1991.
13. Saing H, Lau F, Chan YF, Chan FL: Parapharyngeal teratoma in newborn. *J Pediatr Surg* 29 (12): 1524-5, 1994.
14. Sawakuji M, et al: A case report of cervical teratoma in adult. *Nippon Kyobu Geka Gakkai Zasshi* 41 (11): 2220-3, 1993.
15. Sheror DM, et al: Prenatal sonographic assessment of early, rapidly growing fetal cervical teratoma. *Prenatal Diag* 13 (12): 1079-84, 1993.
16. Talmi YP, Sadov R, Dulitzky F, Finkelstein Y, Zohar Y: Teratoma of the mastoid region in a newborn. *J Laryngol Otol* 102 (11): 1033-1035, 1988.
17. Ward RF, April M: Teratoma of the head and neck. *Otolaryngol Clin North Am* 22 (3): 621-29, 1989.