

## DISSEMINATED INFECTION DUE TO *FUSARIUM SP.* IN A PATIENT WITH CHRONIC GRANULOMATOUS DISEASE

SHAHINDOKHT BASIRI DJAHROMI, ALI ASGHAR KHAKSAR,  
MOJGAN VAZIRI KASHANI,\* AND SAHBA ARSHI\*\*

From the Department of Medical Mycology, Pasteur Institute of Iran, the \*Section of Pathology, Pasteur Institute of Iran, and the \*\*Department of Pediatrics, Hazrat Rasool Acram Hospital, Iran University of Medical Sciences, Tehran, Islamic Republic of Iran.

### ABSTRACT

The present report discusses disseminated fusariosis in a 15 year old boy with chronic granulomatous disease (CGD). He was admitted to the Hazrat Rasool Acram Hospital in November 1995, with a chronic wound in the right ankle and buttock area. Antibacterial therapy was started, but there was no response. The patient was still febrile. Chest x-ray revealed parahilar lesions in both lungs. Tissue biopsy and broncho-alveolar lavage were performed and the specimens were sent to Pasteur Institute. In both specimens, *Fusarium sp.* was recognized as the pathologic agent by direct smear and culture techniques. The patient underwent antifungal therapy receiving amphotericin B and oral ketoconazole. The result of this treatment suggests that aggressive management of fusariosis offers the best chance of survival. This paper reports the first case of disseminated fusariosis in Iran.

**Keywords:** Fungal infection, *Fusarium sp.*, Chronic granulomatous disease.

*MJIRI, Vol. 12, No. 1, 93-96, 1998.*

### INTRODUCTION

*Fusarium sp.* is a common soil organism and has been reported most frequently as an agent of mycotic keratitis.<sup>2,5</sup> It is usually considered an opportunistic fungus in man;<sup>12</sup> however, there have been a number of recent reports in which *Fusarium sp.* caused systemic fungal infections.<sup>16</sup> Systemic infection with *Fusarium sp.* occurs predominantly in immunocompromised patients.<sup>13</sup>

Several cases of onychomycosis and keratitis with *Fusarium Sp.* have been reported in Iran,<sup>14,15,20</sup> but the present case is the first report of disseminated fusariosis.

#### Case report

A 15 year old boy, who was a known case of CGD, was

admitted to Hazrat Rasool Acram Hospital on November 5th, 1995 with an oozing erythematous, edematous and painful lesion of the right ankle area (Fig. 6). His problem began when he was 2 years old with an ulcerative and infectious lesion in the neck area, which was recurrent. Despite the negative cultures of lymph node and fistular discharges, he underwent a clinical trial of anti-TB therapy for 30 months. This treatment trial made him free of symptoms within a year. In 1992 he had an ankle sprain. After removal of the cast, the area began to swell and ulcerate. The lesion exacerbated gradually and fistulization occurred. Treatment with cephalothin and gentamicin was begun, but the response was not satisfactory. So this drug regimen was replaced by co-trimoxazole and erythromycin. Initially the lesions healed but they recurred about 5

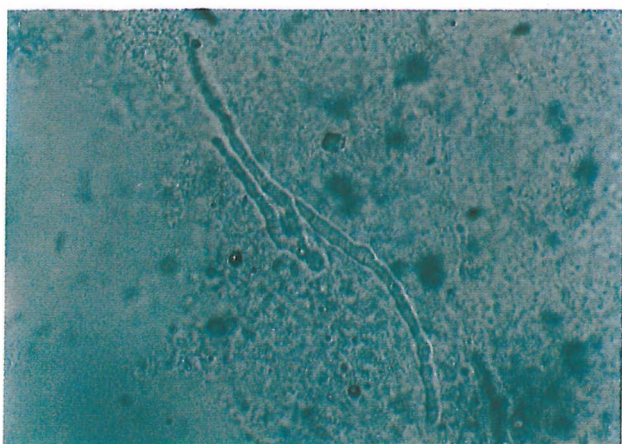


Fig. 1. Microscopy of broncho-alveolar lavage, showing *Fusarium sp.* hyphae.  $\times 400$ .

months later. In 1993 the patient was referred to the pediatric medical center, where CGD was definitively diagnosed (NBT= 0)\*. The patient underwent treatment with cephalexin, co-trimoxazole and gamma interferon. He had two other hospital admissions in Sept. 1994 and Feb. 1995. Debridement of the ankle lesion and an iliac bone graft were performed, followed by antibiotic therapy. On November 5th, 1995, the patient was admitted again in Hazrat Rasool Acram Hospital with ulcers on the right ankle and buttock area. The painful lesion of the right ankle was infiltrating, edematous and erythematous, and the tip was fistulized and oozing.

On physical examination he was pale and seemed anemic. He had high grade fever and generalized lymphadenopathy, associated with an itching maculopapular rash on his lower extremities and trunk. X-ray revealed osseous and ankle joint involvement. There was no response to antibacterial treatment with cephalothin (17 days) and amikacin (14 days). The patient was still febrile. Chest x-ray revealed parahilar lesions in both lungs. As there was no response to antibacterial therapy, fungal infections were suspected. A biopsy specimen of the lesion and B.A.L. (broncho-alveolar lavage) were performed and sent to Pasteur Institute. The specimens for mycological study were biopsy material of the lesion, B.A.L., and blood. Specimens were directly examined with 10% KOH. The biopsy specimens and B.A.L. showed the presence of branching hyaline septated hyphae (Figs. 1-3). The tissue sections were stained by hematoxylin and eosin and periodic acid schiff stains. Sections revealed a granulomatous reaction.

Ground tissue and B.A.L. were cultured on sabouraud dextrose agar, sabouraud dextrose agar with chloramphenicol (50 mg/mL), blood agar and brain heart

\*(NBT)= Nitro blue tetrazolin. Used for diagnosis and screening of chronic granulomatous disease and for detection of carrier state.<sup>4</sup>

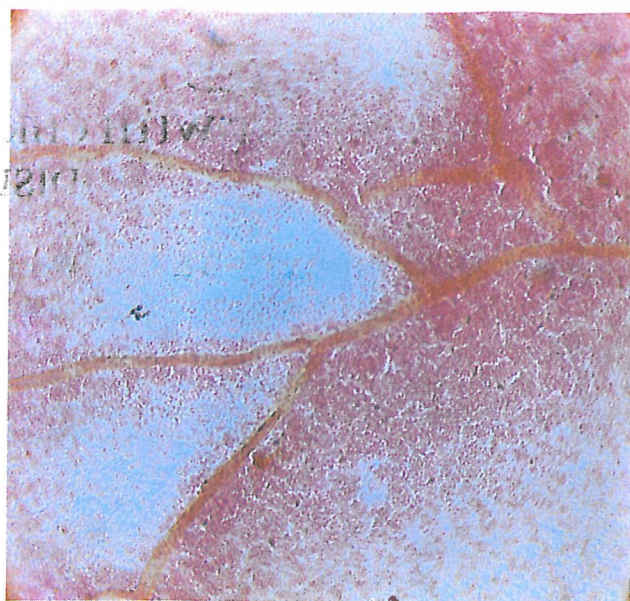


Fig. 2. Microscopy of skin biopsy specimen, showing *Fusarium sp.* hyphae.  $\times 400$ .

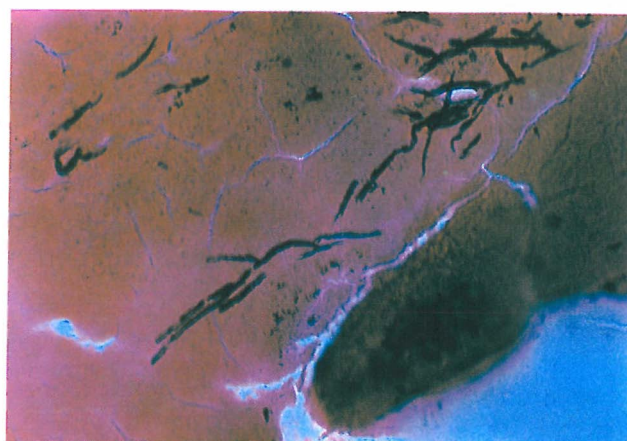


Fig. 3. *Fusarium sp.* hyphae in skin biopsy specimen.

infusion agar (BBL). Duplicate cultures on each medium were incubated at 37°C and 30°C. Culture of the specimens gave rise to *Fusarium sp.* The blood culture was negative.

Microscopic features of the isolates were studied by slide culture preparation. *Fusarium sp.* colonies were identified as initially cotton-white colonies which turned purple in the substratum (Fig. 4).

Microscopic examination showed hyaline septate hyphae with conidiophores borne singly or in groups, banana-shaped macroconidia and oval or elongated single-cell microconidia (Fig. 5).

The patient underwent a 40-day course of intravenous amphotericin B (1 mg/kg/day), and oral ketoconazole for a total period of 50 days (150 mg/day). Following antifungal

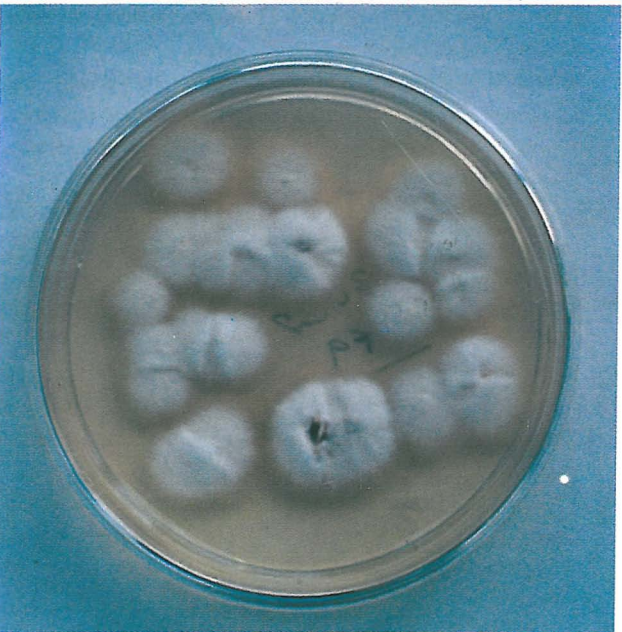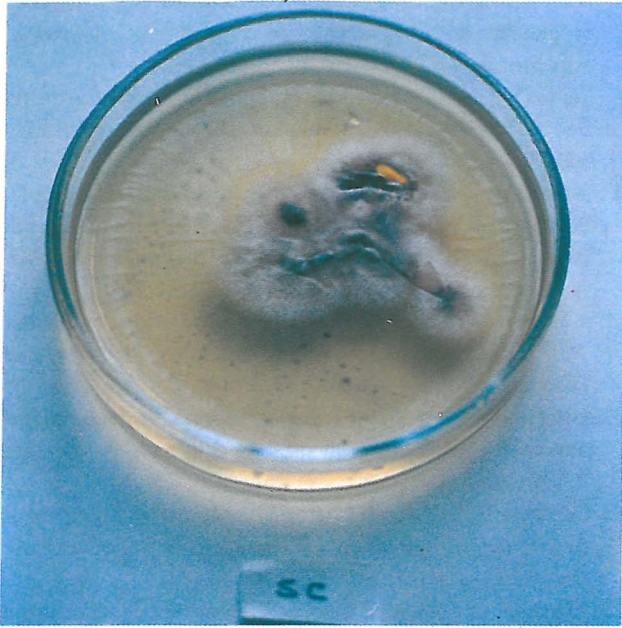


Fig. 4-a, b. Colonies of *Fusarium sp.* on Sabouraud's dex. agar, 6 days, 30°C.

therapy, the lesions subsided and the patient's condition improved clinically. A skin graft was performed, and the patient was discharged in January 1996.

#### DISCUSSION

This case of disseminated *Fusarium sp.* infection is reported for the first time in Iran from Pasteur Institute. Fungi of the genus *Fusarium* can cause disease in plants and animals.<sup>13,16,19</sup> In man there are reports of superficial infections in various sites such as the skin, cornea and

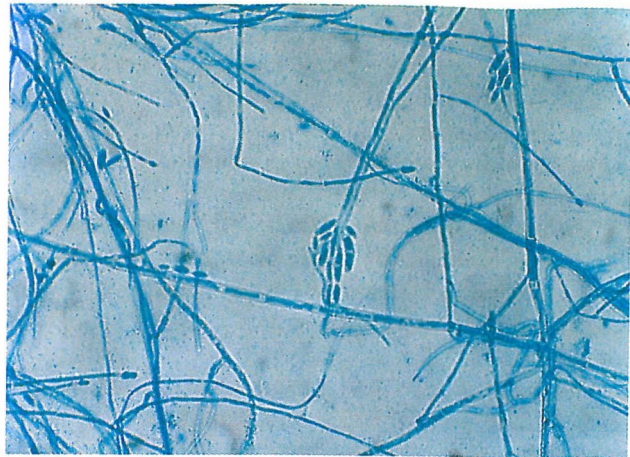

Fig. 5. Slide culture showing *Fusarium sp.* (Lactophenol cotton blue).

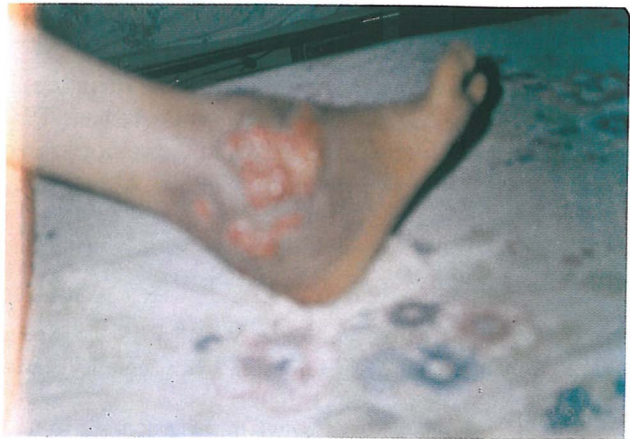

Fig. 6. Ulcer at the right ankle caused by *Fusarium sp.*

nails<sup>12,21,22</sup> and of localized organ infections including endophthalmitis,<sup>6</sup> arthritis,<sup>9</sup> cystitis,<sup>11</sup> peritonitis,<sup>10</sup> and keratitis.<sup>5</sup> However, systemic infection is rare. The first description of disseminated fusariosis was in 1973 in a child with acute lymphocytic leukemia.<sup>3</sup>

Systemic fungal infections with *Fusarium sp.* occur predominantly in immunocompromised patients.<sup>13</sup> This paper reports a case of disseminated fusariosis involving the skin and lungs, in a patient with chronic granulomatous disease. In the immunocompromised host however, especially in those in whom neutrophil and macrophage functions are deficient, it can cause devastating systemic infections.<sup>17</sup> Patients with CGD have disorders of neutrophil and monocyte oxidative metabolism. CGD results from inherited defects in the genes encoding the several components of NADPH oxidase, which generates superoxide.<sup>18</sup> Patients with chronic granulomatous disease are unable to generate a "respiratory burst" after stimulation of neutrophils and monocytes and are therefore unable to

## Disseminated Fusarium Infection in CGD

kill certain microorganisms. "Respiratory burst" results in the generation of superoxide ( $O_2^-$ ), hydrogen peroxide ( $H_2O_2$ ), and hypochlorite (OCI).<sup>4</sup> Leukocytes from patients with CGD have severely diminished hydrogen peroxide production. Although CGD is rare, occurring in about 1 in one million individuals, it is an important model of defective neutrophil oxidative metabolism.<sup>7</sup>

The homogeneity of the clinical presentation of fusarial infection is noteworthy. The most important clinical features are painful cutaneous nodules which are initially reddish but become rapidly necrotic. Severe myalgia is commonly seen.<sup>1,16</sup>

Our patient also had an infiltrative, edematous, erythematous, painful lesion and flaccid pustules on his right ankle. Some of the pustules developed central necrosis. The course of the infection in our patient was similar to that of most cases previously reported.

Our patient survived with antifungal treatment. This treatment included amphotericin B (1 mg/kg/day), and oral ketoconazole (150 mg/day). Amphotericin B remains the standard treatment.<sup>8</sup>

From this case and from a review of the literature, it appears that synergic antifungal agents may be beneficial in successful treatment of fusariosis in the compromised host.

### REFERENCES

1. Alvarez Franco M, Reyes Mugica M, Paller AS: Cutaneous fusarium infection in an adolescent with acute leukemia. *Pediat Dermatol* 9(1): 62-5, 1992.
2. Chandler FW, Kaplan WW, Ajello L: A color atlas and textbook of the histopathology of mycotic diseases. Lochem, Netherlands: Wolfe Pub., pp. 101-102, 1989.
3. Cho CT, Vats TS, Lowman JT, Brandsberg JW, Tosh FE: *Fusarium solani* infection during treatment for acute leukemia. *Journal of Pediatrics* 83: 1028-1031, 1973.
4. Stites DP, Terr AI: Basic and Clinical Immunology. 7th edition, Singapore: Prentice-Hall International Inc, p. 356, 1987.
5. Freidamk H: Hyalohyphomycoses due to *Fusarium sp.* Two case reports and review of the literature. *Mycoses* 38(1-2): 64-74, 1995.
6. Guss RB, Koenig S, De La Pena W, Marx M, Kaupman HE: Endophthalmitis after penetrating keratoplasty. *American Journal of Ophthalmology* 95: 651-658, 1983.
7. Gallin JI: Disorders of phagocytic cells. In: Wilson JD, Braunwald E, Isselbacher KJ, Petersdorf RG, Martin JB, Fauci AS, Root RK (eds.), *Harrison's Principles of Internal Medicine*. 12th edition, Vol. 1, New York: McGraw-Hill Co., p. 462, 1991.
8. Herbrecht R, Waller J, Dufour P, Koenig H, Liover B, Marcellin L, Oberling F: Rare opportunistic fungal diseases in patients with organ or bone marrow transplantation. *Agressologie*: 33 Spec. No. 2: 77-80, 1992.
9. Jakle C, Leek JC, Olson DA, Robbons DL: Septic arthritis due to *Fusarium solani*. *Journal of Rheumatology* 10: 151-153, 1983.
10. Kerr CM, Perfect JR, Craven PC, Jorgensen JH, Drutz D, Shelburne JD, Gallis HA, Gutman RA: Fungal peritonitis in patients on continuous ambulatory peritoneal dialysis. *Annals of Internal Medicine* 99: 334-337, 1983.
11. Lazarus JA, Scharawz LH: Infection of urinary bladder with an unusual fungus strain: *Fusarium*. *Urologic and Cutaneous Review* 52: 185-189, 1948.
12. Leu HS, Lee AY, Kuo TT: Recurrence of *Fusarium solani* abscess formation in an otherwise healthy patient. *Infection* 23(5): 303-5, 1995.
13. Lupinetti FM, Giller RH, Trigg ME: Operative treatment of fusarium fungal infection of the lung. *Ann Thorac Surg* 46(6): 991-2, 1990.
14. Mirshafii A: Study of mycotic keratitis and determination of fungal agents. Thesis for Ph.D. degree, School of Public Health, Tehran University, 1986.
15. Movahed Mohamadi M: Study of keratomycosis in Tehran hospitals and fungal contamination degree of operating rooms. Thesis for M.Sc. degree, School of Public Health, Tehran University, 1991.
16. Nucci M, Spector N, Lucena S, Bacha PC, Pulcheri W, Lamosa A, Derossi A, Caivby MJ, Maciera J, Oliveira HP: Three cases of infection with *Fusarium* species in neutropenic patients. *Eur J Clin Microbiol Infect Dis* 11: 1160-1162, 1992.
17. Prins C, Chaavaz P, Tam K, Hauser C: Ecthyma gangrenosum-like lesion: a sign of disseminated *Fusarium* infection in the neutropenic patient. *Clin Exp Dermatol* 20(5): 428-30, 1995.
18. Samuelson J, Lichtenberg FV: Inflammation and repair. In: Cotran RS, Kumar V, Robbins SL (eds.), *Pathologic Basis of Disease*. 5th ed, Philadelphia: W.B. Saunders Co., p. 63, 1984.
19. Booth C: The genus *Farium*. Hyalohyphomycosis. In: Rippon JW (ed.), *Medical Mycology: The Pathogenic Fungi and the Pathogenic Actinomycetes*. Philadelphia: W.B. Saunders, pp. 732-735, 1988.
20. Shidfar MR: Isolation and identification of etiologic agents of onychomycosis among the patients visiting the Medical Laboratory, School of Public Health in Tehran. Thesis for Ph.D. degree, Tehran University, 1992.
21. Weitzman I: Saprophytic molds as agents of cutaneous and subcutaneous infection in the immunocompromised host. *Archives of Dermatology*: 1161-1168, 1986.
22. Zapter RC, Arrechea A: Mycotic keratitis by *Fusarium*: a review and report of two cases. *Ophthalmologica* 170: 1-12, 1975.