

Original Articles

SURGICAL ASPECTS OF PEDIATRIC COCHLEAR IMPLANTATION

M. FARHADI, M.D., A. DANESH, M.D, AND H. IMAMJOMEH

From the ENT Dept. and Dept. of Audiology, Rasul Akram Medical Complex, Iran University of Medical Sciences, Tehran, Islamic Republic of Iran.

ABSTRACT

Since 1991, 90 cochlear implantations have been performed in the " cochlear center" of our department, including 57 children. This paper presents the results of 57 children who underwent cochlear implantation in the Iranian pediatric cochlear implant program. The surgical technique is described below. No flap problems were encountered, and no cholesteatoma or other complication was seen. In one child secondary operation was required due to fracture of the electrode array.

Keywords: Deafness, congenital, acquired; implantation, cochlea.

MJIRI, Vol. 11, No. 4, 281-284, 1998.

INTRODUCTION

After the successful performance of cochlear implantation in adults with acquired deafness,¹ we began to perform cochlear implantation in children with congenital deafness as well as those who had acquired their deafness prelingually.

The major factor in pediatric cochlear implantation is the ability and skill of the entire team, which is composed of an ENT specialist, psychiatrist, neuro-radiologist, speech therapist, audiologist, teacher of the deaf and a coordinator.^{4,5}

PATIENTS AND METHODS

Cochlear implantation was performed in 57 children according to the protocol of the Iranian Cochlear Implantation Center (ICIC). 31 of the patients were female and 26 were male. Their age ranged between 2 and 11 years old. 44 of the children were congenitally deaf, 6 had prelingual deafness and 7 had acquired deafness.

The average age of the children with congenital deafness was 6.5 years old, while the average age of the children with

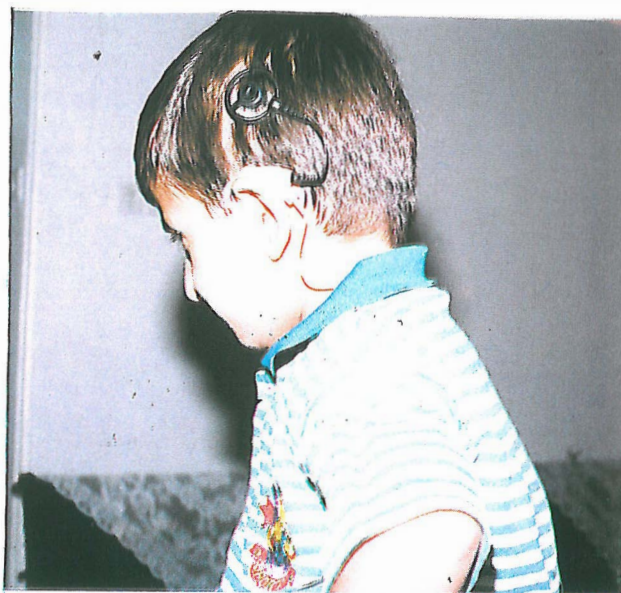

Fig. 1. Two and a half year old child with cochlear implant.

acquired deafness was 9 years old.

44 patients received multichannel Mini-system 22 and 3

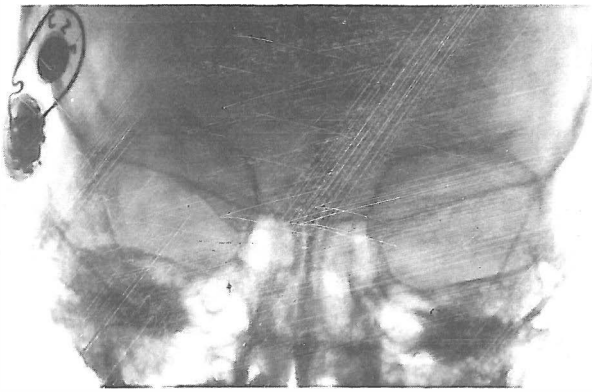


Fig. 2. Insertion of electrode array in transorbital view.

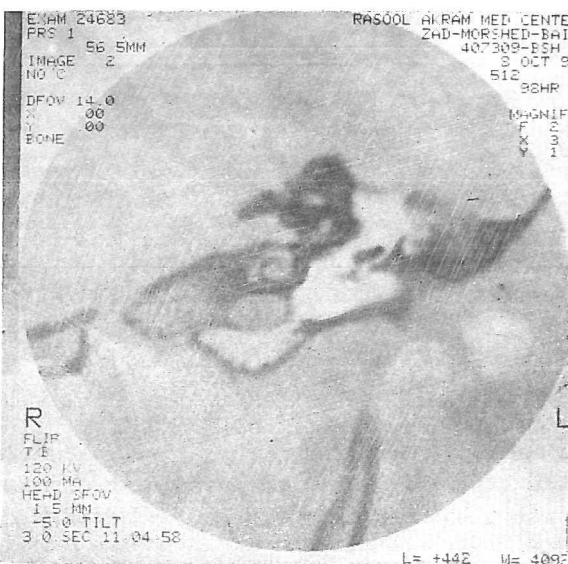
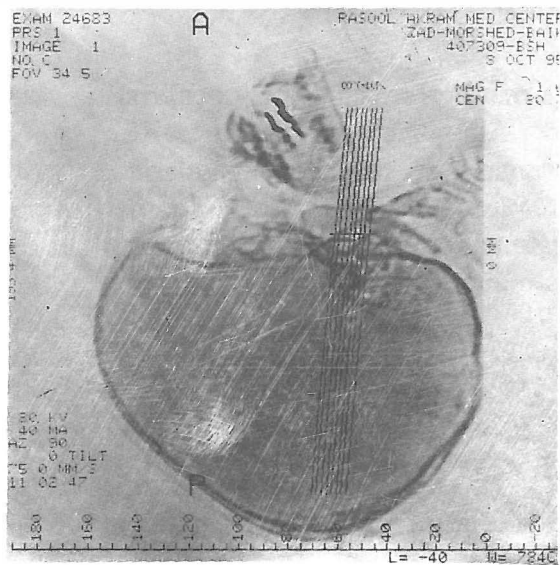


Fig. 3, (A,B). The cochlear duct (A) and IAC (B) are clearly visible in the patient's CT scan.

received a single channel device. The importance of a complete medical preoperative evaluation is stressed. This comprises general medical, otological and radiological assessment.⁴ Also we emphasize the importance of family motivation and the social and educational environment in the selection period at the otological assessment.

Three patients demonstrated secretory otitis media and were treated before operation. Two children demonstrated bilateral scarring of the tympanic membranes. One child suffered from epilepsy and was referred to the pediatric service for assessment and management. Ten patients underwent anti-epileptic therapy prior to surgery.

SURGICAL TECHNIQUE

The ear to undergo cochlear implantation was chosen preoperatively based on audiological, radiological and otological findings (Fig. 1)⁷ and promontory stimulation test. It also must be free of disease, such as infection or a perforated ear drum. After preparation using an iodine-based compound, an extended endaural incision (Lindhart incision) was used in all cases. A separate periosteal flap was not created and no flap thinning was carried out.^{2,4}

After carrying out a simple mastoidectomy, the implant site was prepared. A posterior tympanotomy (facial recess extended) was then carried out, leaving a buttress of bone adjacent to the fossa incudis.

A routine cochleostomy anterior and inferior to the round window membrane was used rather than utilizing the round window approach.^{1,2,3} All children received preoperative antibiotic coverage as well as an antibiotic based wound irrigation solution.

All children with CI 22 were examined during surgery by means of the electrically-elicited stapedius reflex. A stapedius reflex could visually be detected for all subjects. The posterior tympanostomy was sealed with fascia and muscle. Meticulous hemostasis was carried out prior to closure. Drains were not used and a pressure dressing was applied for 3 days.

Initially, conventional suturing material was used but later closure was performed with subcuticular vicryl. The day after the operation we checked the position of the electrode array in the cochlear duct by the transorbital view (Fig. 2).^{8,12}

RESULTS

Full insertion was achieved in 42 children. In 12 children, between 14 and 20 electrodes were inserted and 3 children had less than 10 inserted.

In one child the operation was abandoned because of failure to detect a lumen due to a completely ossified

Table I. Summary of map 17 created on 01-Sep-95 at 15:58 with V6.100.

Chan.	Mode	T-level	C-level	Range	Freq. Bounds		Gain
					Lower	Upper	
21	CG	60	160	100	150	350	8
20	CG	40	162	122	350	550	8
19	CG	40	162	122	550	750	8
18	CG	25	164	139	750	950	8
17	CG	45	164	119	950	1150	8
16	CG	62	166	104	1150	1350	8
15	CG	68	166	98	1350	1550	8
14	CG	75	168	93	1550	1768	8
13	CG	65	170	105	1768	2031	8
12	CG	62	168	106	2031	2333	8
11	CG	60	168	108	2333	2680	8
10	CG	44	166	122	2680	3079	8
9	CG	62	166	104	3079	3571	8
8	CG	75	164	89	3571	4184	8
7	CG	100	165	65	4181	4903	8
6	CG	95	162	67	4903	5744	8
5	CG	85	162	77	5744	6730	8
4	CG	72	160	88	6730	7885	8
3	CG	65	160	95	7885	9238	8
2	CG	55	158	103	9238	10823	8

The T stimulus level has been modified by 0%;

The C stimulus level has been modified by 0%;

Base Level=1; Encoder Strategy: SPEAK;

Optimum sensitivity setting = 2.5 for Spectra 22 332618;

Loudness growth Q value = 20; Autosensitivity on S position = Yes;

Average number of maxima = 6;

Frequency allocation table =9.

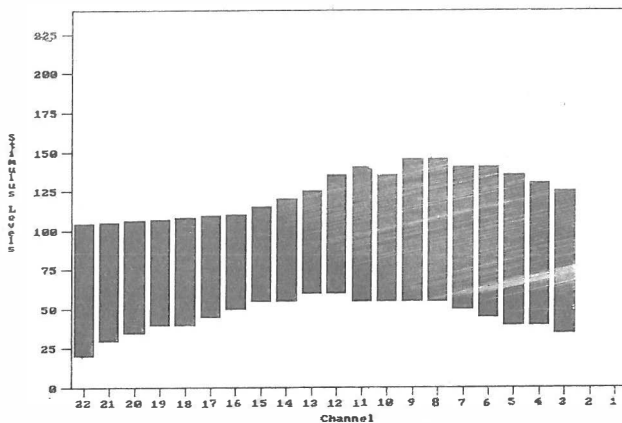


Fig. 4. Plot of T and C-levels for patient N.M. on 16-JUL-97.

cochlea (cochlear duct was open on CT scan) (Fig. 3). In 5 patients difficulty was experienced during insertion and in 3 cases gusher occurred during the surgery which was sealed by portions of muscle and one of them had common cavity malformation.

One patient underwent operation twice due to some kind of malfunction in the electrode array after performing the

integrity test. The prosthesis was replaced with a new one and now he is in the process of rehabilitation.⁹

No incorrect electrode position, 7th nerve stimulation, meningitis, vestibular problem, flap necrosis or hematoma was experienced. Only in two cases minor wound infection developed which was treated successfully with antibiotics. There was no cholesteatoma and no prosthesis rejection.^{6,9,11}

45 days after operation and performing auditory mapping and fitting, auditory rehabilitation was begun (Fig. 4, Table I).

DISCUSSION

Successful surgical implantation of an intracochlear device requires accurate preoperative assessment, otologically and radiologically, and careful preoperative general medical evaluation is essential. Other general medical conditions do not necessarily contraindicate cochlear implant surgery.

During the surgical phase a number of factors contribute to the success of the procedure. We believe the extended endaural incision offers the best results with the least chance

of wound dehiscence.^{1,6,9}

In cases where the facial nerve has been exposed, the nerve is subsequently protected with a silastic sheet. Sacrifice of the chorda tympani is to be avoided in a child who already has other major sensory deficits, but nonetheless may have to be carried out in a limited number of cases in order to gain adequate surgical access through the posterior tympanotomy.^{9,11} A separate cochleostomy provides a more direct route of access to the cochlea.^{4,6}

We believe wound drains are unnecessary as long as careful and meticulous hemostasis is carried out, but a firm pressure dressing is applied. Subcuticular suturing avoids the postoperative trauma of suture removal in young children.

Infection can be avoided by a combination of meticulous surgical technique coupled with pre- and intraoperative use of antibiotics. Wound irrigation with antibiotics may be of additional benefit.

Our results show a very low complication rate and are comparable with those of prominent otological surgery centers.^{10,12}

REFERENCES

1. Farhadi M, Danesh A, Imamjomeh H: Cochlear implantation in Iran. *Med J Islamic Rep Iran* 8 (2): 71-4, 1994.
2. Patrick JF, Clark GM: The Nucleus 22-channel cochlear implant system. *Ear and Hearing* 12 (4) (suppl): 3, 1991.
3. Clark GM, Franz BK, et al: Surgery for multichannel cochlear implantation. In: Cooper HUW, (ed), *Cochlear Implants: A Practical Guide*. London: Whurr Publisher Ltd., pp.9-32, 1991.
4. Miyamoto RT, et al: Medical and surgical issues. *Otology* 12: 18-21, 1991.
5. House WF, Berliner KI: Cochlear implants: from idea to clinical practice. In: Cooper HUW, (ed), *Cochlear Implants: A Practical Guide*. London: Whurr Publisher Ltd., pp. 9-32, 1991.
6. Ledenhardt E: Cochlear Implant Mini-System 22 for the management of deaf preschool children. *HND* 38 (5): 161-5, 1990.
7. Wiet RJ, et al: Computed tomography: how accurate a predictor for cochlear implantation? *Laryngoscope* 100 (7): 687-92, 1991.
8. Deguine D, Frayss B, et al: Predictive factors in cochlear implant surgery. In: Frayss B, (ed). *Cochlear Implants: New Perspectives*. Basel: Karger, pp. 144-5, 1993.
9. Webb RL, Ledenhardt GM, Clark GM, Laszing R, Pyman BC, Burkhard KHGF: Surgical complications with the cochlear multiple channel intracochlear implant: experience at Hannover and Melbourne. *Ann Otol Rhinol Laryngol* 100: 131-6, 1991.
10. Cohen NL, Hoffman RA, Stroschein M: Medical or surgical complications related to the Nucleus multichannel cochlear implant. *Ann Otol Rhinol Laryngol* 97 (suppl 135): 8-13, 1988.
11. Gibson W, Lam P, Scrivener B: The operative and postoperative complications encountered in 100 cochlear implant surgeries- the Sydney experience. *J Otolaryngol Soc Aust* 6: 399-404, 1991.
12. Clark GM, Cohen NL, Shepherd V: Surgical and safety considerations of multichannel cochlear implants in children. *Ear and Hearing* 12 (Suppl): 15s-24s, 1991.