

ASSESSMENT OF TUMOR MARKERS IN BENIGN, DYSPLASTIC AND MALIGNANT ORAL MUCOSAL LESIONS

BEHJAT K.H. MOGHADAM,* D.D.S., D.Sc.D., ISMAIL YAZDI,**
D.M.D., AND HOURI FATOREHGHI***

*From the School of Dentistry, University of Missouri-Kansas City, 650 E. 25th Street, Kansas City, Missouri
64108, U.S.A.*

ABSTRACT

Immunohistochemical demonstration of tumor-associated markers may be valuable as an adjunct to conventional histology for determination of malignancy development in oral mucosal diseases. Accordingly, the present study determined the distribution of some important tumor markers such as heat shock proteins (HSP), fibroblast growth factors (FGF) and transferrin receptors (TF-R) in 22 samples of primary oral squamous cell carcinoma (SCC) and in 18 hyperplastic/dysplastic oral lesions. Fifteen samples of normal buccal mucosa were included for comparison. Serial sections taken from frozen tissues and paraffin-embedded samples were stained immunohistochemically using monoclonal antibodies against HSP, FGF and TF-R. Results showed that normal tissues had only a detectable level of HSP and FGF while dysplastic tissues had a higher level of HSP and FGF expression. Oral SCCs demonstrated the highest level of HSP and FGF expression distributed widely across the tumor specimens. TF-R expression was detected only in cryostat sections with low immunoreactivity seen in normal tissues, and the highest level of immunoreactivity detected in malignant tissues. Expression of TF-R in paraffin-embedded sections was non-specific and was masked by fixation methods used to process these tissues. It is concluded that HSP and FGF are largely expressed by malignant cells indicating that over-expression of these markers in mucosal lesions might be a reflection of malignancy. Secondly, these markers are preserved well in paraffin-embedded sections and finally, expression of TF-R correlates with rapid cell proliferation but its assessment is highly specific and is only accurate in cryostat sections.

Keywords: Tumor markers; immunohistochemistry; Oral cancer; growth factors.

MJIRI, Vol. 11, No. 4, 289-294, 1998.

*Associate Professor, Department of Diagnostic Sciences, UMKC School of Dentistry, **Professor, Department of Oral Pathology, Tehran University of Medical Sciences, School of Dentistry, Visiting Professor, USA, ***Current Student, D.D.S. Program, UMKC School of Dentistry.

Correspondence: B.K.H. Moghadam, D.D.S., D.Sc.D., University of Missouri-Kansas City, School of Dentistry, 650 E. 25th Street, Kansas City, Missouri 64108, U.S.A., Tel. (816) 235-2100, Fax: (816) 235-2157.

INTRODUCTION

The significance of various molecular alterations associated with premalignant and malignant conditions of oral mucosa is currently under extensive investigations. The most recent studies point out the amplification and over-expression of growth factors,^{4,10} growth factor receptors¹⁹ and oncogene-products¹¹ in a variety of malignant cell-lines including oral squamous cell carcinoma (SCC).^{4,10,14} These growth factor proteins are thought to play an important biological role in the initiation and progression of tumor cells. Fibroblast growth factors (FGFs) have a widespread distribution in normal tissues as well as neoplastic conditions.³ FGFs are involved in a variety of activities which include angiogenesis, mitogenesis, and wound healing.⁶ The importance of FGF receptor expression in myoblast generation and in prostate cancer is also documented.²¹ Recently, cell-lines derived from oral SCC(s) have been shown to express FGFs in culture.¹³

Increased synthesis of heat shock proteins (HSP, stress-induced proteins) is also found in a variety of human cells in response to non-lethal stimuli such as viral infection, growth factor deprivation, and malignant transformation.^{1,17} Tumor cell expression of HSP may reflect the degree of tumorigenicity of malignant cells.^{7,8,18}

Over-expression of transferrin receptors (TF-R) is an additional marker which can reflect the growth capacity of a neoplasm.^{2,9,16,19,20} TF-R is a cell membrane glycoprotein and mediates iron uptake via internalization of transferrin, an iron-carrying serum protein.²

Immunohistochemical detection of rapidly growing cells is valuable for assessment of malignant and premalignant conditions in routine histological examination of oral lesions. The purpose of the current study was to determine the value of immunohistochemical localization and the tissue distribution of FGF, HSP and TF-R in normal, dysplastic and malignant oral mucosa and to relate them to their cell-line occurrence reported in the literature.

MATERIAL AND METHODS

Tissue specimens

Cryostat sections and formalin-fixed paraffin-embedded tissues were available from twenty-two primary oral squamous cell carcinoma (SCC) and eighteen cases of hyperplastic/dysplastic oral lesions. The SCC(s) were graded as; well differentiated (n=14), moderately differentiated (n=6) and poorly differentiated (n=2). The hyperplastic/dysplastic lesions were graded as; benign acanthosis/hyperkeratosis (n=9), mild to moderate dysplasia (n=7), severe dysplasia [carcinoma in situ (n=2) and papilloma (n=1)]. Fifteen samples of normal buccal mucosa were included for comparison.

Immunohistochemical staining

From each block, 5µm serial sections were deparaffinized by heating for 24 hours in 56°C and subsequently immersing in xylenes and graded alcohol changes two times, each at 10 minute intervals. The deparaffinized sections were then treated with 1% hydrogen peroxide to block endogenous peroxidase activity.

The cryostat sections were first air dried, and then fixed in cold acetone for 10 minutes at room temperature (RT). Following 10 minutes washing in two changes of distilled water, both the deparaffinized and cryostat sections were incubated for 20 minutes first with 0.05% saponin (Sigma) and then with a protein blocking agent (10% normal goat serum) to reduce the non-specific reactions. The initial step of immunohistochemical staining involved an overnight incubation of deparaffinized sections with assigned primary antibodies. Cryostat sections were incubated with related antibodies for 60 minutes at RT.

The primary monoclonal antibodies used were 1:10 dilution of anti-FGF receptor (Ab-1), anti-heat shock protein (HSP 72/73-Ab-1), and anti-transferrin receptor (OKT9). The first two monoclonals were obtained from Oncogene Science, Inc., San Diego, CA and OKT9 was obtained from Ortho Diagnostic, Inc., Kansas City, MO, USA.

Incubation with primary antibodies was terminated by two washes in PBS (phosphate-buffered saline, pH 7.2) for five minutes each. All sections were then incubated first with multilink biotinized secondary antibodies, and then with peroxidase conjugated streptavidin label (Biogenex Super Sensitive Multilink Kit, San Ramon, CA). Incubation was 20 minutes at RT. Sections were washed for 10 minutes in two changes of PBS between each step. Immunohistochemical staining was accomplished by incubation of sections with AEC chromogen (from the kit) for 5-10 minutes at RT. Following two washes in distilled water, sections were counterstained with hematoxylin and mounted for microscopic examination.

Control sections

Positive tissue controls were sections of breast cancer which is known to express HSP, FGF and TF-R. Negative controls were non-immune sera and PBS in place of primary antibodies.

The intensity of the staining in each section was assessed by using a semiquantitative scoring system: no staining (-), barely staining (±), weak staining (+), moderate staining (+2), strong staining (+3), and highly strong staining (+4).

RESULTS

The overall results of the study are briefly summarized in Table I.

Table I. Results of the study.

	Paraffin Embedded Sections			Cryostat Sections		
	Normal	Hyperplastic/Dysplastic	Malignant	Normal	Hyperplastic/Dysplastic	Malignant
HSP	Prickle cells (±) Basal cells (+).	Benign hyperplastic (±) Only dysplastic cells stained (+2), (+3)	The majority of the cells (>95%) stained (+3), (+4)	Similar to paraffin embedded sections		The majority of the cells (>95%) stained (+3), (+4).
FGF	Prickle cells (±) Basal cells (+)	Benign hyperplastic (±) Only dysplastic cells stained (+2), (+3), (+4)	The majority of the cells (>95%) stained (+2), (+3), (+4)	Similar to paraffin embedded sections		The majority of the cells (>95%) stained (+4).
TF-R	Was not detected in paraffin-embedded sections			90% of the basal and suprabasal cells stained (+2)	Benign hyperplastic lesions (+) Dysplastic lesions (+3)	100% of the cells stained (+4).
Intensity of staining was determined as no staining (-), barely staining (±), light staining(+), moderate staining (+2), strong staining (+3), and very strong staining (+4).						

Normal tissues

The staining pattern of cryostat sections and paraffin embedded samples of normal buccal mucosa was similar for distribution of HSP. A detectable level of HSP was found in all epithelial cells in various anatomical zones with a relatively weak staining intensity (±). Increased intensity level (+) was found in basal cell and suprabasal cell layers and in epithelial components of minor salivary glands.

A similar immunoreactivity of normal tissue specimens was found for FGF expression. Results of the study with OKT9 were inconclusive and non-specific for distribution of TF-R in paraffin-embedded sections. However, all of the cryostat sections stained with OKT9 at the basal cell and suprabasal cell layer (approximately 90% of the cells). Some basal cells as well as all the epithelial cells in the upper anatomical zones did not stain. The immunoreactivity for TF-R was demonstrated by a bright red reaction at the cell membrane of all positive cells with (+2) intensity level (Fig. 1).

Benign and dysplastic mucosal lesions

Seven of the nine benign mucosal lesions without dysplasia had only detectable levels of HSP with weak (±) to moderate (+2) staining intensity found in deep prickly cell layers. Two samples did not stain. Immunoreactivity with FGF was found in 9/9 benign mucosal lesions with moderate (+2) intensity (Fig. 2).

All dysplastic mucosal lesions (n=7) with mild to moderate dysplasia had positive focal staining for HSP and FGF in distinct regions of tissues with dysplasia. The staining intensity in dysplastic areas varied from moderate

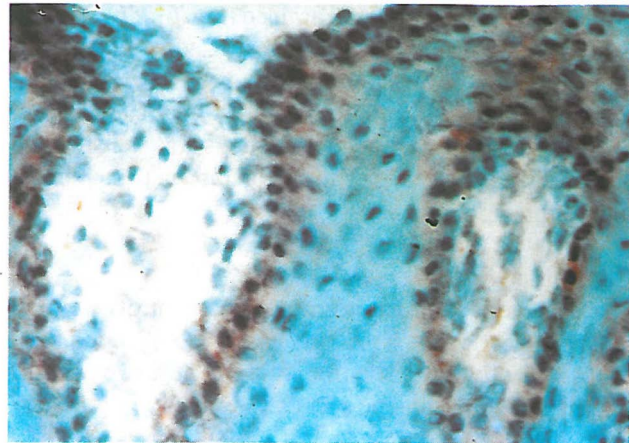


Fig 1. Selective expression of TF-R at the cell membrane of basal and suprabasal cells of normal buccal mucosa (frozen section) (×400)

(+2) to strong staining (+3) and was focal in distribution in most cases. There was an increase in the distribution and intensity of staining (+4) in severe dysplastic mucosal lesions categorized as carcinoma in situ bordering on early SCC (Fig. 3).

TF-R immunoreactivity was localized only in cryostat sections and was found in basal cell and suprabasal cell layers in benign lesions. In dysplastic lesions the TF-R immunoreactivity was stronger in intensity (+3) and was found as focal staining in epithelial cells with loss of polarity and increased dysplasia.

Oral malignant lesions

Immunoreactivity with HSP was found in 12/14 well

differentiated SCCs, and in all moderately differentiated (n=6) and poorly differentiated (n=2) samples of oral SCCs examined in this study. The intensity of the staining varied from weak staining (+) in four cases to moderate staining (+2) in five, strong reaction (+3) in nine and highly strong staining (+4) in two tissues examined. Some samples had focal staining in distribution and many had the majority of malignant cells stained positively for HSP (Fig. 4).

FGF immunoreactivity was detected in all 22 primary oral sections. The intensity of the staining for FGF varied from (+) in four cases to (+2) in three sections, (+3) for seven and (+4) for eight cases of malignant sections (Fig. 5). The overall staining intensity of FGF was much stronger than that of HSP. The FGF-positive cells were evenly distributed across the entire bulk of the tumors. The intensity of the staining was particularly stronger in the highly anaplastic regions of the same tumor with different degrees of differentiation. The staining pattern for both HSP and FGF was cytoplasmic with occasional positive nuclear staining of malignant cells for FGF.

TF-R staining was detected as a strong cell membrane reaction only in the cryostat sections obtained from all primary oral SCC samples examined (Fig. 6). The staining pattern within each section was restricted specifically to the cell membrane of all the malignant cells corresponding to the anatomical distribution of TF-R. Immunoreactivity of TF-R in paraffin embedded sections was indistinctive and much less specific with no precise cell membrane immunoprecipitations.

Control sections

Sections of breast cancer (positive control) were all positive for expression of HSP, FGF and TF-R. Immunoreactivity was not found in any negative controls treated with non-immune sera or PBS in place of primary antibodies.

DISCUSSION

Previous studies have shown that tumor cells produce FGF,^{3,13} HSP^{1,7} and TF-R^{2,9} both *in vivo* and *in vitro*. The current study determined the tissue distribution and in situ synthesis of these cell markers in normal, benign, dysplastic and malignant oral mucosal lesions. The existence of these tumor markers was determined by immunohistochemical demonstration of positive cells in various anatomical zones of tissues under investigation.

Sections of normal tissues had only detectable levels of FGF and HSP. The staining distribution of benign lesions was similar to that seen in normal oral mucosa. The dysplastic lesions, however, demonstrated an increased level of staining in anaplastic regions with many dysplastic cell staining more positively for HSP and FGF. A widespread

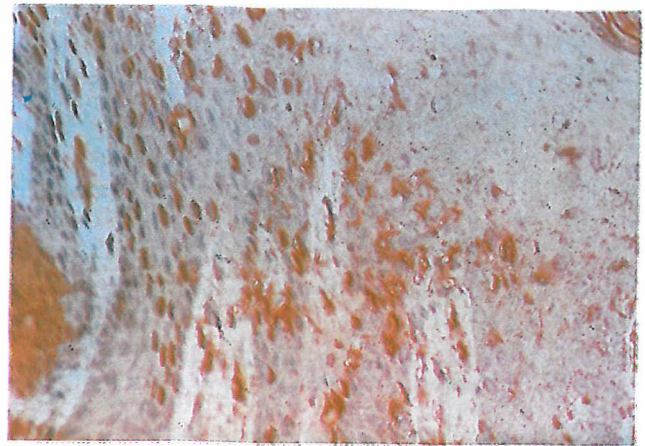


Fig 2. Expression of FGF in a hyperplastic mucosal lesion (×200).

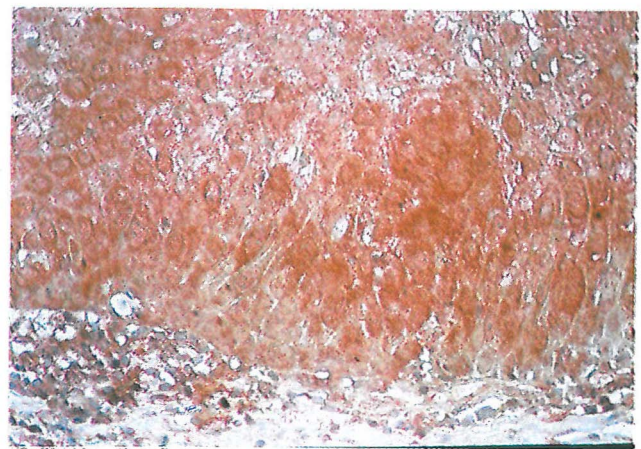


Fig 3. Increased staining intensity of FGF was found in mucosal lesions with severe dysplasia (carcinoma in situ) (×200).

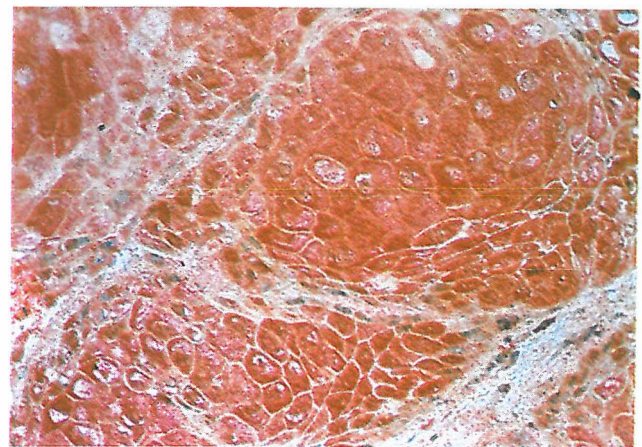


Fig 4. The majority of malignant cells stained strongly positive for HSP (×400).

and strong staining intensity of HSP and FGF was found within individual malignant cells and in those cells arranged in groups and clusters making up the bulk of the tumor.

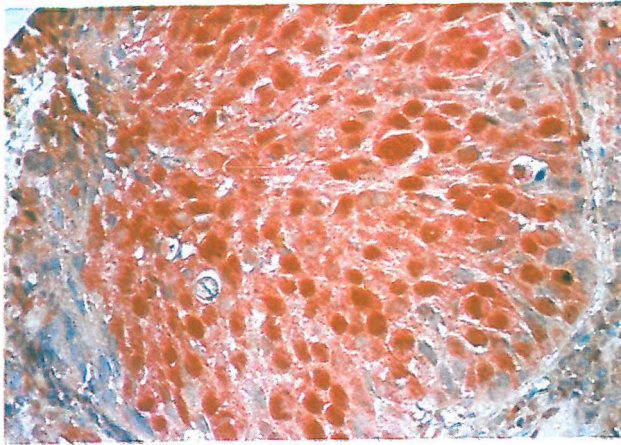


Fig 5. Strong immunoreactivity of oral malignant cells with FGF (×400).

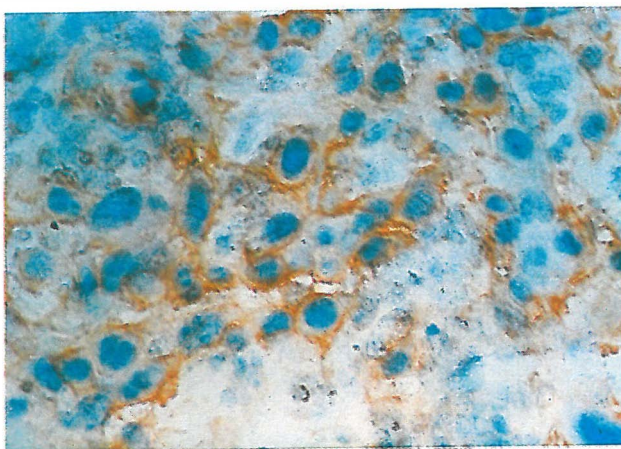


Fig 6. Expression of TF-R at the cell membrane of malignant cells in a frozen section of oral SCC (×400).

These observations indicate that expression of HSP and FGF is related to increasing dysplasia and loss of differentiation in oral epithelial cells. The enhanced production of these antigens is apparently a reflection of an active growth and development of malignancy in oral lesions. In addition, the apparent immunohistochemical determination of HSP and FGF in paraffin-embedded sections in the current study indicate that the stability of these antigens is not affected by formalin fixation and the methods used to process these tissues. As such, detection of these markers may have a diagnostic value in early detection of a malignant condition in routine histopathological examinations of mucosal tissues.

Results of staining with anti-transferrin antibody (OKT9) in cryostat sections of normal mucosa indicated that only the epithelial cells of basal and suprabasal layers expressed a high level of TF-R. These results are in agreement with other reports that TF-R is largely expressed by less-differentiated cells than by well-differentiated or mature cells.^{2,9} The negative staining of some basal cells is consistent

with the fact that not all the basal cells can divide and those cells capable of dividing comprise a number of sub-populations in this anatomic zone.¹⁵ The selective expression of TF-R on basal and suprabasal cells confirms the role of iron and proteins of iron metabolism in epithelial cell proliferation.

Expression of TF-R was identified as strong cell membrane staining in the majority of malignant cells in all the cryostat sections obtained from SCCs. A particular problem was the detection of TF-R receptors in paraffin-embedded sections. The staining pattern in these tissues was non-specific and was much weaker than that of cryostat sections. It is likely that TF-R antigens had deteriorated during the tissue-fixation procedures. Support for this explanation may be derived from the literature which showed that the majority of studies used cryostat sections to determine TF-R distribution.^{12,15} There is one study, however, which has employed paraffin-embedded sections to demonstrate TF-R distribution in lung cancer.⁹ This study used a special fixation method different from that used to process tissues in the current study. It is essential, therefore, to evaluate the effect of different types of fixation on TF-R antigen preservation when employing paraffin-embedded tissues for detection of TF-R positive cells. Also, caution must be exercised in assessment of staining intensity of TF-R in paraffin-embedded sections, since the best results are obtained from frozen sections.

In conclusion, expression of HSP and FGF is up-regulated in malignant conditions. As such, their immunoreactivity may be a valid marker for assessment of malignancy development in oral mucosal diseases. Secondly, the precise immunohistological demonstrations of these markers in paraffin embedded tissues, extend the use of these tissues for detection of HSP and FGF in pathological sections. Finally, despite the limitation of paraffin embedded section use in detection of TF-R, the assessment of this particular cell marker in frozen sections is quite easy and satisfactory and accurately reflects the degree of cellular reactivity.

REFERENCES

1. Ciocca D, Clark G, Tandon A, et al: Heat shock protein HSP 70 in patients with axillary lymph node-negative breast cancer; prognostic implications. *J Natl Cancer Inst* 85: 570-4, 1993.
2. Gatter KC, Brown G, Trowbridge IS, et al: Transferrin receptors in human tissues: their distribution and possible clinical relevance. *J Clin Pathol* 36: 539-45, 1983.
3. Gospodarowicz D, Neufeld G, Schweigerer L: Molecular and biological characterization of fibroblast growth factor, an angiogenic factor which also controls the proliferation and differentiation of mesoderm and neuroectoderm derived

- cells. *Cell Differ* 19: 1-17, 1986.
4. Grandis JR, Tweardy DJ: Elevated levels of transforming growth factor- α and epidermal growth factor receptor messenger RNA are early markers of carcinogenesis in head and neck cancer. *Cancer Res* 53: 3579-84, 1993.
5. Hume WJ: Changing concepts of oralepithelium: discussion paper. *JR Soc Med* 84: 92-94, 1991.
6. Johnson D, Lee P, Lu J, et al: Diverse forms of a receptor for acidic and basic fibroblast growth factors. *Mol Cell Biol* 10(9): 4728-36, 1990.
7. Kaur J, Srivastava A, Ralhan R: P 53-HSP 70 complexes in oral dysplasia and cancer: potential prognostic implications. *Oral Oncol, Eur J Cancer* 32B(1): 45-9, 1996.
8. Kimura E, Enns R, Alcaraz J, et al: Correlation of the survival of ovarian cancer patients with mRNA expression of the 60-ke heat-shock protein HSP-60. *J Clin Oncol* 11: 891-8, 1993.
9. Kondo K, Noguchi M, Mukai K, et al: Transferrin receptor expression in adenocarcinoma of the lung as a histopathologic indicator of prognosis. *Chest* 97: 1367-71, 1990.
10. Kramer S, Reynolds FH Jr, Castillo M, et al: Immunological identification and distribution of parathyroid hormone-like protein polypeptides in normal and malignant tissues. *Endocrinology* 128: 1927-37, 1991.
11. Levine AJ, Momand J, Finlay CA: The P53 suppressor gene. *Nature* 351: 435-6, 1991.
12. Miyamoto T, Tanaka N, Eishi Y, et al: Transferrin receptor expression in oral tumors. *Int J Oral Maxillofac Surg* 23: 430-3, 1994.
13. Myoken Y, Myoken Y, Okamoto T, et al: Immunocytochemical localization of fibroblast growth factor-1 (FGF-1) and FGF-2 in oral squamous cell carcinoma (SCC). *J Oral Pathol Med* 23: 451-6, 1994.
14. Prime SS, Game SM, Matthews JB, et al: Epidermal growth factor and transforming factor- α characteristics of human oral carcinoma cell lines. *Br J Cancer* 69: 8-15, 1994.
15. Schneider C, Newman RA, Sutherland DR, et al: Structural features of the cell surface receptor for transferrin that is recognized by the monoclonal antibody OKT9. *J Biol Chem* 257: 8516-22, 1982.
16. Soyer HP, Smolle J, Torne R, et al: Transferrin receptor expression in normal skin and in various cutaneous tumors. *J Cutan Pathol* 14(1): 1-5, 1987.
17. Srivastava P, Maki R: Stress-induced proteins in immune response to cancer. *Curr Top Microbiol Immunol* 167: 109-23, 1991.
18. Sugerman P, Savage N, Xu L, et al: Heat shock protein expression in oral epithelial dysplasia and squamous cell carcinoma. *Oral Oncol, Eur J Cancer* 31 B(1): 63-7, 1995.
19. Trowbridge IS, Omary MB: Human cell surface glycoprotein related to cell proliferation is the receptor for transferrin. *Proc Natl Acad Sci USA* 78: 3039-43, 1981.
20. Walker RA, Day S: Transferrin receptor expression in non-malignant and malignant human breast tissue. *J Pathol* 148: 217-24, 1986.
21. Yan J, Fukabori Y, McBride G, et al: Exon switching and activation of stromal and embryonic fibroblast growth factor (FGF)-FGF receptor genes in prostate epithelial cells accompany stromal independence and malignancy. *Mol Cell Biol* 13(8): 4513-22, 1993.