

PRIMARY LOCALIZED RETROPERITONEAL AMYLOID TUMOR WITH OSSEOUS METAPLASIA: CASE REPORT AND REVIEW OF THE LITERATURE

T. GHIASI,* M.D., P. RAOFIAN,**M.D., AND S. NORUZPOUR,***
M.D.

*From the Department of Pathology, Ghaem Hospital, Mashhad University of Medical Sciences,
Mashhad, and the **Sina Hospital, Reza Avenue, Mashhad, Islamic Republic of Iran.*

ABSTRACT

Amyloidoma or amyloid tumor is a tumor-like localized deposit of amyloid encountered occasionally in association with multiple myeloma, various chronic inflammatory diseases and primary amyloidosis.

Amyloid tumors unassociated with plasmacytoma or other disease are extremely rare in soft tissues and few cases in various situations have been reported.

Histologic examination discloses amorphous eosinophilic material that stains positive with congo red preparation, and shows apple-green birefringence under polarized light. The deposits are surrounded by more or less prominent chronic inflammatory cells, especially plasma cells and giant cells. Cartilage formation and ossification, however, occur in some amyloid tumors.

Keywords: Tumor, amyloid, retroperitoneal; metaplasia, osseous.

MJIRI, Vol. 11, No. 4, 369-372, 1998.

INTRODUCTION

Amyloidoma or amyloid tumor refers to localized tumor-like deposits of amyloid which are associated with multiple myeloma, various chronic inflammatory diseases and primary amyloidosis.

Amyloid tumors are extremely rare in soft tissues without concomitant plasmacytoma or other diseases as only a few cases have been reported in the breast, eye, thigh, mediastinum,² central nervous system, urethra, bladder, lung, thyroid, rectum, larynx, trachea, stomach and palate.

Microscopically, deposits of amorphous eosinophilic material are seen which stain positive with congo red and have green birefringence under polarized light. Chronic inflammatory cells, especially plasma cells, surround the deposits and rarely cartilage or osseous metaplasia are seen.

Case report

The patient is a 44 year old woman who noticed a slightly painful rounded mass in her abdomen 7 years ago which had begun growing since last year. All blood examinations, serum protein electrophoresis and immunoelectrophoresis and bone radiographs were normal. Bence-Jones protein was negative in urine. We did not find any other abnormal findings in her physical examination. The patient underwent laparotomy, and a retroperitoneal and intrapelvic mass was discovered which had adhesion to the iliac veins.

Correspondence: T. Ghiasi, M.D.,
Department of Pathology, Ghaem Hospital, Mashhad, IRAN,
91735 Fax: (051) 809612 Tel: (051) 800001-9

* Assistant Professor of Pathology

** General Surgeon

*** Resident of Pathology

Retroperitoneal Amyloid Tumor with Osseous Metaplasia

Pathologic findings

Macroscopically the mass was 14×10×8 cm in diameter, of hard consistency in most areas and had a brown to white color in cut surfaces (Figs. 1, 2.). Microscopic examination showed lymphocyte and plasmocyte infiltration with fibrosis and deposits of eosinophilic material (Figs. 3, 4) which were positive with congo red staining and had green birefringence under polarized light (Fig. 5) and showed areas of osseous metaplasia (Fig. 6).

DISCUSSION

Amyloid tumor is referred to as tumor-like localized deposits of amyloid material which is associated with multiple myeloma and other various chronic inflammatory diseases.⁷ Amyloid tumor is also associated with primary amyloidosis without any other disease which is rare and usually seen as solitary or multiple nodules in genitourinary, gastrointestinal and respiratory tracts. These nodules are usually large, and present with signs and symptoms of pressure which compress adjacent organs.² Typical examples of amyloid tumor are seen in the palate, stomach, ureter, larynx, trachea and especially in the lungs.⁷

Amyloid tumor without concomitant plasmacytoma or other disease is extremely rare in soft tissues and only a few cases have been reported.⁷ One case of this tumor was in the soft tissue of the neck of a 46 year old man which had presented as a large and lobulated mass deep to the sternocleidomastoid and internal jugular vein for a period of 6 years. The other case was in the femoral triangle of an 84 year old woman, 6.5 cm in diameter and grey to light grey in cut surfaces. Serum proteins were within normal limits in both of these cases. Other cases have been reported in the literature.⁷

Lipper and Kahn have reported 4 cases, one in bone and the others in the right breast of a 57 year old woman, the abdominal wall of a 47 year old man and the left inguinal region in a 40 year old man.⁷

Follow up of two of the three cases showed nothing. In other reports, other organs, for example the breast,¹⁰ eye,¹² thigh,¹⁷ mediastinum,² brain,⁸ urethra (17 cases),²¹ bladder,⁴ lung,⁵ thyroid¹⁶ and the rectum⁶ have been involved.

Amyloid tumor has also been reported in the eyelid and skin as small nodules.^{13, 14, 18, 21}

Brown Stein and Helwig in 1970³ reported 39 cases of primary localized amyloid tumor in the skin and since then there have been several reports of these tumors in the skin.¹⁹ Some authors think that gonococcal urethritis is a predisposing factor for amyloid tumor of the urethra.²¹ One case of localized amyloid tumor in the thyroid has been reported which was associated with Hashimoto's thyroiditis.¹⁶

Macroscopically the tumor consists of a mass or lobulated

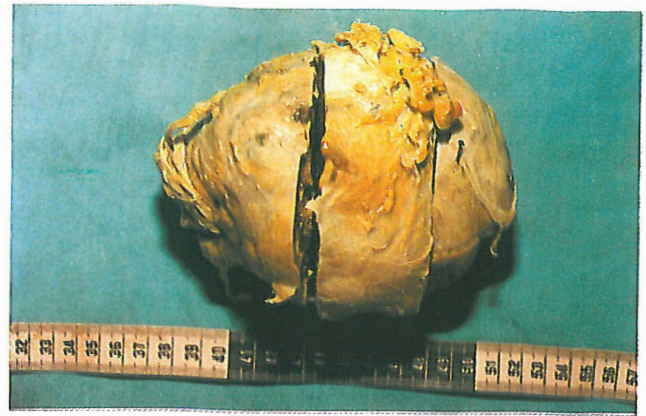

Fig. 1. Retroperitoneal localized primary amyloid tumor in a 44 year old woman.

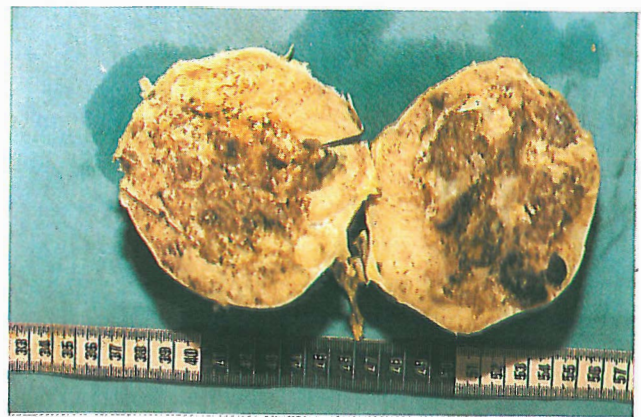

Fig. 2. Cut surface of retroperitoneal amyloid tumor with brown, white and light red color.

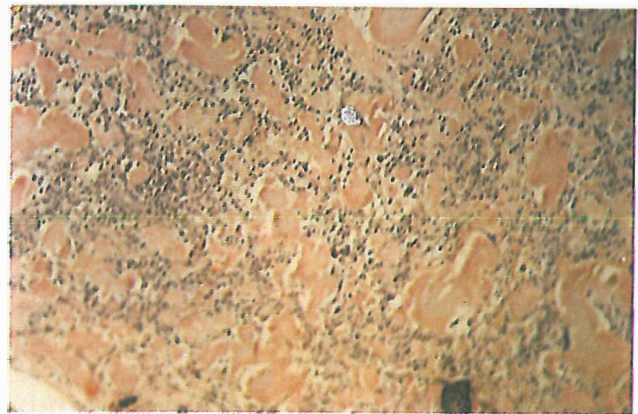


Fig. 3. Retroperitoneal amyloid tumor: deposits of amorphous eosinophilic material surrounded by lymphocytes and plasma cells.

nodule with slow growth and yellow, white or light red color upon sectioning. Microscopically there is amorphous eosinophilic material which is PAS-positive and are

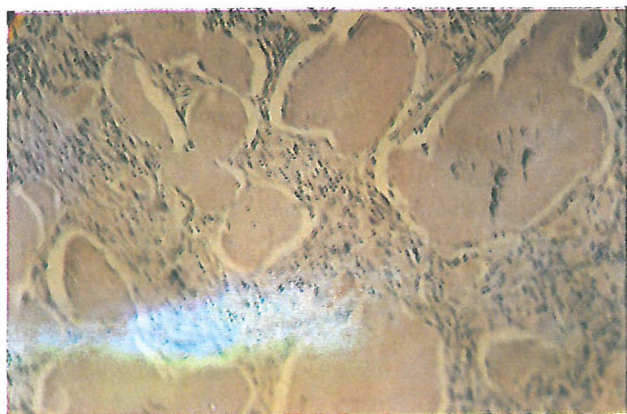


Fig. 4. Retroperitoneal amyloid tumor: deposits of amorphous eosinophilic material.

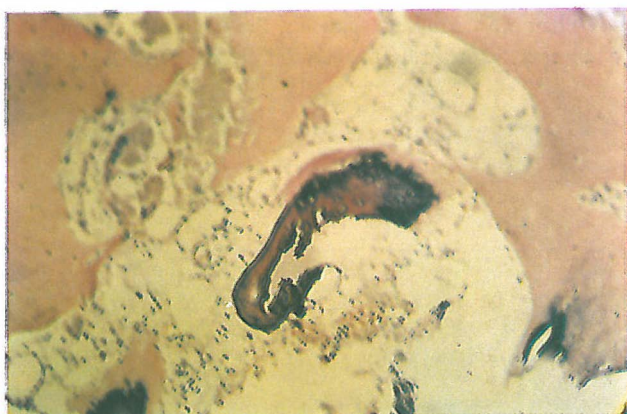

Fig. 5. Retroperitoneal amyloid tumor: osseous metaplasia.

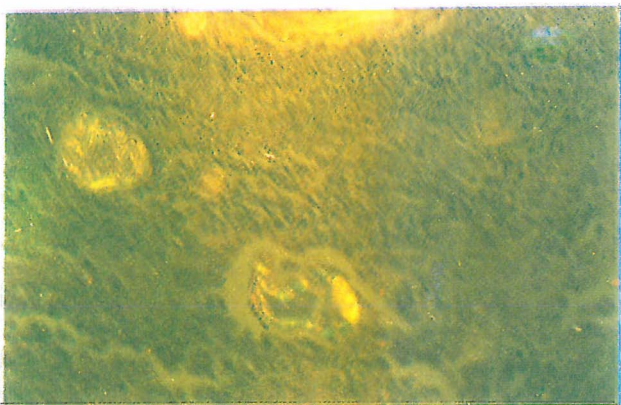


Fig. 6. Retroperitoneal amyloid tumor: apple-green birefringence of amyloid material under polarized light.

metachromatic with crystal violet staining. They are positive with congo red staining and have apple-green birefringence under polarized light. These deposits are surrounded by multinucleated giant cells and more or less chronic

inflammatory infiltrates rich in lymphocytes and especially plasma cells.⁷ Differentiation between the infiltration observed in amyloid tumor, which is often associated with enormous plasma cells, from the tumoral infiltration present in plasmacytoma is important. The following findings disclose the former as being a reactive phenomenon:

- 1) Small and enormous blood vessels which are covered by monomorphous but large endothelial cells.
- 2) Mature plasma cells
- 3) The presence of other inflammatory cells
- 4) Russell bodies
- 5) To prove the polyclonality by immunohistochemistry.²⁰

Deposits of this material are fine and fibrillar and have different amino acids in each case.⁸

Some believe that the precursor protein in localized cases is made by plasma cells which are adjacent or in the deposits even if they are few in number. On the other hand, in systemic cases the precursor proteins exist in the circulation and their site of production may be far from the place in which they are deposited.⁸

Immunohistochemical evaluation has been done in only a few cases, but in almost all of them this protein was a light chain monoclonal immunoglobulin.

Kappa chain was present in two patients with localized skin and larynx amyloidosis, and lambda chain was reported in two patients with localized skin and lung amyloidosis.

The kind of precursor protein in localized amyloid tumors of the skin, cervical vertebrae, wrist and other joints is beta 2 microglobulin, although a small area may be α_1 positive.^{1,9}

Vessel walls are often diffusely thickened by deposition of amyloid. Microscopically, there is no difference between the amyloid tumor present in primary or secondary amyloidosis.

Elastin stain helps to differentiate this tumor from elastofibroma and absence of calcium separates this tumor from tumoral calcinosis.⁷

Cartilage and bone formation sometimes occurs in amyloid tumor.^{7,15}

REFERENCES

1. Ausserwinkler M: Craniocervical amyloid tumor with destructive spondyloarthropathy and myelocompression as a rare complication of long term dialysis. *Wien Klin Wochenschr* 102 (5): 152-5, 1990.
2. Boleslaw P: Amyloid tumor (amyloidoma) of the mediastinum. *Pathol Pol* 44(4): 227-231, 1993.
3. Brown Stein MH: The cutaneous amyloidosis. *Arch Dermatol* 102: 8, 1970.
4. Bhagwande BS: Primary localized amyloidosis of the bladder with a monoclonal plasma cell infiltrate. *Pathology* 20 (1): 67-9, 1988.

Retroperitoneal Amyloid Tumor with Osseous Metaplasia

5. Bootsvelde K: Primary amyloid tumor of the lung. *Radiology* 32 (12): 612-7, 1992.
6. Dörner O: Solitary primary amyloid tumor of the rectum. *Leber Magen Darm* 19 (2): 95-6, 99, 1989.
7. Enzinger FM: *Soft tissue tumors*. St. Louis: C. V. Mosby Company, p. 928; 1988.
8. Eriksson L: Tumour-like localized amyloid of the brain is derived from immunoglobulin light chain. *Scand J Immunol* 37 (1): 623-6, 1993.
9. Floege J: Subcutaneous amyloid tumor of beta-2 microglobulin origin in a long-term hemodialysis patient. *Nephron* 53 (1): 73-5, 1989.
10. Fernandez BB: Amyloid tumor of the breast. *Arch Pathol* 95: 102, 1973.
11. Goonatillake HD: Amyloid tumor of the breast simulating carcinoma. *Aust NZJ Surg* 58 (7): 589-90, 1988.
12. Howard GM: Amyloid tumor of the orbit. *Br J Ophthalmol* 50: 421, 1966.
13. Halasa AH: Amyloid disease of eyelid and conjunctiva. *Arch Ophthalmol* 74: 298, 1965.
14. Haltzman IN: Amyloid tumor formation of skin. *Arch Dermatol* 67: 187, 1953.
15. Lynch LA: Localized primary amyloid tumor associated with osseous metaplasia presenting as bilateral breast masses. *Diag Cytopathol* 9 (5): 570-5, 1993.
16. Moriuchi A: Localised primary amyloid tumor of the thyroid developing in a case of Hashimoto's thyroiditis. *Pathol JPN* 42 (3): 210-6, 1992.
17. Potter BS: Primary localized amyloidosis cutis. *Arch Dermatol* 103: 448, 1971.
18. Smith ME: Amyloidosis of the eyelid and conjunctiva. *Arch Ophthalmol* 75: 42, 1966.
19. Sepp N: Typing of infiltration cells in primary nodular, cutaneous amyloidosis. *Hautarzt* 43 (4): 210-4, 1992.
20. Silverberg SG: *Principles and Practice of Surgical Pathology*. New York: Churchill- Livingstone, p. 620, 1990.
21. William OE: Amyloid tumor of the urethra presenting as nonspecific urethritis. *Genitourin Med* 63 (5): 332-3, 1992.