

XERODERMA PIGMENTOSUM WITH NEUROLOGICAL COMPLICATIONS: THE DESANCTIS-CACCHIONE SYNDROME

HAMDOLLAH KARAMIFAR, M.D., AND GHOLAMHOSEIN
AMIRHAKIMI, M.D.

From the Department of Pediatrics, Shiraz University of Medical Sciences, Shiraz, Islamic Republic of Iran.

ABSTRACT

A 7 year old boy with DeSanctis-Cacchione syndrome – xeroderma pigmentosum, microcephaly, mental deficiency, dwarfism and gonadal hypoplasia – will be presented.

Keywords: Xeroderma pigmentosum (XP), DeSanctis-Cacchione syndrome

MJIRI, Vol. 11, No. 2, 153-155, 1997.

INTRODUCTION

Xeroderma pigmentosum (XP) is a rare multisystemic disorder affecting approximately 1 in 250,000 people.⁵ XP is characterized by freckle-like lesions in areas exposed to sunlight with the subsequent development of carcinomas.^{4,6} These skin lesions have their onset at an early age.¹⁰ The DeSanctis-Cacchione syndrome is the most severe form of XP; in addition to skin lesions, the syndrome includes microcephaly with mental deficiency, premature closure of cranial sutures, retarded growth and sexual development, choreoathetosis, cerebellar ataxia, eventual quadriplegia with shortening of the Achilles tendons and sometimes sensorineural deafness.^{1,2,8,9}

Case report

A 7 year old boy was referred to the pediatric endocrine department of Nemazee Hospital because of failure to thrive. He had been born as a full term infant following normal vaginal delivery without any birth problems. He had a history of growth and developmental retardation and skin lesions appearing early in life which progressed with age, along with photophobia and abnormal photosensitivity. There was a family history of a cousin with similar problems.

Physical examination revealed a small boy who was

totally unaware of his surroundings and unable to sit or speak. Vital signs were as follows: BP: 95/60, PR: 120. Body weight was 9 kg, height 82 cm, and head circumference 40 cm, all below the third percentile for

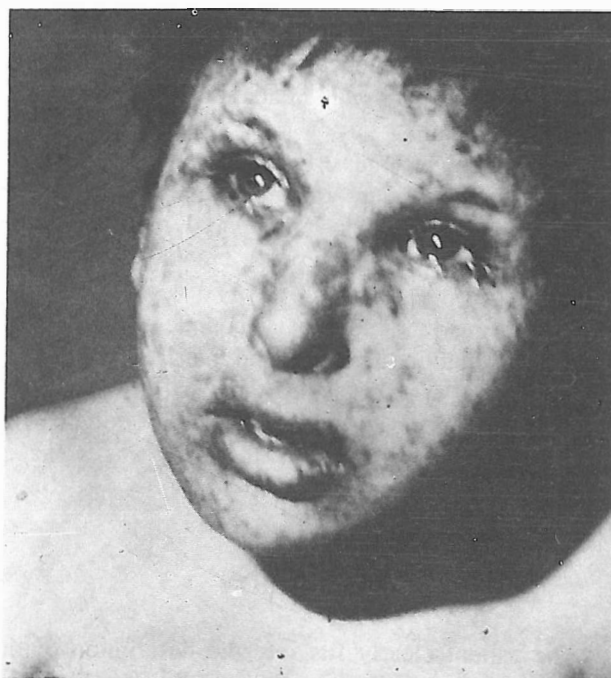

Fig. 1. Advanced cutaneous changes in the patient.

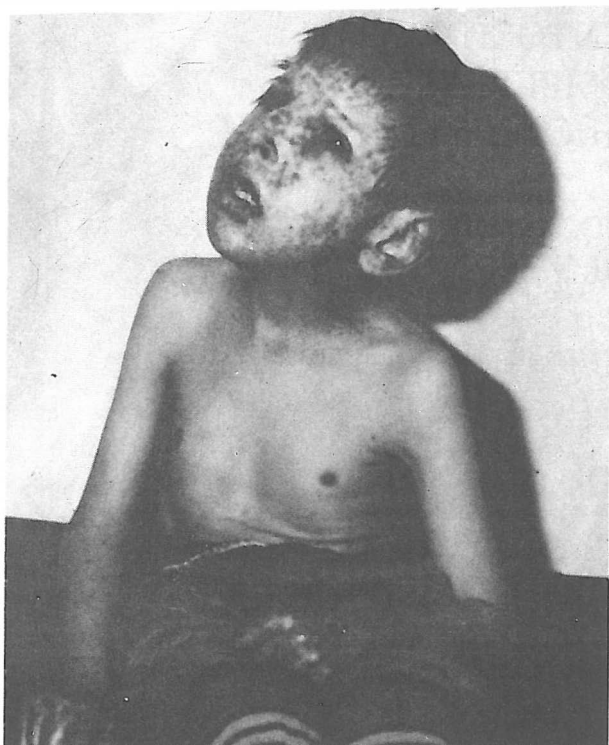

Fig. 2. The child's appearance showing microcephaly.

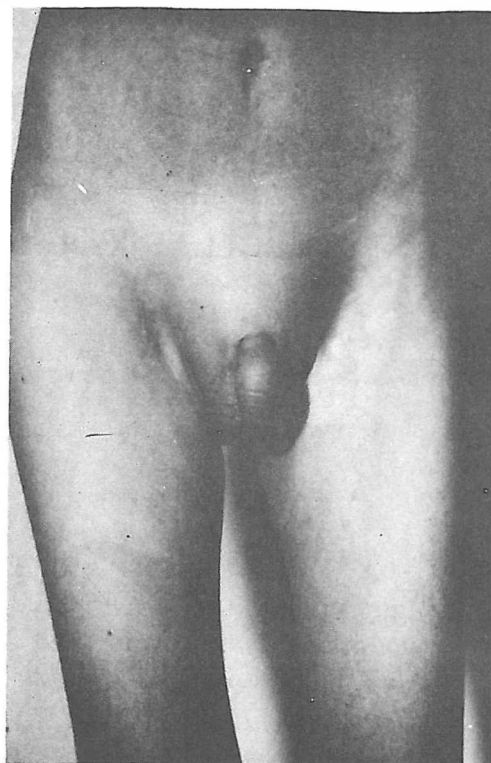


Fig. 3. The child's small genitalia and testicular hypoplasia.

age.

The patient's skin was hyperpigmented, and freckles were present on the face, nose, neck and extremities. He had microcephaly, deep set eyes, equal pupils responsive to light, and a normal fundus upon examination. A small nose, high arched palate, normal lungs and heart, a deformed chest, a soft abdomen without organomegaly, and bilateral undescended testes were also present.

Decreased muscle mass in the extremities, spasticity and quadriparesis were other findings. Neurological examination revealed severe mental retardation, an intact sensorium and functioning cranial nerves (Figs. 1,2,3).

Concerning laboratory data, complete blood count and thyroid function tests were normal; BUN=12mg/dL; creatinine= 0.4 mg/dL; fasting blood sugar = 80 mg/dL; calcium=9 mg/dL; phosphorus=5 mg/dL; sodium =140 meq/L; potassium=4 meq/L. Skin biopsy was in favour of XP.

DISCUSSION

The patient clearly fits into the description of the DeSanctis-Cacchione syndrome,^{2,3,7} due to the presenting features of 1) xeroderma pigmentosum, 2)

microcephaly with progressive mental deterioration and spastic paralysis, 3) gonadal underdevelopment, and 4) short stature.

This autosomal recessive disorder was first reported by DeSanctis and Cacchione in 1932.²⁻⁷ They described three brothers with idiocy, XP, testicular hypoplasia and retarded skeletal development.⁷ The postmortem microscopic examination of one revealed a small brain with gliosis and loss of neurons in the frontal and temporal cortices.

REFERENCES

1. Friedman A, Naveh Y, Haim S: Xerodermic idiocy or DeSanctis-Cacchione syndrome. *Clin Pediatr Phila* 12 (1): 56-8, 1973.
2. Gupta CM, Bhate RD, Chandar V: The DeSanctis-Cacchione syndrome. *Indian J Pediatr* 55 (6): 991-3, 1988.
3. Hessel A, Siegle RJ, Mitchell DL, et al: Xeroderma pigmentosum variant with multisystem involvement. *Arch Dermatol* 128: 1233-1237, 1992.
4. Hertle RW, Durso F, Varsa EW: Epibulbar squamous cell carcinoma in brothers with xeroderma pigmentosa. *J Pediatr Ophthalmol Strabismus* 28 (6): 350-3, 1991.
5. Leake J, Sheehan MP, Rampling D, et al: Angiosarcoma complicating xeroderma pigmentosum. *Histopathology* 21: 179-181, 1992.

6. Paridaens AD, McCartney AC, Hungerford JL: Premalignant melanosis of the conjunctiva and the cornea in XP. *Br J Ophthalmol* 176 (2): 120-2, 1992.
7. Reed WB, Stanton B, Walter R, et al: Xeroderma pigmentosum with neurological complications: the DeSanctis - Cacchione syndrome. *Arch Dermatol* 91: 224-227, 1965.
8. Reed WB, Sugarman G, Mathis RA: DeSanctis - Cacchione syndrome: a case report with autopsy findings. *Arch Dermatol* 113: 1561-1564, 1977.
9. Reed WB, Landing B, Sugarman G, et al: Xeroderma pigmentosum: clinical and laboratory investigation of its basic defect. *JAMA* 207: 2073-2077, 1969.
10. Silberstein AG: Xeroderma pigmentosum with mental deficiency: a report of two cases. *Am J Dis Child* 55: 784-91, 1938.

