

UNUSUAL PRESENTATION OF TAILGUT CYST AS A PROTRUDING MASS BESIDE THE COCCYX

JALAL VAHEDIAN ARDEKANI, M.D.
AND ALI ZARE MEHRJARDI, M.D.*

*From the Departments of Surgery and *Pathology, Bahonar Hospital, Kerman University of Medical
Sciences, Kerman, Islamic Republic of Iran.*

ABSTRACT

Tailgut cyst is a very rare lesion of the retrorectal space seemingly derived from embryonic remnants of the tailgut which often causes rectal signs and symptoms. A unique case of this lesion presenting as a subcutaneous mass lateral to the coccyx is hereby described.

Keywords: Tailgut, tailgut cyst, retrorectal cystic hamartoma, retrorectal space

MJIRI, Vol. 11, No. 2, 161-162, 1997.

INTRODUCTION

A rare lesion in the retrorectal area, tailgut cyst or retrorectal cystic hamartoma is a developmental lesion likely to be derived from vestiges of embryonic tailgut.¹ A unique case of this lesion is hereby described.

Case report

A 55 year old woman presented with a protruding subcutaneous mass in the right sacrococcygeal area. She stated that it had been present for a long time, but has recently grown further and has caused an unpleasant and uncomfortable state for her. On examination there was a soft dome-shaped bulging mass measuring 8×10 cm in the right sacrococcygeal area with no tenderness or superficial inflammation. Rectal examination disclosed a smooth round mass in the posterior rectal area. Barium enema revealed a soft tissue mass in this region with no connection to the rectum. Myelography showed a normal sacral spinal canal and CT scan revealed a well-demarcated lesion in the retrorectal area with extension posterolaterally beside the coccyx to the subcutaneous area, forming a dumb-bell shaped mass (Figs. 1,2). Fine needle aspiration of this lesion showed thick secretory material, cholesterol crystals and foamy histiocytes. The mass was completely excised through a skin incision. The patient is well with no sign of recurrence or local discomfort 6 months after surgery.

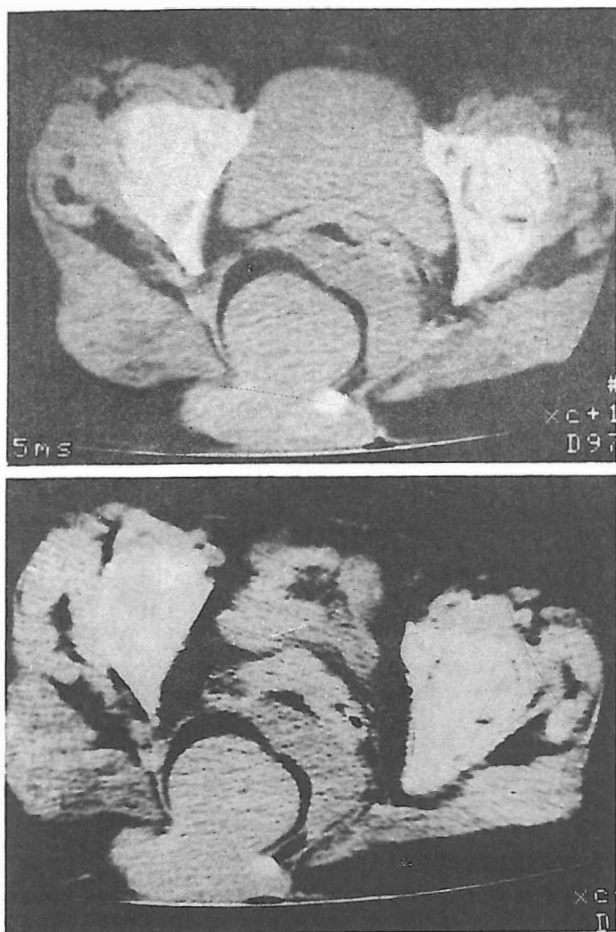
Pathologic findings

The specimen received was an irregular brown mass covered in some areas by a thick layer of fatty tissue measuring 8×6.5×3.5 cm (Fig. 3). On section it was a bilocular cyst filled with thick brown gelatinous material. The lining was smooth but finely wrinkled. Microscopic examination of the cyst wall revealed a variety of epithelial linings including nonkeratinizing stratified squamous cells, transitional cells, columnar mucus cells and pseudostratified ciliated columnar cells. The underlying connective tissue contained occasional fine bundles of smooth muscle cells along with areas of old hemorrhage and infiltration of chronic inflammatory cells.

DISCUSSION

The tailgut is a small segment of embryonic gut that grows from the postanal part of it along with the embryonic tail, but it soon disappears in the 8 mm stage embryo. If portions of this structure remain, they may give rise to cystic structures in the retrorectal space known as tailgut cysts. These are often multicystic lesions with variable epithelial linings and devoid of an organized smooth muscle coat, but they have scattered smooth muscle bundles in their connective tissue wall.³

Tailgut cyst is a rare lesion that has appeared in the



Figs. 1, 2. CT scan reveals a dumb-bell shaped, homogenous soft tissue mass in the retrorectal space, well-separated from the rectum and protruding posteriorly beside the coccyx.

literature mostly as case reports.^{4,5} Hjernstad and Helwig have collected 53 cases of tailgut cyst in more than thirty years, the largest reported collection of this lesion.³ It may present at any age, and signs and symptoms are mainly rectal, such as pain or feeling pressure in the rectum, decreased stool caliber, pain on defecation and draining sinuses in the perianal area.³ Bony defects such as spina bifida in the sacrum and coccyx have been reported concomitantly with tailgut cyst.² It may even remain asymptomatic and be discovered incidentally. In unusual cases, tailgut cyst has appeared with pressure signs on the bladder⁶ or on the renal pelvis.² Our case also seems to be unique in its growth and presentation.

Main differential diagnoses of tailgut cyst are enteric

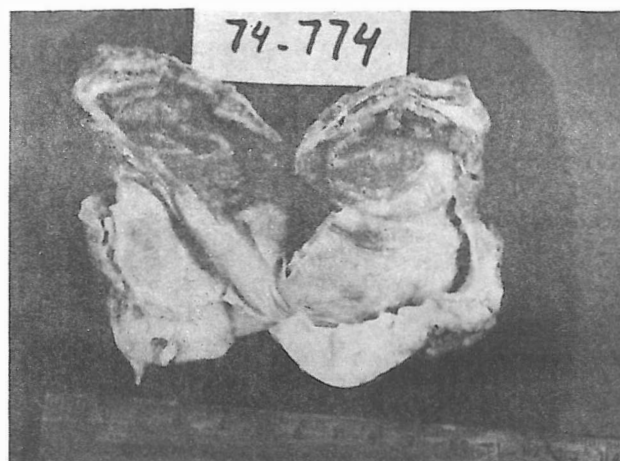


Fig. 3. Opened cyst with areas of hemorrhage in the wall and inhomogenous linings.

cyst, rectal duplication and teratoma; enteric cyst has a lining identical to that of small intestine; rectal duplication has well-developed muscle coats; and teratoma should contain elements of all three germ cells. Besides, teratomas of the presacral area often have neural elements and skin appendages which are not seen in tailgut cysts.⁷

Since tailgut cysts may become infected or rarely be the site of an adenocarcinoma they must be completely excised even in asymptomatic cases.

REFERENCES

1. Morson BC, et al: Tumors of the anorectal region. In: Morson BC, Dawson IMP, Day DW, Jass JR, Price AB, Williams GT, (eds.), *Morson & Dawson's Gastrointestinal Pathology*. Oxford, Blackwell Scientific Pub., 3rd ed., pp. 681-2, 1990.
2. Mills SE, Walker AN, Stallings RG, Allen SA: Retrorectal cystic hamartoma: report of three cases including one with a perirenal component. *ArchPath Lab Med* 108: 737-740, 1984.
3. Hjernstad BM, Helwig EB: Tailgut cysts. Report of 53 cases. *Am J Surg Pathol* 89: 139-147, 1988.
4. Djamali M, Shahnazari F: Tailgut cyst: a case report. *J Tehran Univ Med* 7: 71-76, 1990 (in Persian).
5. Macro V, Autonell J, Farre J, et al: Retrorectal cystic hamartoma: report of two cases with adenocarcinoma developing in one. *Am J Surg Pathol* 6: 707-714, 1982.
6. Stephenson BM, et al: Recent change in a tailgut cyst presenting as urinary retention. *Br J Urol* 66(3): 326, 1990.
7. Ganzalez-Crussi F: *Extragenital teratoma*. Washington, DC: Armed Forces Institute of Pathology, pp. 50-76, 1982.