

DIPHALLUS: A REPORT OF AN UNUSUAL CASE

ABDOLLAH NASSEHI, M.D.,* AND MOHAMMAD AMIR
KHAMMER, M.D.**

*From the Department of Urology, Mashhad University of Medical Sciences, Mashhad, Islamic Republic
of Iran.*

ABSTRACT

We report an unusual case of diphallus in a five year old boy. The two organs appeared separately, one orthotopically in the pubic area and the other in the perineum with no urinary meatus. A perineal hypospadias with meatus in the anterior anal verge was also present. The right testis was undescended and the scrotum was mildly bifid. The patient was continent for both voiding and defecation. Micturition was via the hypospadiac perineal meatus under voluntary control. A review of published cases suggests that this may be the first example of complete diphallia with two separate phalli in different locations.

Keywords: Diphallus, Pseudodiphallia, Duplication of penis, Perineal hypospadias.

MJIRI, Vol. 11, No. 1, 61-63, 1997.

INTRODUCTION

Diphallia, also referred to as duplication, is a rare congenital anomaly, as there have been less than 100 reports of diphallus in the literature.¹⁶ It has been estimated that in the United States its incidence is one per every 5 million live births. The first documented report of this anomaly dates back to 1602.²⁰ Associated defects are common, including hypospadias, epispadias, bifid scrotum, vesical extrophy, diastasis pubis, absence or duplication of the bladder and urethra, renal agenesis, ectopia and horseshoe kidneys, duplication of the hindgut and spinal dysraphism.

Schneider proposed three different groups: (1) bifid glans, (2) bifid diphallia, and (3) complete diphallia or double penis. The term pseudodiphallia proposed by Villanova and Raventos includes cases exhibiting an accessory ectopic penis.

According to Abdel, two main groups exist, true diphallia (partial and complete) and bifid phallus (partial and complete-bifid glans, bifid body).¹

Our case does not fit any of these classifications and may

be the first example of complete diphallia with two separate phalli in different locations.

Case Report

A five year old boy was referred to our center because of bizarre genitalia. There were two separate phalli, one

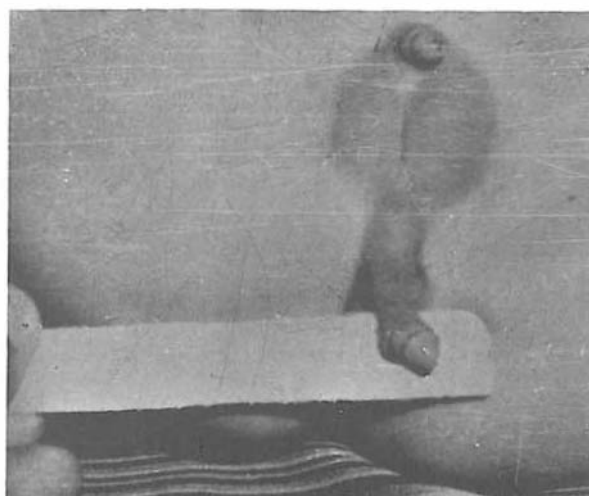


Fig. 1. Two distinct phalli are shown.

* Assistant Professor of Urology

** Assistant Professor of Urology

Diphallus

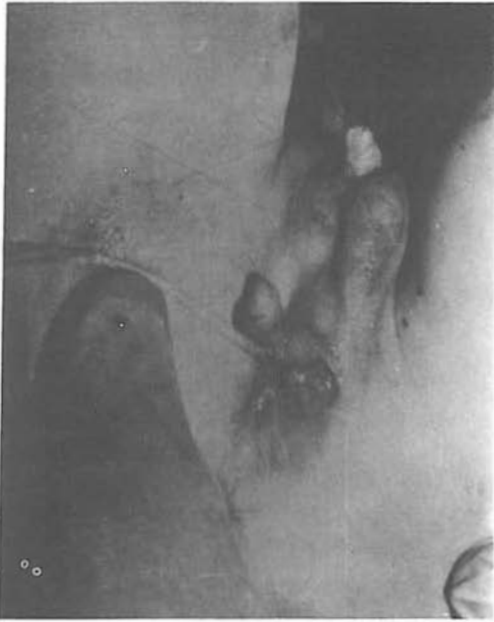

Fig. 2. Another picture of the patient showing positions of two phalli, anus, and urinary meatus in anterior anal verge with catheter.

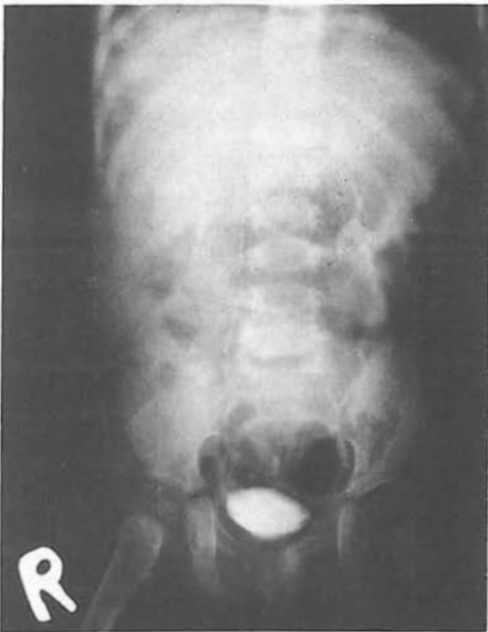

Fig. 3. Intravenous urogram of the patient showing both kidneys and ureters with no abnormalities.

orthotopic (in the pubic area) and the other located in the perineum. Both phalli were smaller than normal with no urethra or urethral meatus (Fig. 1). The scrotum was mildly bifid, and a perineal hypospadias existed with meatus located in the anterior anal verge (Fig. 2).

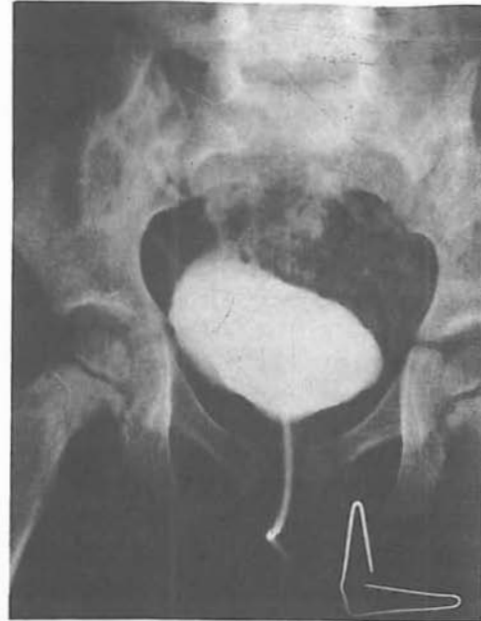

Fig. 4. Retrograde cystogram of the patient demonstrating no duplication or vesicoureteral reflux.

The left testis was normal in size and consistency, but the right testis was undescended. The patient was continent for both voiding and defecation day and night. Micturition was via the perineal meatus under voluntary control. Physical examination of the heart, lungs, limbs, spine and CNS was normal. Rectal examination revealed normal anal sphincter tonicity and an intact prostate gland.

Family history was negative for any congenital anomalies. Furthermore, the patient's mother had no infections, nor had she been exposed to any. She also denied any drug consumption during an uneventful pregnancy. Chromosomal study revealed normal X karyotype and appropriate sexual chromatin.

Evaluation of the patient's upper urinary tract with excretory urogram revealed normal kidneys and ureters with no ectopia or fusion and no osseous abnormalities in vertebrae or pelvic bones (Fig. 3).

Retrograde cystogram showed normal bladder with no evidence of vesicoureteral reflux (Fig. 4). On endoscopy there was a straight narrow tube as the posterior urethra with no evidence of verumontanum.

Ultrasound study of the liver, pancreas and adrenals was normal. Chest x-ray disclosed no abnormalities.

After explaining the situation of the patient to his parents, we asked them for evidence of erection. His mother reported nocturnal tumescence in both phalli.

Surgical exploration was performed, and revealed that there were two corporal tissues within the ectopic phallus which terminated in the perineum. The ectopic phallus was excised completely and a right orchiopexy was done at the

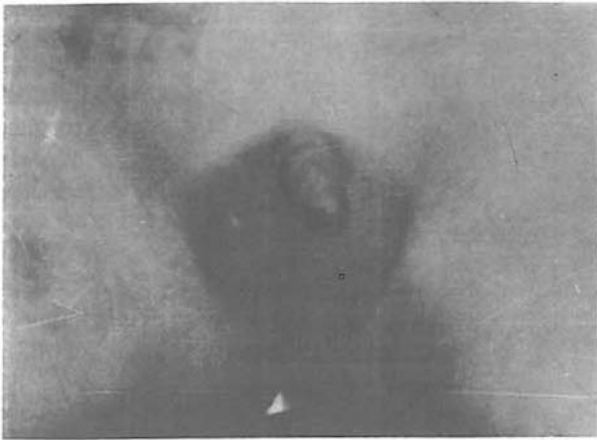

Fig. 5. Picture showing the patient after ectopic phallus excision and right orchiopexy.

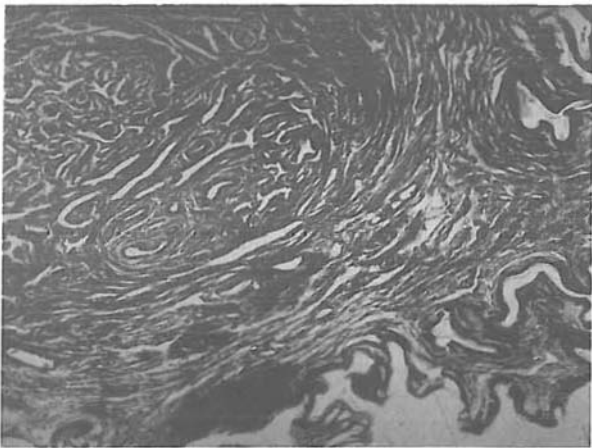


Fig. 6. Low-power view of the specimen demonstrating corporal tissue in the upper left, with skin layers in the lower right side of the picture.

same time (Fig. 5).

The anatomopathologic report was as follows: Gross specimen covered with skin measured 5 cm long and 1 cm wide. A glans penis was located at one end, and corpora cavernosal bodies were seen on cross section. Microscopic examination showed distinct dilated vessels with fibroelastic wall embedded in fibromuscular tissue which was totally surrounded by skin. The diagnosis was diphallus or double penis.

We plan to perform urethroplasty with bladder mucosal graft after six months.

CONCLUSION

Review of literature revealed that complete diphallus is a very rare anomaly. Some of the previous reports of this

anomaly were unique in some aspects; i.e., association with a third urethra, duplicated bladder, spinal dysraphism, etc. We believe that our case may be the first example of a complete diphallus in these locations.

REFERENCES

1. Abdel A: Diphallia. *J Urol* 108: 357, 1972.
2. Agarwal S, Sogani SK: Diphallus. *J Ped Surg* Apr 19(2): 213-4, 1984.
3. Azmy AF: Complete duplication of the hindgut and lower urinary tract with diphallus. *J Ped Surg* 25 (6): 1984.
4. Beau J: Diphallus. *Chir Ped* 21 (4): 281-2, 1980.
5. Gammie WP, Davies JH: Diphallus in an adult. *Br J Urol* 62 (2): 185-6, 1988.
6. Hollowell JG: Embryologic considerations of diphallus and associated anomalies. *J Urol* 117: 728, 1977.
7. Kapoor R, Saha MM: Complete duplication of the bladder, urethra and external genitalia in a neonate. A case report. *J Urol* 137: 1243, 1987.
8. Kaufman A, Guia R, Davila H, Kaufman A: Diphallus with third urethra. *Urology* 35 (3): 257-60, 1990.
9. Landy B, Singer R, Oetjen L: A case of diphallia. *Urology* (1): 48-9, 1988.
10. Marti-Bonmati L, Menor F, Gomez J, Cortina H, Ibarra FG: Value of sonography in true complete diphallus. *J Urol* 142: 356, 1989.
11. Melekos MD, Barbalias GA, Asbach HW: Penile duplication. *Urology* 27(3): 258-9, 1986.
12. Nesbit RM, Bomme W: Double penis and double bladder. *Am J Roentgenol* 30:497, 1933.
13. Pagano J: Diphallus. *Urology* 13:362, 1962.
14. Rao TV, Chandrasekharam V: Diphallus with duplication of cloacal derivative (report of a rare case). *J Urol* 124 (4):555-7, 1980.
15. Remzi D: Diphallia. *Urology* 13:362, 1962.
16. Schneider P: Cited by Lattimer JK, Uson AC and Melicow AC: The male genital tract. In: Mustard WT, et al (eds), *Pediatric Surgery*. Vol. I, Chap 77, p. 1263, 1969.
17. Seth RE, Peacock AH: Double penis. *Urol Cutan Rev* 36: 590, 1932.
18. Srivasta DN, Awasthy DN, Katiyar R K: Spinal dysraphism with accessory male genital organs. *Australas Radiol* Aug 33 (3): 293-5, 1989.
19. Urol 71: 338, 1954.
20. Wecker SS: Penegemino visus quidam, obs Med Admir Moust Lib Y De Partibus

