

GASTROINTESTINAL BLEEDING FROM A FISTULA BETWEEN A HEPATIC ARTERY ANEURYSM AND THE DUODENUM: A CASE REPORT AND REVIEW OF THE LITERATURE

H. HODJATI, M.D., AND S. ARSHADI,* M.D.

*From the Departments of Surgery and *Radiology, Shiraz University of Medical Sciences,
Shiraz, Islamic Republic of Iran.*

ABSTRACT

Hepatic artery aneurysms are a rare cause of upper gastrointestinal hemorrhage and may represent significant problems in both diagnosis and management. We report a 70 year old patient with gastrointestinal bleeding from a fistula between a 7 cm hepatic artery aneurysm and the duodenum. He underwent successful surgical management with endoaneurysmorrhaphy and duodenal wall repair.

MJIRI, Vol. 11, No. 1, 67-69, 1997.

INTRODUCTION

Hepatic artery aneurysm is an uncommon but frequently fatal lesion. The natural course of the lesion appears to be rupture with exsanguinating hemorrhage into the peritoneal cavity or into the biliary tract or duodenum. Gastrointestinal hemorrhage may be massive when the aneurysm ruptures into a viscus or it may be intermittent when it ruptures into the biliary tree. Hepatic artery aneurysm should be suspected when the more common forms of upper gastrointestinal hemorrhage are not discovered by upper GI endoscopy. We present a case of recurrent upper gastrointestinal hemorrhage from a ruptured hepatic artery aneurysm into the duodenum. Endoaneurysmorrhaphy and duodenal repair was done without complications.

Case report

A 70 year-old male was referred to Faghihi Hospital in Shiraz for evaluation of upper gastrointestinal bleeding for 3 days. The patient had done well without any complaints of melena, hematemesis or abdominal pain before that time. On examination, the patient was noted to be pale and dehydrated. Blood pressure was 130/90 mmHg, and pulse rate was 100 per minute. On abdominal palpation there was

no detectable mass or organomegaly. Bowel sounds were normal. Upper gastrointestinal endoscopy revealed a submucosal bulging mass in the duodenal bulb with multiple mucosal erosions oozing blood. Abdominal sonography showed a cystic structure about 7 cm in diameter displacing the stomach and duodenum upwards (Fig. 1). Contrast-enhanced CT also showed a large aneurysm in the subhepatic

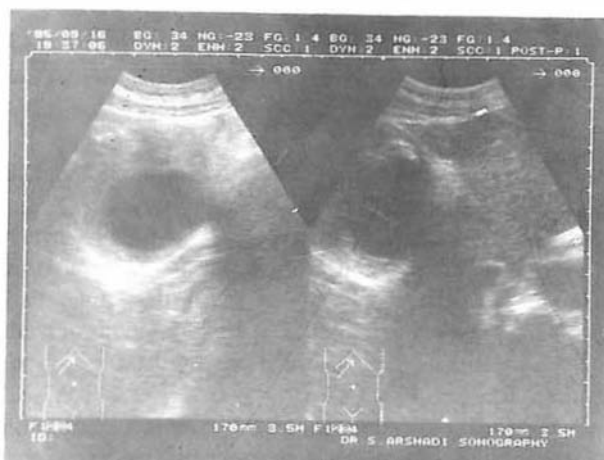


Fig. 1. Abdominal sonography revealing a 7 cm cystic lesion with a thick wall.

Hepatic Artery Aneurysm-Duodenal Fistula

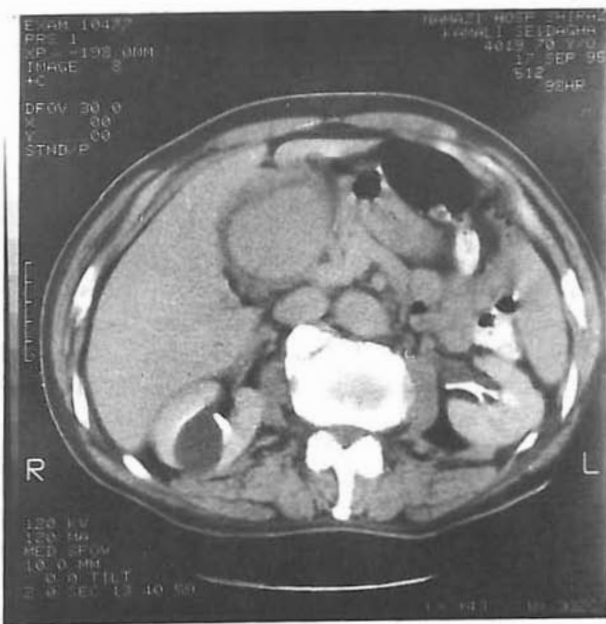
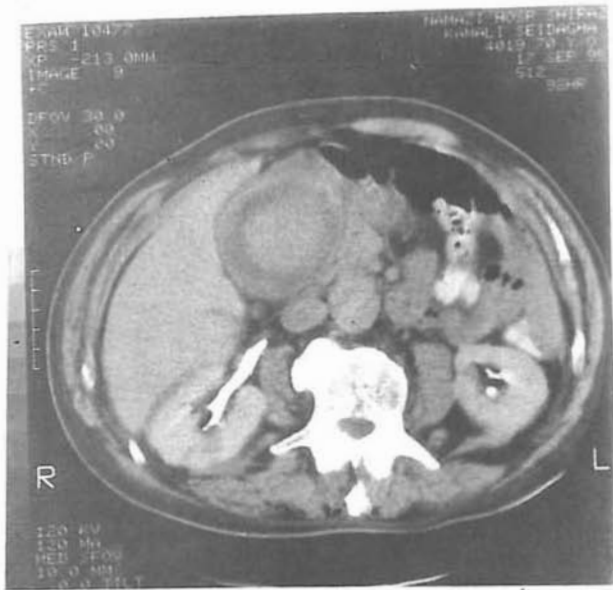


Fig. 2,3. CT scan demonstrates a large subhepatic aneurysm.

area with possibility of leakage into the hollow viscus. On CT the aneurysm was not from the aorta (Figs. 2,3).

The patient underwent surgery where exploration showed a large 7 cm hepatic artery aneurysm distal to the gastroduodenal artery and connected to the duodenum. The aneurysm was opened with endoluminal control and endoaneurysmorrhaphy was done with 5/0 prolene. The duodenal wall was debrided and repaired in one layer and the aneurysmal wall was used as a flap over the duodenum. A Penrose drain was placed in the subhepatic area and the abdomen was closed. The patient tolerated the operation uneventfully and was discharged 7 days later. During 6

months follow-up no sign of gastrointestinal bleeding was seen and abdominal sonography was normal.

DISCUSSION

Aneurysm of the hepatic artery was first reported by the British anatomist Wilson in 1809.^{1,2} The first successful surgical intervention was performed nearly 100 years later by Kehr,¹ who in 1903 ligated an aneurysm in the common hepatic artery. The first attempt at surgical therapy with restoration of flow through the damaged vessel was done in 1943 by another English physician, Gordon Taylor.¹ The first successful reconstructive endoaneurysmorrhaphy was done by Paul in 1953.³ The etiology has changed from mostly mycotic in the 1900's to atherosclerotic (32%), medial degeneration (24%) and trauma (22%).

The anatomic distribution of these lesions has been relatively constant in modern literature.^{1,4,5} Eighty percent are extrahepatic while 20 percent are intrahepatic. Intrahepatic aneurysms are usually false aneurysms secondary to trauma, while extrahepatic aneurysms may be true or false in nature.⁶ Signs and symptoms are quite variable. Patient age range has been from 10 to 83 years. The lesions are more common in men with the ratio being greater than 2:1.^{1,4,5} Abdominal pain, hemobilia and obstructive jaundice are generally associated with hepatic aneurysm.¹ Abdominal pain is the dominant symptom (85%), and obstructive jaundice may be secondary to duct compression by the aneurysm or result from bleeding into the biliary tree with subsequent obstruction by clots.^{7,8,9} The great majority of lesions rupture either into the peritoneal cavity or into the biliary tree, but rupture may occur to other sites. Bleeding from T-tubes or other drains has been reported. Rupturing to the portal vein with secondary portal hypertension has been reported.^{1,2,7,10}

Abdominal plain films occasionally show a calcific ring, and upper gastrointestinal studies may show duodenal deformity and extrinsic mass pressure.^{1,2} CT and abdominal sonography show a mass.

Arteriography represents the most definite diagnostic test in demonstrating hepatic artery aneurysm and allows for assessment of hepatic circulation, essential in planning surgical treatment.¹¹ Treatment requires aggressive operative intervention. Aneurysms which occur proximal to the gastroduodenal artery can generally be safely handled by simple ligation or by ligation with excision.^{5,7,12,13,14} Aneurysms that arise distal to the gastroduodenal artery require an operative procedure that restores flow through the area of the lesion. Endoaneurysmorrhaphy is the most frequently used procedure in review by Guida and Moore and by Ariyan.¹⁰ This operation ranked second only to obliterative procedures in producing cures.

We conclude that hepatic artery aneurysm should be

considered in the differential diagnosis of unexplained upper gastrointestinal bleeding. A high index of clinical suspicion is needed for diagnosis. Confirmation is attained with the accuracy and consistency of vascular ultrasound, CT and angiography. Operative intervention should be swift with special interest given to location of the aneurysm and collateral hepatic blood flow.

REFERENCES

1. Guida PM, Moore SW: Aneurysm of the hepatic artery. Report of five cases with a brief review of the previously reported cases. *Surgery* 60: 299-310, 1966.
2. Payne JE, Kemmerer WT: Hepatic artery aneurysm with rupture into general peritoneal cavity. *J Trauma* 7: 793-7, 1967.
3. Rutten APM, Sikkenk PJH: Aneurysm of the hepatic artery; reconstruction with saphenous vein graft. *Br J Surg* 50: 262-6, 1971.
4. Stanley JC, Zelenock GB: Splanchnic artery aneurysms. In: Rutherford RB (ed), *Vascular Surgery*. Philadelphia: W.B. Saunders Co., pp. 969-981, 1989.
5. Stanley JC: Abdominal visceral aneurysm. In: Haimovici H (ed), *Vascular Emergencies*. New York: Appleton-Century-Crofts, pp. 387-396, 1981.
6. Alexander RA, Lawrence GH: Operative repair of hepatic artery aneurysm. *Arch Surg* 93: 409-14, 1966.
7. Harlaftis NN, Akin JG: Hemobilia from ruptured hepatic artery aneurysm. *Am J Surg* 133: 229-32, 1977.
8. Santiago-Delpin EA, Marquez E, Roudriquez OL, et al: Perforated hepatic artery aneurysm and multiple aneurysms in incomplete Marfan syndrome. *Ann Surg* 176: 772-6, 1972.
9. Abraham RA, Stone J, Conn JH, et al: Hepatic artery aneurysm—diagnosis and successful treatment. *Angiology* 22: 134-40, 1971.
10. Ariyan S, Cahow CE, Greene FL, et al: Successful treatment of hepatic artery aneurysm with erosion into the common duct. *Ann Surg* 182: 169-72, 1975.
11. Weaver DH, Fleming RJ, Barnes WA: Aneurysm of the hepatic artery: the value of arteriography in surgical management. *Surgery* 64: 891, 1968.
12. Salto MK, Perna LR, Kishishian JM: Successful treatment of a hepatic artery aneurysm following intraperitoneal rupture. *Am Surg* 34: 450-4, 1968.
13. Asbury GF: Ruptured hepatic artery aneurysm. *Am Surg* 36: 631-4, 1970.
14. Winchester DP, Seed RW, Bergan JJ, et al: Jaundice, hemobilia, and hemoperitoneum. *Am J Surg* 120: 384-7, 1970.

