

Original Articles

SHORT TERM CLINICAL OUTCOME OF PERCUTANEOUS BALLOON MITRAL VALVULOPLASTY VERSUS SURGICAL CLOSED MITRAL COMMISSUROTOMY

M. MOMTAHEN, M.D., A. MOHEBBI, M.D., M. KIAVAR, M.D.,
M.B. TABATABAIE, M.D., AND THE BALLON MITRAL
VALVULOPLASTY GROUP*

*From the Shahid Rajai Cardiovascular Center, Iran University of Medical Sciences, Tehran, Islamic
Republic of Iran.*

ABSTRACT

Ballon mitral valvuloplasty and closed mitral valve commissurotomy were performed in 450 and 127 patients, respectively. Also, 254 patients with severe mitral stenosis were enrolled in a prospective randomized trial comparing the two procedures.

Immediately after balloon mitral valvuloplasty, mean left atrial pressure was 11.38 ± 3.54 mmHg, transmitral valve gradient was 1.8 ± 2 mmHg, and mitral valve area was 2.4 ± 0.4 cm² (all $p < 0.0001$). At one week follow up after surgical mitral commissurotomy, transmitral valve gradient was 6.4 ± 2.4 mmHg and mitral valve area was 1.85 ± 0.45 cm². Two cases of severe mitral regurgitation occurred in each group. There was one case of death due to infection in the surgical commissurotomy group. Mild to moderate mitral regurgitation occurred in 36 patients (28.3%) in the surgical commissurotomy group whereas 11 patients (8.7%) developed only mild mitral regurgitation in the balloon commissurotomy group. The success rate was 96.8% in each group. We conclude that immediate hemodynamic results of balloon mitral commissurotomy, if not superior, is as favorable as surgical commissurotomy and is the treatment of choice in selected cases.

MJIRI, Vol. 10, No. 4, 259-262, 1997.

INTRODUCTION

Treatment of rheumatic mitral stenosis by surgical closed commissurotomy was first attempted in 1923.¹ Percutaneous

Address for correspondence: M. Momtahan, M.D., Shahid Rajai Cardiovascular Center, Vali-Asr St., Park Mellat, Tehran, Iran.

*A listing of the principal investigators is presented in the appendix.

balloon mitral valvuloplasty was first described by Inoue as an alternative to the surgical approach.^{2,3} Previous studies have reported successful immediate hemodynamic and symptomatic results,^{4,7} even in the presence of calcified mitral stenosis⁸ or severe pulmonary hypertension.⁹ Although comparisons of balloon mitral valvuloplasty with surgical closed mitral commissurotomy have shown similar short-term hemodynamic results,¹⁰ this study was designed to

PTMC vs. Surgical Closed Mitral Commissurotomy

Table I: Base-line characteristics of 577 patients in whom PTMC or CMVC was attempted.*

Age (yr)	CMVC (n=127)	PTMC (n=450)
15-53		15-55
Sex: Male	29 (23%)	97 (21%)
Female	98 (77%)	353 (79%)
NYHA class		
2,3	127	383 (85%)
4	-	67 (15%)
Rhythm: Sinus	127	391 (87%)
Atrial fibrillation	-	59 (13%)
Previous CMVC	-	24 (5.3%)
Associated cardiac disease:		
Tricuspid Regurgitation	22 (17%)	76 (16.8%)
Aortic Regurgitation	16 (12.5%)	57 (12.7%)
Tricuspid Stenosis	-	4 (0.9%)
M.V. Morphologic Score <8	-	395 (87.7%)
Score >8	-	55 (12.3%)
Mitral valve calcification	-	15 (3.3%)

* PTMC = Percutaneous transvenous mitral commissurotomy.
CMVC= Closed mitral valve commissurotomy.

compare balloon commissurotomy with surgical closed commissurotomy in a larger group of patients.

PATIENTS AND METHODS

Between February 1992 and September 1994, 577 patients with severe rheumatic mitral stenosis were randomized for balloon valvuloplasty (450 patients) and surgical closed mitral commissurotomy (127 patients). There were 126 males and 451 females. The mean age was 32 years (range 15-55). We enrolled 254 patients with severe mitral stenosis in a prospective randomized trial comparing the two procedures. The baseline clinical and echocardiographic characteristics of both groups are summarized in Table I.

15 percent of the patients who underwent balloon valvuloplasty were in New York Heart Association (NYHA) class IV and the remaining were in classes II and III.

Patients with more than mild mitral regurgitation or left atrial thrombus were not considered to be candidates for balloon valvuloplasty or closed mitral commissurotomy.

Echocardiographic Evaluation

Two dimensional and Doppler echocardiography was performed before and 24 hours after the balloon valvuloplasty and one week after surgical commissurotomy in all 254 patients. The presence of left atrial thrombus, the degree of mitral regurgitation and the morphologic features of the mitral valve were assessed in each patient. A semiquantitative echocardiographic score as described by Wilkins was obtained in each patient by assigning scores for valvular thickening, mobility, calcification and subvalvular disease.

The four scores for each patient (ranging from 0 to 4) were added to obtain the overall mitral valve echocardiographic score (range 0 to 16).

Commissurotomy

Balloon commissurotomy was performed by the transeptal approach with a single balloon (Inoue balloon catheter) in all patients. The balloon diameters were between 24 and 30 mm. Left atrial and left ventricular pressures were recorded immediately after each dilatation. Surgical closed commissurotomy was performed with the standard left lateral thoracotomy approach with a Tubbs dilator inserted via a left ventriculotomy.

RESULTS

Immediate results

Balloon mitral valvuloplasty was performed successfully in 123 of the 127 patients (96.8%) and resulted in a decrease in left atrial mean pressure from 27 ± 7 mmHg to 11 ± 3 mmHg ($p < 0.0001$) and a decrease in transmitral valve

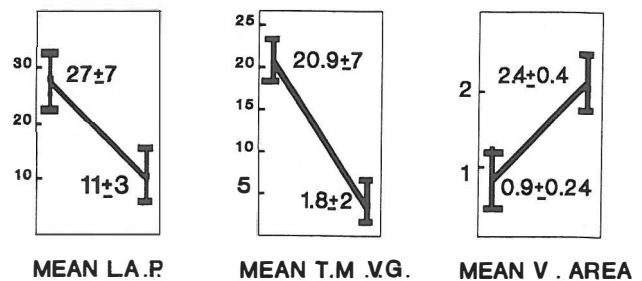


Fig.1. Hemodynamic results of balloon mitral valvuloplasty.

Table II: Clinical and hemodynamic results of balloon valvuloplasty.

Total Patients	Failure	Clinical Success	Pressure gradient	M.V. Area (Cm ²)	Mitral Regurgitation
127	4	96.85%	Before 21±7 After 1.8±2	Before 0.9±0.2 After 2.4±0.4	13 (10%)

Table III. Comparison of complications for balloon commissurotomy and surgical closed commissurotomy.

Complications	CMVC	PTMC
Mitral regurgitation (1+ to 2+)	36 (28%)	11 (8.7%)
Severe mitral regurgitation	2 (1.5%)	2 (1.5%)
Atrial septal defect	0	4 (3%)
Mitral valve replacement	2 (1.5%)	2 (1.5%)
Open mitral valve commissurotomy	1 (0.8%)	2 (1.5%)
Thromboembolism	-	-
Failure: Pericardial entrance	-	1 (0.8%)
Failure of septostomy	-	1 (0.8%)
Failure of L.V. Entrance	-	1 (0.8%)
Death	1 (0.8%)	0 (0.8%)

Table IV: Relation between echocardiographic score and clinical results.

Results	Echocardiographic Score <8 (n = 111)		Echocardiographic Score >8 (n = 16)		Total
Failure	1	0.9%	3	18.7%	4
Success Rate	110	99%	13	81%	96.8%
MR (1+ to 2+)	8	7%	3	18.7%	11
Severe MR	0		2	12.5%	2
Clinical Success		99%		81%	96.8%

gradient from 21±7 to 1.8±2 mmHg ($p < 0.0001$) and increase in the mitral valve area from 0.9±0.24 cm² to 2.4±0.4 cm² ($p < 0.0001$, Fig. 1 and Table II). Cine left ventriculography was done before and after valvotomy in all 127 patients to assess mitral regurgitation.

Immediately after the procedure, 11 patients developed mild new mitral regurgitation and two patients had severe regurgitation. Two-dimensional and Doppler echocardiographic study of the 127 patients after surgical commissurotomy demonstrated mild new mitral regurgitation (1+ to 2+) in 28 patients, 3+ in 8 patients and severe regurgitation in two patients.

The mean transmitral valve gradient decreased from 22.5±5 mmHg to 6.4±2.4 mmHg and the mitral valve area increased from 1±0.25 cm² to 1.95±0.45 cm². The success rate was 96.8% in this group.

Complications

Complications of surgical closed and balloon mitral commissurotomy are shown in Table III. Two patients in each group developed severe mitral regurgitation, all

underwent uncomplicated mitral valve replacement. 11 balloon commissurotomy patients and 36 closed commissurotomy patients developed new mild to moderate mitral regurgitation. There was one case of death due to infection in the surgical commissurotomy group. Oximetry showed the presence of a hemodynamically insignificant interatrial shunt in four balloon commissurotomy patients. It was not possible to perform transeptal catheterization or to dilate the valve in one patient. One patient developed cardiac tamponade treated successfully by pericardiocentesis followed by emergency open mitral valve commissurotomy. No deaths or thromboembolic events occurred during hospitalization in the balloon commissurotomy group.

DISCUSSION

In our study, balloon mitral commissurotomy was done successfully in 96.8% of patients in whom it was attempted, and resulted in immediate symptomatic improvement in all patients. Patients with echocardiographic score less than 8

PTMC vs. Surgical Closed Mitral Commissurotomy

had a success rate of about 99% (Table IV). Previous reports have given similar results.^{6,11,12} The success rate in the surgical commissurotomy group was 96.8%. These observations agree with surgical data that indicate that patients with pliable valves and absence of calcification have better initial results and long term prognosis after closed commissurotomy.¹⁴⁻¹⁶

The transmitral valve gradient immediately after balloon valvotomy was 1.8 ± 2 mmHg versus 6.4 ± 2.4 mmHg one week after closed commissurotomy ($p < 0.005$), and mitral valve area was 2.4 ± 0.4 cm² versus 1.85 ± 0.4 cm² respectively ($p < 0.005$). These data suggest the superiority of hemodynamic results of balloon mitral commissurotomy compared with closed mitral commissurotomy. Although the occurrence of severe mitral regurgitation was nearly equal in both groups, the incidence of new mild to moderate regurgitation was significantly higher in the surgical group (28.3% versus 8.7%). There were no deaths in the balloon valvuloplasty group versus one death in the surgical group. Our findings suggest that the immediate results of balloon mitral valvuloplasty are at least as favorable as surgical closed mitral valve commissurotomy, if not superior to it, with significantly less discomfort and shorter hospitalization. A prospective study will be needed to compare open mitral commissurotomy and balloon valvuloplasty in patients with similar anatomy.

APPENDIX

Balloon mitral valvuloplasty group:

M. MOMTAHEN, M.D.
M. KIAVAR, M.D.
H.A. BASIRI, M.D.
A. MOHEBBI, M.D.
F. NOOHI, M.D.
H. AZARNIK, M.D.
M.J. HASHEMI, M.D.
M. PAYGHAMBARI, M.D.
A.A. USEFI, M.D.
M.A. SADR-AMELI, M.D.
E. FIROZI, M.D.
M. MALEKI, M.D.

REFERENCES

1. Cutler EC, Levine SA, Becj CS: Surgical treatment of mitral stenosis: experimental and clinical studies. *Arch Surg* 9: 689-821, 1924.
2. Inoue K, Owaki T, Nakamura T, Kitanmura F, Miyamoto N:

Clinical application of transvenous mitral commissurotomy by a new balloon catheter. *J Thorac Cardiovasc Surg* 87: 394-402, 1984.

3. Lock JE, Khalilullah M, Shrivastava S, Bahl V, Keane JF: Percutaneous catheter commissurotomy in rheumatic mitral stenosis. *N Engl J Med* 313: 151-8, 1985.
4. McKay RG, Lock JE, Safian RD, et al: Balloon dilation of mitral stenosis in adult patients: postmortem and percutaneous mitral valvuloplasty studies. *J Am Coll Cardiol* 9: 723-31, 1987.
5. Palacios I, Block PC, Brandi S, et al: Percutaneous balloon valvotomy for patients with severe mitral stenosis. *Circulation* 75: 778-84, 1987.
6. The National Heart, Lung, and Blood Institute Balloon Valvuloplasty Registry Participants: Multicenter experience with balloon mitral commissurotomy: NHLBI Balloon Valvuloplasty Registry Report on immediate and 30-day follow-up results. *Circulation* 85: 448-61, 1992.
7. McKay CR, Kawanishi DT, Kotlewski A, et al: Improvement in exercise capacity and exercise hemodynamics 3 months after double-balloon catheter balloon valvuloplasty treatment of patients with symptomatic mitral stenosis. *Circulation* 77: 1013-21, 1988.
8. McKay RG, Lock JE, Keane JF, Safian RD, Aroesty JM, Grossman W: Percutaneous mitral valvuloplasty in an adult patient with calcific rheumatic mitral stenosis. *J Am Coll Cardiol* 7: 1410-5, 1986.
9. Levine MJ, Weinstein JS, Diver DJ, et al: Progressive improvement in pulmonary vascular resistance after percutaneous mitral valvuloplasty. *Circulation* 79: 1061-7, 1989.
10. Turi ZG, Reyes VP, Raju BS, et al: Percutaneous balloon versus surgical closed commissurotomy for mitral stenosis. A prospective, randomized trial. *Circulation* 83 (4): 1179-85, 1991.
11. Abascal VM, Wilkins GT, O'Shea JP, et al: Prediction of successful outcome in 130 patients undergoing percutaneous balloon mitral valvotomy. *Circulation* 82: 448-56, 1990.
12. Reid CL, Chandraratna PA, Kawanishi DT, Kotlewski A, Rahimtoola SH: Influence of mitral valve morphology on double-balloon catheter balloon valvuloplasty in patients with mitral stenosis: analysis of factors predicting immediate and 3-month results. *Circulation* 80: 515-24, 1989.
13. Bashi J, et al: Closed mitral valvotomy: early result and long term followup of 3724 consecutive patients. *Circulation* 68: 891-895, 1983.
14. Grantham R, et al: Transventricular mitral valvotomy. *Circulation* 49 (II): 200-211, 1974.
15. Benson E, et al: The effect of age and other factors on early and late results following closed mitral valvuloplasty. *AHJ* 75: 743, 1968.