

## PRIMARY DIFFUSE LYMPHOMATOUS POLYPOSIS OF THE GASTROINTESTINAL TRACT

H. FOROUTAN, M.D., AND S.A. MORTAZAVI

*From the GI Endoscopic Section, Imam Khomeini Hospital, Tehran University of Medical Sciences,  
Tehran, Islamic Republic of Iran.*

### ABSTRACT

A rare case of diffuse lymphomatous polyposis of the gastrointestinal tract is reported in which the patient presented with abdominal pain, weight loss and bloody diarrhea. X-rays revealed multiple polyps involving the stomach, small intestine and colon. Biopsies confirmed the diagnosis of lymphomatous polyposis. The duration of symptoms and signs was 3 months. Diffuse lymphomatous polyposis of the gastrointestinal tract is a distinct entity, separated from diffuse gastrointestinal lymphoma or Mediterranean-type lymphoma.

*MJIRI, Vol. 10, No. 4, 309-311, 1997.*

**Keywords:** Polyposis, Gastrointestinal tract

### INTRODUCTION

In the West, primary GI lymphoma accounts for only 5 percent of all lymphomas and 1 to 4 percent of all malignancies of the alimentary tract.<sup>12</sup> Some authors have described primary GI lymphomas as those in which involvement of the alimentary tract predominates or have symptoms of GI involvement on presentation.

More stringent guidelines include 1) absence of palpable peripheral lymphadenopathy at the time of first clinical presentation, 2) no mediastinal lymphadenopathy on chest X-ray, 3) a normal peripheral blood smear, 4) at laparotomy the lesion involves only the esophagus, stomach, bowel and/or only the regional lymph nodes (excluding retroperitoneal lymphadenopathy) and 5) the liver and spleen are free of involvement except by direct spread of the disease.<sup>3,4,10</sup>

### Case Report

A 37 year old man presented with weight loss, anorexia, fatigue, melena, abdominal pain and bloody diarrhea. The duration of symptoms and signs was 3 months. Physical examination revealed pale conjunctiva and lower abdominal tenderness but showed no generalized peripheral lymphadenopathy. The hemoglobin level was 10.2 gr/dL and the platelet count 200,000/ $\mu$ l. The leukocyte count was

7,000/ $\mu$ l with normal differentiation and no abnormal cells. The serum protein level was 5.7 gr/dL with 46% albumin. Other serum values were within normal limits. The chest X-ray was normal. The skin tuberculin test was negative. Liver

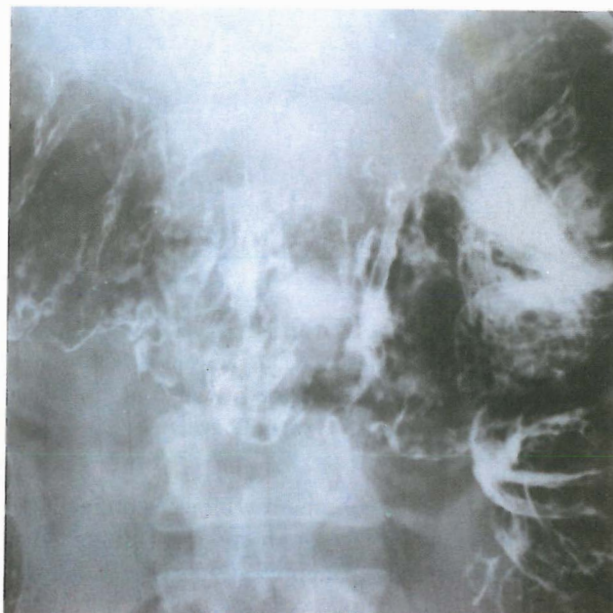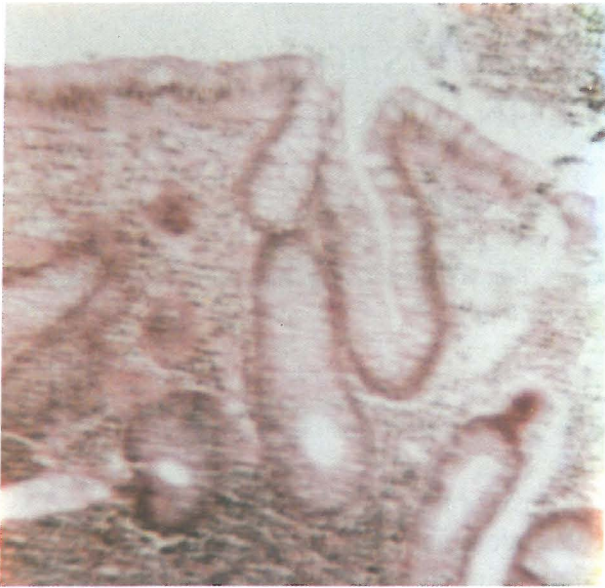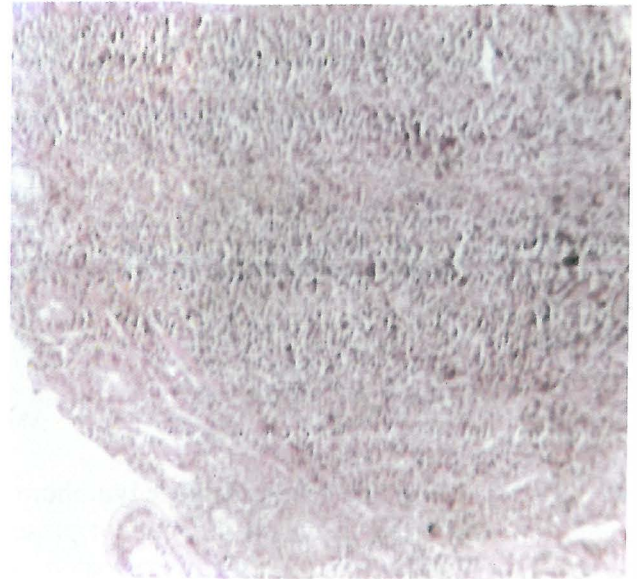


Fig. 1. Air-contrast barium enema showing a nodular pattern.

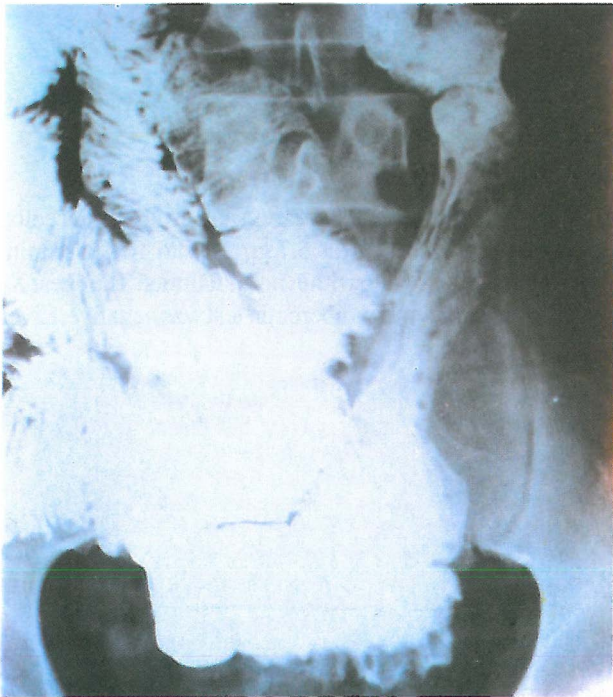## Lymphomatous Polyposis of GI Tract



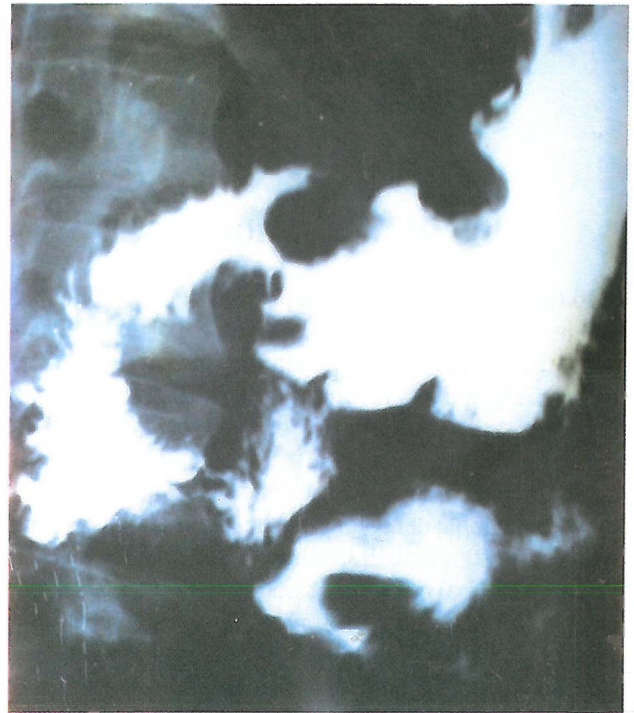**Fig 2.** Biopsy of a colonic polyp showing nodular aggregates of monomorphous, small lymphocytes, the lamina propria and adjacent submucosa.



**Fig 4.** A small intestinal biopsy showing a nodular aggregate of monomorphous, small lymphocytes in the lamina propria.



**Fig. 3.** Small bowel roentgenogram showing a fine feathery mucosal pattern extending from the duodenum to the distal ileum consistent with diffuse small bowel infiltrates.



**Fig. 5.** An upper GI series showing multiple, nodular, ulcerating mass lesions in the fundus, body and antrum, the duodenum and the jejunum.

function tests, liver and bone marrow biopsies, and abdominal CT-scan were normal. An air-contrast barium enema revealed a diffuse nodular pattern evenly distributed throughout the colon. Upon colonoscopy the polyps were fairly uniform in size, ranging from 5 to 20 mm. Some were

pedunculated and some were sessile. Polypectomy was performed. The histology of the polyps is shown in Fig. 2.

A diffuse nodular and polypoid pattern was also present with in the jejunum and ileum (Fig. 3).

## DISCUSSION

The GI tract may be involved by malignant lymphoma as a primary tumor or as part of a more widespread disease process. Generally, lymphoma is considered as "primary" in the GI tract whenever the initial symptoms of the disease are in the abdomen or present as a disturbance of GI functions. Four types of primary intestinal lymphomas have been described: a) annular or plaque-like lesions, b) bulky and protuberant growths, c) aneurysmal bowel lesions, and d) multiple lymphomatous polyps spread over long segments of the intestinal tract.<sup>4</sup> The final type— which our patient had— is the least common. Cornes et al.<sup>6</sup> have described 5 patients with this disease and reviewed a further 22 cases that have been published in the literature. Subsequently, three case reports have appeared<sup>7,8</sup> and Lewin et al.<sup>9</sup> found 4 cases of diffuse lymphomatous polyps in a review of 117 cases of primary GI tract lymphomas.

Our patient showed many features that appear to be characteristic for polyps, i.e., a patient presenting with nonspecific GI symptoms and absence of a malabsorption syndrome. Although the diagnosis may be suspected on radiologic examination, biopsies are necessary to confirm the diagnosis.

Sections of biopsy specimens from the duodenum, colon and rectum all showed similar features: these were nodular aggregates of typical lymphocytes in the lamina propria, confirming the diagnosis of malignant lymphoma (diffuse small cell type).

The patient was treated by chemotherapy (cyclophosphamide, vincristine, and prednisolone) but showed a poor response to therapy. Doxorubicin was added to the chemo-

therapeutic regimen, but with little benefit. The patient died one year after diagnosis. An autopsy was not performed.

## REFERENCES

1. Brady L: Malignant lymphoma of the gastrointestinal tract. *Radiology* 137: 291, 1980.
2. Remine S, Braasch J: Gastric and small bowel lymphoma. *Surg Clin North America* 66: 713, 1986.
3. Contreary K, Nance F, Becker W: Primary lymphoma of the gastrointestinal tract. *Ann Surg* 191: 593, 1980.
4. Dawson J, Corner J, Morson B: Primary malignant lymphoid tumor of intestinal tract: report of 37 cases with a study of the factors influencing prognosis. *Br J Surg* 49: 80-89, 1961.
5. Gray GM, Rosenberg SA, Cooper AD, Gregory PB, Stein DT, Herzenberg H: Lymphoma involving the gastrointestinal tract. *Gastroenterology* 82: 143-52, 1982.
6. Cornes JS: Multiple lymphomatous polyposis of the gastrointestinal tract. *Cancer* 14: 249-57, 1961.
7. Sheahan DG, Martin F, Baginsky S, Mallory JK, Zamchek N: Multiple lymphomatous polyposis of gastrointestinal tract. *Cancer* 28: 408-25, 1971.
8. Ruppert GB, Smith VM: Multiple lymphomatous polyposis of the gastrointestinal tract. *Gastrointest Endosc* 25: 67-9, 1979.
9. Lewin KJ, Ranchord M, Dorfman RF: Lymphomas of the gastrointestinal tract. A study of 117 cases presenting with gastrointestinal disease. *Cancer* 42: 693-707, 1978.
10. Dennie Jones Jr: Primary gastrointestinal lymphoma. In: Dennie Jones Jr, Bernard LX and Salem P, (eds.), *Textbook of Gastrointestinal disease*. W.B. Saunders, Philadelphia, pp. 1379, 1993.

